DEPARTMENT OF THE ARMY TECHNICAL MANUAL
DEPARTMENT OF THE NAVY PUBLICATION
DEPARTMENT OF THE AIR FORCE MANUAL

TM 8-300
NAVMED P-5065
AFM 160-19

TECHNICAL MANUAL

AUTOPSY MANUAL

This copy is a reprint which includes current pages from Change 1.

DEPARTMENTS OF THE ARMY, THE NAVY, AND THE AIR FORCE

APRIL 1981

CHANGE
No. 1

HEADQUARTERS
DEPARTMENT OF THE ARMY
WASHINGTON DC, *15 November 1981*

AUTOPSY MANUAL

This change is made to correct the chemical formulas for fixation of museum specimens shown on page 76. TM 8-300/NAVMED P-5065/AFM 160-19, 1 April 1981, is changed as follows:

1. New or changed material is indicated by a star.
2. Remove old pages and insert new pages as indicated below.

Remove pages	*Insert pages*
75 and 76	75 through 76.1

3. File this change sheet in the front of the publication for reference purposes.

This publication may be released to foreign governments (sec 1719, Title 44, US Code).

The proponent agency for this regulation is the Office of the Surgeon General. Users are invited to send comments and suggested improvements on DA Form 2028 (Recommended Changes to Publications and Blank Forms) direct to HQDA (DASG-PSC-L) WASH DC 20310.

By Order of the Secretaries of the Army, the Navy, and the Air Force:

E. C. MEYER
General, United States Army
Chief of Staff

Official:

ROBERT M. JOYCE
Brigadier General, United States Army
The Adjutant General

H. A. SPARKS
Rear Admiral, MC, USN
Acting Chief, Bureau of Medicine & Surgery

LEW ALLEN, JR., *General USAF*
Chief of Staff

Official:

JAMES L. WYATT, JR., *Colonel, USAF*
Director of Administration

DISTRIBUTION:
To be distributed in accordance with DA Form 12-34B requirements for Autopsy.

FOREWORD

This Autopsy Manual has been prepared at the Armed Forces Institute of Pathology.

This revised Autopsy Manual provides the prosector with ready and concise criteria on postmortem procedures and examinations. Its publication is presented as a guiding directive toward uniformity in the selected techniqes and objectives of an autopsy. It contains new information concerning cytogenic analysis, electron microscopy, examination of the oral cavity and postmortem chemistries. Many of the sections have been extensively revised to update and clarify the material.

Though this manual is issued primarily to meet the requirements of the Armed Forces and other Federal agencies, its value could well extend into civilian laboratories and civilian medicine.

ACKNOWLEDGEMENTS

Acknowledgement is gratefully made to the authors and publishers listed below for their permission to use in this manual the copyrighted material indicated:

a. Table 1 is reprinted form *Legal Medicine Annual 1976* by permission of Richard T. Goldhahn, Jr., the author, and Appleton-Century-Crofts, New York, the publishers.

b. Table 2 is reprinted from *Normal Values In Clinical Medicine*, 1948 Edition, by permission of F. William Sunderman and Frederick Barner, the authors, and W. B. Saunders Company, Philadelphia and London, the publishers.

c. Table3 is reprinted from *American Journal of Pathology 9:59, 1933*, by permission of the publisher.

d. Table 4 is reprinted from Potter, E. L. and Craig, J. M.: *Pathology of the Fetus and Infant*, third edition. Copyright 1975 by Year Book Medical Publishers, Inc., Chicago. Used by permission.

This manual contains copyright material

*TM 8-300
*NAVMED P-5065
*AFM 160-19

TECHNICAL MANUAL
No. 8-300
NAVMED P-5065
AIR FORCE MANUAL
No. 160-19

DEPARTMENTS OF THE ARMY,
THE NAVY AND THE AIR FORCE

WASHINGTON, DC, *1 April 1981*

AUTOPSY MANUAL

			Paragraph	Page
CHAPTER	1.	INTRODUCTION		
SECTION	I.	General	1-5	1
	II.	Authority	6-7	1-2
CHAPTER	2.	TECHNIQUE OF THE AUTOPSY		
SECTION	I.	External examination and body cavities	8-18	5-6
	II.	General principles in dissection and examination of the viscera	19-20	7
	III.	Organ by organ removal	21-65	9-35
	IV.	Removal of the viscera en masse (Rokitansky Method)	66-79	35-37
CHAPTER	3.	PEDIATRIC AUTOPSIES WITH SPECIAL REFERENCE TO INFANTS AND FETUSES		
SECTION	I.	Preliminary considerations	80-83	38
	II.	Technique	84-86	38-39
CHAPTER	4.	AIRCRAFT ACCIDENT AUTOPSIES		
SECTION	I.	General	87-89	40
	II.	Recording of Data	90-91	40
CHAPTER	5.	SPECIAL PROCEDURES		
SECTION	I.	Descriptive Protocol	92-95	49-51
	II.	Examination for microorganisms	96-103	51-53
	III.	Special studies of viral diseases	104-108	53-54
	IV.	Immunological examination	109-110	55
	V.	Radioactive cadavers and specimens	111-112	55-56
	VI.	Collection and shipment of specimens for toxicological examination	113-114	57
	VII.	Cytogenetic analysis	115-116	60
	VIII.	Fixation of tissue for electron microscopy	117-119	60-61
	IX.	Postmortem chemistry	120-122	61-62
	X.	Photography	123	63
CHAPTER	6.	OBJECTIVES OF THE MEDICOLEGAL AUTOPSY		
SECTION	I.	Preliminary considerations	124-126	64
	II.	Autopsy procedures	127-143	64-74
CHAPTER	7.	SELECTION AND PRESERVATION OF TISSUE FOR FURTHER STUDY AND MUSEUM PURPOSES		
SECTION	I.	Fixation of blocks for microscopic study	144-146	75
	II.	Preservation by deep freezing for bacteriological, serological, and hormone study	147-148	76
	III.	Preservation of tissues for museum purposes	149-150	76
	IV.	Fixation of museum specimens	151-153	76-78
APPENDIX	A.	REFERENCES		A-1
	B.	EQUIPMENT AND SUPPLIES		B-1
	C.	TABLES OF AVERAGE WEIGHTS AND MEASUREMENTS		C-1
INDEX				I-1-I-4

*This manual supersedes TM 8-300/NAVMED P-5065/AFM 160-19, 1 July 1960.

CHAPTER 1
INTRODUCTION

Section I. GENERAL

1. Purpose and Scope

This manual is intended to provide medical officers of the Armed Forces with ready and concise criteria on postmortem procedures and examinations and to insure uniformity in the selected techniques and objectives of an autopsy. The material presented herein is applicable without modification to both nuclear and nonnuclear warfare. The manual should not be used as a step-by-step guide before gaining an understanding of more general concepts and principles by reading the entire manual or at least the sections dealing with the type of autopsy to be performed.

2. Definitions

a. Autopsy. An autopsy is a scientific postmortem examination of a dead body, performed to reveal the presence of pathologic processes, their relation to clinical phenomena and history, and to determine the cause or causes of the changes encountered.

b. Medicolegal Autopsy (chap. 6). A specialized type of autopsy authorized or ordered by proper legal authorities in cases of accidental, suicidal, homicidal, unattended, or unexpected deaths for the purpose of determining the cause and manner of death in order to protect society and insure the administration of justice.

3. Extent of Autopsy

Whatever type of autopsy is performed, the examination should not be restricted to only those areas which are the seat of obvious alteration, but should include all the organs of the body, for the normality of certain viscera is often as significant as the disease of others, and organs that appear normal macroscopically are frequently abnormal microscopically. An exception to the foregoing is where the authority to conduct the autopsy derives from the consent of the next-of-kin and such consent has limited the extent of the autopsy. In this event, the extent of the autopsy should not exceed the extent of the consent.

4. Responsibility

It is the responsibility of the pathologist to acquaint the clinician with information obtained form the autopsy. This information is used by the clinician to aid in establishing the cause or causes of death before he signs the death certificate.

5. Preparation and Shipment of Specimens for Diagnosis

a. Small *individual* specimens, or large *groups* of specimens, each individually packed, may be mailed in a single appropriately sized container. The protocol folder should be wrapped around the representative individual specimen containers and held in place with rubber bands, while group shipment containers should include protocols and contributor's list that are placed inside separate leak proof or heat sealed plastic bags. Individual specimen shipments should be externally marked "1st Class Mail, Rush, Specimen for Diagnosis," addressed, and mailed, whereas group shipment packages should be labeled "Fragile, Laboratory Specimens," addressed, and shipped.

b. All specimens should be prepared in accordance with "Methods of Preparing Pathologic Specimens for Storage and Shipment" (TM 8-340/NAVMED P-5083/AFM 160-28/VA IB 11-13).

Section II. AUTHORITY

6. Jurisdiction Over Dead Bodies for Purposes of Autopsy

a. Deceased Military Personnel. An autopsy will be performed on the remains of any person who dies in the military service while serving on active duty or active duty for training when the commanding officer of an installation or command of his own volition, or upon recommendation of the investigating officer or other fact-finding body or medical officer, deems such procedure necessary in order to determine the true cause of death, to secure information for the completion of military records or to protect the welfare of the military community. When death occurs while a service member is serving as an aircrew member in a military aircraft, an autopsy is mandatory.

b. Other Deceased Persons. When an autopsy is deemed necessary in the case of retired personnel or nonmilitary persons who die in a military medical treatment facility or on a military installation, written permission from the next-of-kin must be obtained and recorded on SF 523 (Clinical Record—Authorization for Autopsy) before the autopsy is performed, except as provided in

(1) and (2) below:

(1) If applicable State or Federal laws authorize the performance of an autopsy, the commander may order an autopsy to be performed without the consent of the next-of-kin. The commanders of Army or Air Force installations have statutory authority to appoint summary courts-martial to investigate deaths occurring on land under exclusive Federal jurisdiction. (10 USC 4711, 9711). This authority has been interpreted as including the authority to order an autopsy when necessary to complete an investigation of death. Certain State laws may also permit the medical examiner or coroner to authorize military medical personnel to perform autopsies which would otherwise be the responsibility of the medical examiner or coroner. It should be recognized, however, that a legitimate military interest must be served by such State-authorized autopsies and that no State legal authority may order an officer or employee of the military services to perform an autopsy.

(2) Outside the United States, if local laws or regulations require an autopsy and the United States has not been exempted from such laws or regulations by treaty or agreement, the commander shall order an autopsy to be performed without the consent of the next-of-kin.

c. Consent or Other Authority Not Obtained. If consent of the next-of-kin or other legal authority to conduct an autopsy cannot be obtained, and an autopsy is required to complete records of death in compliance with local, State, or Federal law, a report will be made to civil authorities for necessary action.

d. Legal Advice. An opinion should be obtained from the local judge advocate defining "next-of-kin" for the jurisdiction in which the installation is located. Advice as to local law, jurisdictional status of military installations, and procedures for appointment of summary courts-martial should be obtained form the local judge advocate prior to proceeding with an autopsy without consent of the next-of-kin in the case of deceased retired or nonmilitary personnel.

e. Performing Autopsies Promptly. Autopsies must be completed as quickly as possible to permit prompt release of the remains to mortuary officials. Under normal conditions the autopsy should be completed within 24 hours after the death. The autopsy surgeon will employ techniques which offer minimum interference with the embalming process, particularly with respect to the circulatory system, and which minimize disfigurement. All autopsies will be recorded on SF 503 (Clinical Record—Autopsy Protocol).

7. Postmortem Examinations and Other Dispositions of Remains or Tissue for Purposes Other Than Autopsy

a. No authority to conduct postmortem examinations on either military or nonmilitary personnel for purposes other than to determine the cause of death, to complete medical records or to protect the welfare of the military community exists in the absence of written consent of the next-of-kin or other legal authority as specified in paragraph 6*b*.

b. It is the policy of the military services to dispose of remains in accordance with the wishes of the person recognized as having the right to direct disposition of the remains, provided there is strict compliance with the law of the competent jurisdiction in which the case arises. Accordingly, the written consent of the person who may direct disposition of remains must be obtained prior to obraining human tissue from any deceased. Such consent must be obtained even in cases where the deceased has left written instructions, such as in a will, and even where State law provides for giving effect to instructions of deceased. Written consent will be obtained on SF 523B (Medical Record—Authorization for Tissue Donation).

c. Authority for postmortem examination is not required for autopsy on an aborted fetus; this is examined as a routine surgical specimen.

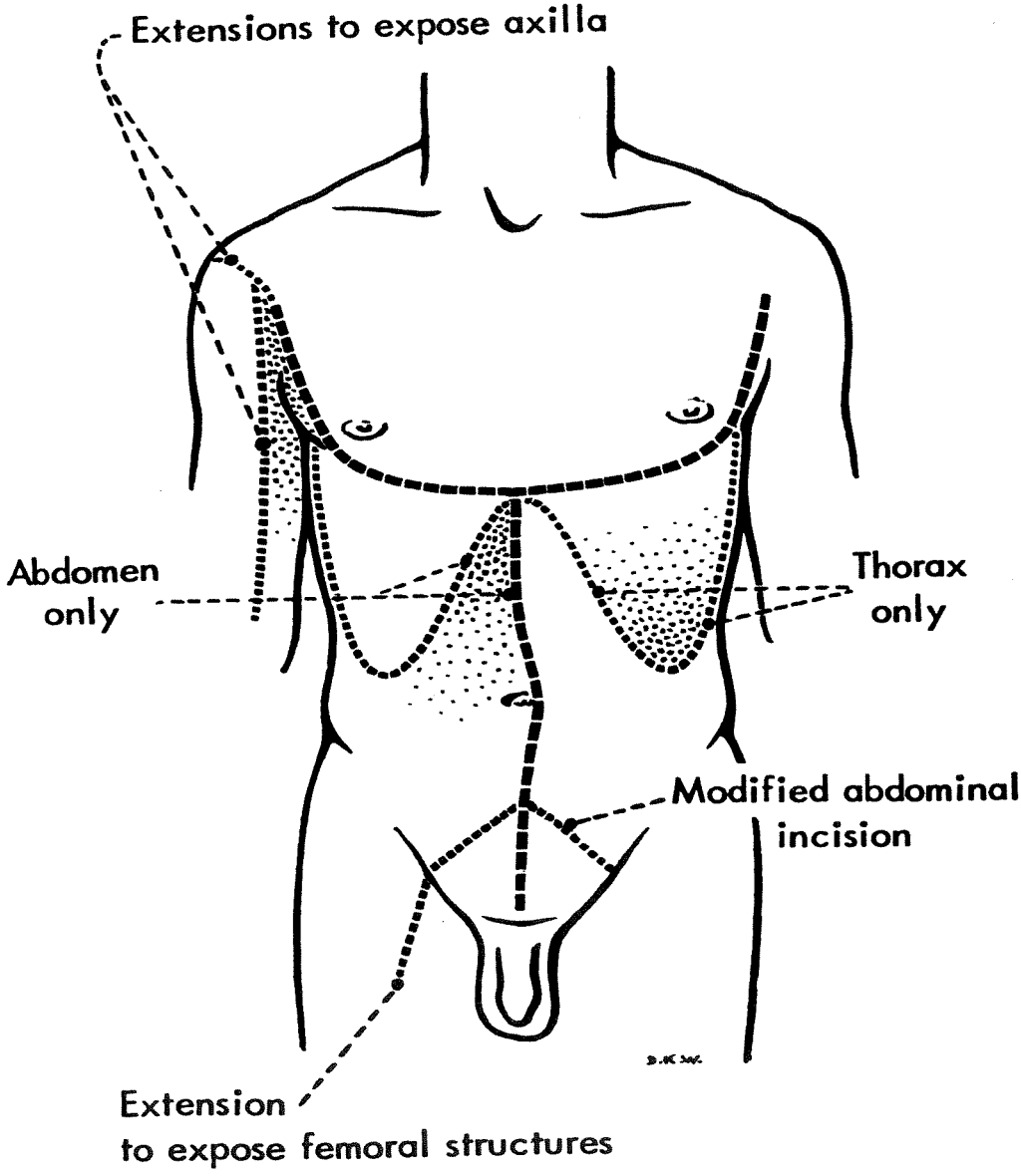
Extensions to expose axilla
Abdomen only
Thorax only
Modified abdominal incision
Extension to expose femoral structures

Figure 1.

CHAPTER 2
TECHNIQUE OF THE AUTOPSY

Section I. EXTERNAL EXAMINATION AND BODY CAVITIES

8. Preparatory Measures

a. Before he performs the autopsy, the pathologist should familiarize himself with the clinical history, clinical diagnosis and special points of interest to the clinician. Direct consultation with the responsible clinician is desirable. A complete review of the patient's hospital records will furnish valuable information and may indicate special procedures which otherwise might not be carried out.

b. The final typed autopsy protocol must include a clinical abstract for reviewing pathologists who do not have accesss to the clinical records.

c. The prosector should be familiar with chapter 6 in the case of medicolegal autopsies and Armed Forces Directives in appendix I. The body must be identified. The prosector must assure himself that the autopsy is authorized.

d. During the autopsy the prosector will ligate all major blood vessels in a manner that will permit recovery of the vessels during the embalming. It is desired that the ligatures be of sufficient length and firmly tied to facilitate recovery. The degree of consideration given by the prosector will have a strong influence on the eventual quality of preservation and appearance of the body.

9. Inspection

a. Both the anterior and posterior surfaces should be scrutinized. The more important observations include signs of violence, fractures, recent or healed wounds and lacerations, identifying marks, such as tattoos, edema of the legs, back, scrotum, or face, distention of the abdomen, jaundice, hemorrhage from the orifices of the body, hemorrhage into the subcutaneous tissues or cornea, decubital ulcers, abnormal pigmentation, tumors, anomalies, deformities, distribution of hair and subcutaneous fat, and symmetry of the trunk and extremities. The oral and nasal cavities should be examined and the state of the mucosa noted. The number, character, and state of preservation of the teeth may be indicative of certain lesions or diseases. The eyelids should be elevated and the color, size, and shape of both pupils recorded, with other pertinent observations. The external genitalia should be examined.

b. If the patient has received radioactive material, precautions are indicated in paragraphs 111 and 112.

10. Primary Incision of Thorax and Abdomen

a. The usual incision for both men and women is the Y-shaped incision indicated in figure 1. This begins at a point near the acromial extremity of the clavicle, extends in a curve below the corresponding breast to the xyphiod process of the sternum, and thence in similar manner to the opposite acromial extremity. From the xyphoid process, the incision is extended downward in the midline to the symphysis pubis, passing the to left of the umbilicus and not entering the peritoneum.

b. When the autopsy permit restricts examination to the thorax or abdomen, the skin incisions should be modified to allow individual exposure of either of these cavities without cutting into the skin of the adjacent restricted area (fig.1). Transforming the lower end of the abdominal incision into an inverted V allows easier dissection of the inguinal region and the femoral triangle (fig. 1). An extension of the primary incisions down the anteromedial aspect of the arm may be made as shown in figure 1; however, special permission is required.

c. The peritoneum is incised with scissors, or with a knife placed between two of the prosector's fingers as guides to avoid injury to the intestines or other viscera. The attachments of the abdominal wall to the costal border are severed to lay open the abdominal cavity. Transverse incisions of the rectus muscles are made when necessary to permit easier access to the peritioneal cavity. The incision over the thorax should extend through the skin, subcutaneous fat, and muscle, so that these tissues can be dissected away from the bony thoracic wall as far superiorly as 2 cm. above the sternoclavicular joints.

11. Skin

Random ellipses of skin, 2 to 3 cm. in length, may be obtained adjacent to the primary incision. Lesions noted in the external examination may be removed by excising a small ellipse which includes the subcutaneous tissue as well as the dermis. The *skin of the face, neck, arms, and hands must not be incised except when specific permission is granted.* If more than one lesion is removed, each should be placed in a separate bottle and the site of origin indicated on the label.

12. Inspection of the Peritoneal Cavity and Abdominal Organs

The amount of fluid, the character of the surfaces, and the presence of adhesions should be noted. The size,

character, and position of the omentum may yield information concerning focal lesions within the abdomen. The size and relative position of each of the viscera should be observed in relation to fixed landmarks; for example, the liver might be noted as extending so many centimeters below the right and left costal margins in the mid-clavicular lines.

13. Fluid in Peritoneal Cavity

Cultures and smears should be obtained if indicated (paras 96–103). When the amount of fluid in the cavity is increased, save at least 50 ml in a clean dry vessel. If warranted, determine the specific gravity and the character of the cells in the centrifugal sediment.

14. Exposure and Inspection of the Thoracic Viscera

a. If pneumothorax is suspected, insert a 16-gauge needle, attached to a 25 ml syringe filled with water, through an intercostal space into the pleural cavity. Bubbles will appear in the syringe if there is air under pressure. An additional confirmatory procedure is to incise the skin of the anterior thorax forming a small pocket in an intercostal space. A small volume of fluid is placed within this pocket and a small incision placed through the parietal pleura. Bubbles appearing within the fluid would indicate probable pneumothorax. A postmortem chest radiograph can also be employed.

b. Open the thorax by cutting the costal cartilages just medial to the costochondral junction. The knife should always be directed away from the subject's face to avoid possible damage. Use a heavy cartilage knife for this purpose, with the edge of the blade parallel to the surface of the body to prevent the point from entering the pleural cavity and puncturing a lung. If the cartilages are calcified, rib shears or a saw must be used. Disarticulate the sternoclavicular joints by cutting the capsular ligaments. Sever the first rib with rib shears. Dissect the diaphragm free from the lower ribs on both sides, and remove the triangular "chest plate" to expose the heart, superior mediastinum, and pleural cavities. It is advisable to place a hemostat on the internal mammary arteries and veins on each side as they turn from the sternum to enter the superior mediastinum. This will prevent the leakage of blood into the pleural cavities before they have been inspected.

c. After removal of the chest plate, the position of the mediastinum, great vessels and heart should be determined in relation to fixed anatomical landmarks. The left cardiac border can be determined in relation to the clavicles. The degree of inflation of each lung should be noted, and whether or not the lungs are voluminous and meet in the midline. The domes of the diaphragm in relation to the intercostal spaces or ribs should be indicated.

15. Pleural Cavities

a. The pleural cavities should be inspected before they are contaminated by the prosector's hands. Cultures and smears should be obtained if indicated (paras 96–103). The fluid should be cultured and examined cytologically. Save at least 50 ml for determination of specific gravity and chemical determinations as indicated. Amylase determinations of left pleural fluid can be useful in cases of pancreatitis, and lactic dehydrogenase (LDH) analysis in suspected infarcts of the lung parenchyma. The quantity of protein, the presence of cholesterol or lipid can all be determined on pleural fluid. Cytological examination of the fluid may serve as a control for premortem effusion cytology.

b. If there are slight fibrous adhesions, they may be freed by blunt dissection, but if the adhesions are dense it may be necessary to cut around the diaphragm and separate the parietal pleura from the underlying intercostal muscles and ribs in order to remove the lung. If dense adhesions are broken by force, the adjacent lung tissue is often torn.

16. Thoracic Duct

The prosector should develop the habit of displaying the thoracic duct routinely. It is difficult to demonstate and must be located before other dissections in the thorax are carried out. Lift the entire right lung from its cavity and draw it to the left side of the body, anterior to the left thoracic cage. This maneuver exposes the right side of the posterior mediastinum. The thoracic duct is located between the aorta and the azygos vein, close to the vertebrae. Opposite the fifth thoracic vertebrae the duct inclines toward the left side and enters the superior mediastinal cavity. It ends by opening into the angle of junction of the left subclavian vein with the left internal jugular vein. The thoracic duct is most easily found just above the diaphragm, to the right and behind the aorta. It can be traced inferiorly below the diaphragm where it joins the cisterna chyli located in front of the second lumbar vertebra.

17. Pericardial Cavity

The pericardial cavity is opened by a linear incision from below, cutting to the base. Note the amount of fluid, the condition of the surfaces, and the presence of adhesions. A specimen of the heart's blood may be taken for culture if indicated (paras 96–103).

18. Superior Mediastinum

Do this dissection after removal of the heart and lungs

so that the pericardial and pleural cavities will not be obscured by blood, or divide the left innominate vein between ligatures as it crosses high in the superior mediastinum, so that the three major branches of the arch of the aorta can be fully visualized. Ligate these branches as close to the parent vessel as feasible (fig. 2). The ligatures should be at least 15 inches long after they are tied. The vessels are now severed below the ligatures and the long strings left attached as an aid to the embalmer in locating the vessels. The thymus or its remnants should be dissected from the tissues of the superior mediastinum, weighted, measured, and examined. Fix all or part of the thymus for microscopic study.

Section II. GENERAL PRINCIPLES IN DISSECTION AND EXAMINATION OF THE VISCERA

19. General Considerations

a. The following general considerations should be borne in mind in the dissection of the viscera:

(1) The primary incisions in each organ should be so placed as to—

(a) Expose the largest possible surface.

(b) Open the structures that enter through the hilum.

(c) Make visible the ductal and vascular systems.

(d) Preserve the orientation and relations of the organ.

(2) All further incisions should, as far as possible, parallel the first.

b. No organ should be separated from a connecting structure until the intervening tissue has been dissected and examined; for example, the ostia of the renal arteries, the renal arteries and veins, and the ureters should be examined before the kidneys are removed from the body; the ampulla, the bile ducts, the gallbladder, the portal vein and the hepatic artery should be examined before the liver is separated from the stomach and the duodenum; and the mesentery, mesenteric arteries and veins should be explored before the intestine is separated from the mesentery.

c. All viscera except the heart should be weighed and measured before they are sectioned. Blood is lost from the cut surface and the weight may be reduced as much as 20 percent. In general the weight, the greatest length, breadth and depth should be recorded. See appendix C table 2, for normal weights and measurements.

d. The blocks to be selected for histological study are indicated under the separate organs. In all cases the prosector should use his judgment in the removal of additional blocks to illustrate specific lesions. (chap. 7).

e. All calculi should be saved in a clean dry vessel for subsequent chemical analysis, if indicated.

f. Ten percent neutral buffered formalin is the best tissue fixative for general purposes. Twenty volumes of formalin for each one volume of tissue is recommended for optimum fixation. See paragraphs 145 and 146 for other fixatives and directions for preparation of fixatives.

20. Removal of Viscera

Two general methods are available, each of which must be modified to meet special situations and the preferences of the prosector. These are; "Organ by Organ Removal" (paras 21-65) and "Removal of the Viscera En Masse" (paras 66-79). A third method, "Removal by Systems" is a compromise between the two. It is not described in this manual though it has many advantages and is used by many pathologists. There will be instances in which there should be deviations from these methods of visceral removal in order to better demonstrate certain lesions. Innovative dissections are many times very valuable in showing pathologic proceses to clinicians.

-300
MED P-5065
160-19

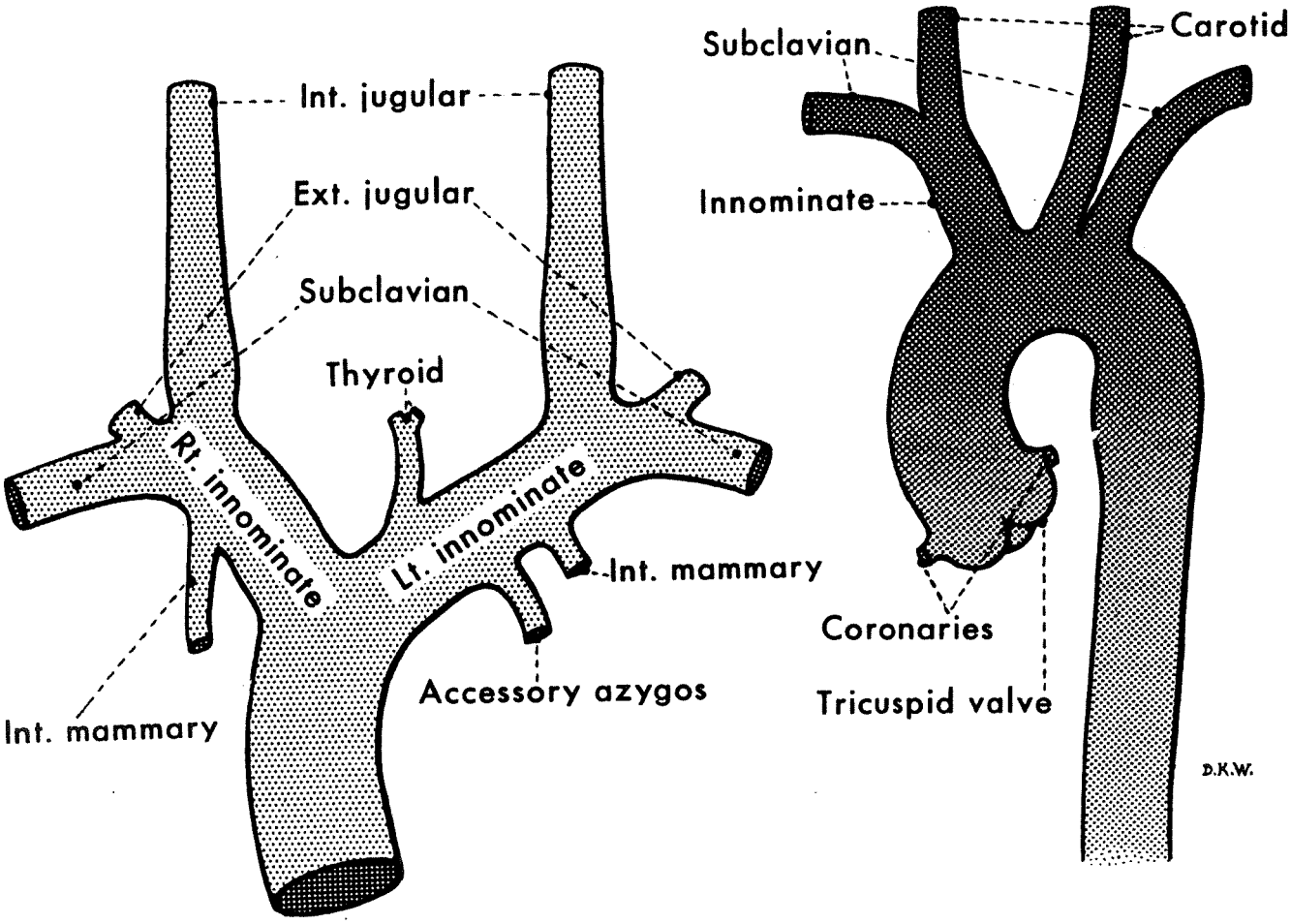

Figure 2.

Section III. ORGAN BY ORGAN REMOVAL

21. Heart

a. Inspect and palpate the heart *in situ*. Make a longitudinal incision in the pulmonary artery and examine for emboli (A-1, fig. 3). Elevate the apex of the heart and sever the inferior vena cava, and the pulmonary veins at their pericardial reflection. Place traction directed inferiorly on the heart and sever the superior vena cava, the aorta and the pulmonary artery. Remove the heart from the pericardial sac. Sever the previously opened pulmonary artery 2 cm above the pulmonary valve (A-2. fig. 3). Dissect the proximal portion of the pulmonary artery from the underlying root of the aorta (B, fig. 3); this allows the aorta to be opened later without cutting through the pulmonary artery. Open the coronary arteries by a series of transverse incisions spaced approximately 3 mm apart (fig. 4). They should not be cut, however, until the heart is fixed in formalin for at least several hours. If the clinical history indicates coronary artery disease, or if the coronary arteries feel narrowed or calcified, they are not cut until they are removed in toto from the fixed heart and decalcified. [1] Atherosclerotic coronary arteries should be cut by a gentle sawing motion with the scalpel rather than by firm pressure to prevent extrusion of pultaceous debris from complicated lesions. This method will allow the prosector to determine the type of plaque involved as well as the degree of luminal narrowing. Vital information is lost if these arteries are opened in a longitudinal fashion.

b. It is highly desirable to fix the heart in formalin at least 48 hours before dissecting it. This can be done by opening the atria and inspecting the valves. Blood clots are removed from the cardiac chambers manually. The heart is then suspended in a canister of formalin until the time of dissection. This method of formalin fixation before dissection has long been accepted as the preferred method for examining the brain. It is no less important in the proper autopsy examination of the heart, especially in maintaining three dimensional relationship for angiographic and echocardiographic correlations. An exception to the desirability of fixation prior to dissection of the heart occurs if infective endocarditis is present or suspected. In this case material for microbiologic study should be removed by sterile techniques before further dissection or fixation. [2] Other exceptions to fixation of the heart for at least 48 hours prior to dissection occur in situations where the cause of death is immediately required by legal or public health authorities, Command, or the clinical situation prior to death. Valve orifice size is determined with the valve intact; not by measurement of the circumference of the annulus. The maximal narrowing of the cardiac valves usually occurs at their apex, often located some distance from the annulus; thus, little indication of functional disturbance is obtained by measuring valve annulae (see para 23*b*). The thickness of the ventricular myocardium is usually measured 1 cm below the pulmonary or mitral valve. Care should be taken that the thickness is measured radially toward the center of the chamber and does not include epicardium, endocardium, or trabeculae carneae. These measurements are of limited value unless heart weight, heart configuration, and the capacity of the chambers are also recorded. [3] The heart cannot be accurately weighed until it is opened, cleaned of clot, and the aorta and pulmonary trunk excised 2 cm above the cephalad margin of the semilunar valve cusps. If it is important to keep the entire pulmonary trunk and ascending aorta attached to the heart (as in congenital heart disease, aortitis, dissecting aneurysm, etc.) an estimate of that weight is subtracted from the registered weight. Fixation in formalin does not alter the weight of the heart.

c. The usual method of opening the heart is to follow the blood flow. Dissect the heart as follows: Insert an amputation knife or scissors in the opening of the inferior vena cava and cut through to the opening of the superior vena cava. Use of the grooved director is helpful in making this incision (C-3, fig. 3). Open the right atrial appendage with an oblique incision beginning at the center of the previous incision (C-4, fig. 3). Cut through the right lateral border of the heart by directing the knife through the tricuspid valve (D-5, fig. 3).

d. Open the outflow tract of the right ventricle by cutting the wall of the right ventricle parallel to and about 1 cm away from the ventricular septum, passing

---

[1] Roberts, William C.: Special Report—Examining the Precordium and the Heart, *Chest* 57:(June) 567-571, 1970.

[2] McAllister, Hugh A., Jr., and Ferrans, Victor J.: The Cardiovascular System, *in* Principles and Practice of Surgical Pathology, Steven G. Silverberg, Ed., John Wiley and Sons, Inc., New York, N.Y. (in press 1981).

[3] Ludwig, J. and Titus, Jack L.: Heart and Vascular System, in Current Method of Autopsy Practice, J. Ludwig, Ed., W. B. Saunders, Philadelphia, 1972, pp 51-92.

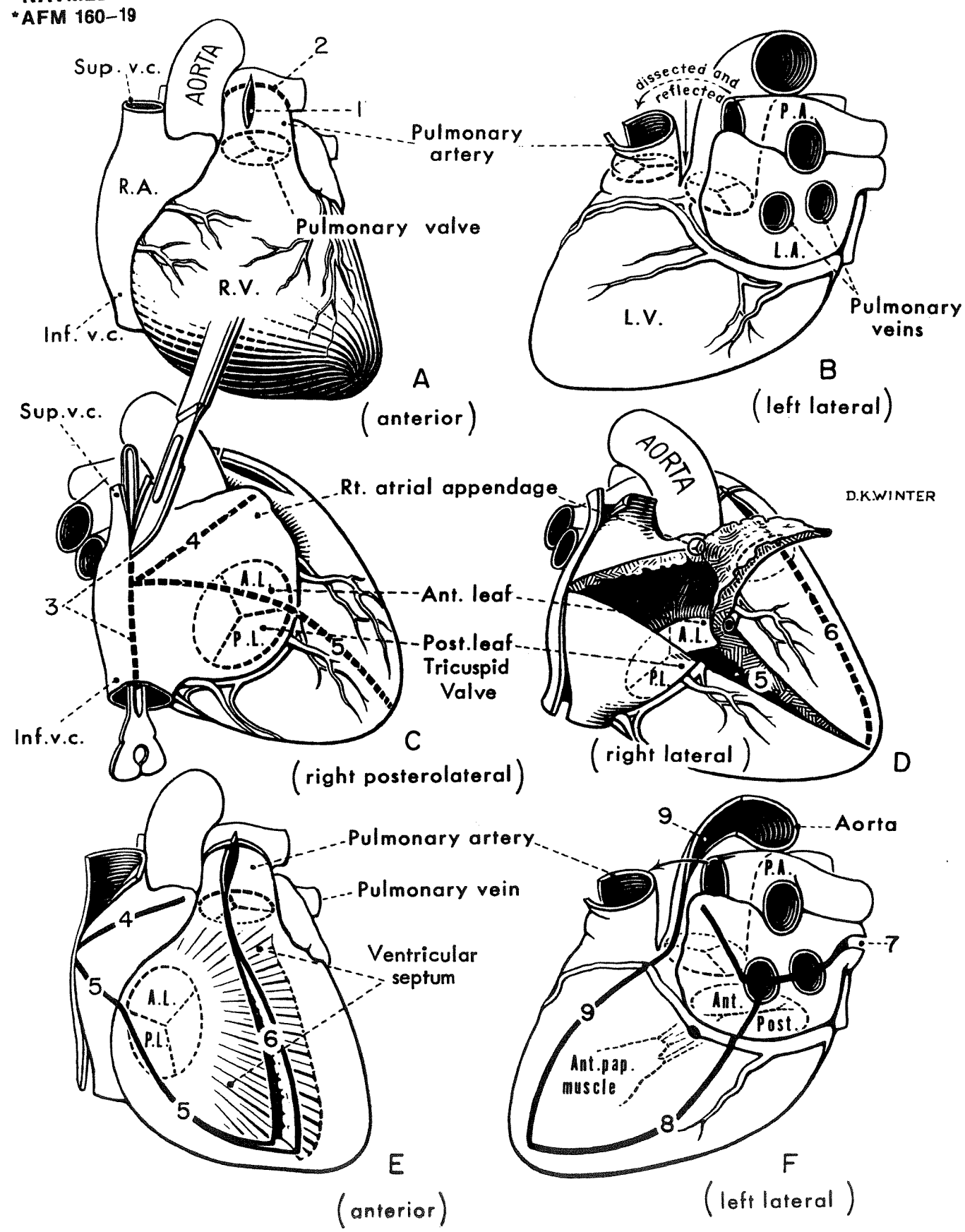
Sup. v.c.
AORTA
2
1
Pulmonary artery
R.A.
Pulmonary valve
R.V.
Inf. v.c.
A
(anterior)
dissected and reflected
P.A.
L.A.
L.V.
Pulmonary veins
B
(left lateral)
Sup.v.c.
Rt. atrial appendage
4
3
A.L.
Ant. leaf
P.L.
5
Post.leaf
Tricuspid Valve
Inf.v.c.
C
(right posterolateral)
AORTA
D.K.WINTER
A.L.
6
P.L.
5
(right lateral)
D
Pulmonary artery
Pulmonary vein
4
Ventricular septum
5
A.L.
P.L.
6
5
E
(anterior)
9
Aorta
P.A.
7
Ant.
Post.
9
Ant.pap. muscle
8
F
(left lateral)

Figure 3.

through the valve at the injunction of the anterior cusps, continuing the incision to connect with the previous incision in the pulmonary artery (D, E-6, fig. 3).

e. Open the left atrium by cutting between the openings of the pulmonary veins and making another incision from the opening of the left pulmonary vein to the tip of the left auricular appendage (F-7, fig. 3). Open the left ventricle by inserting the amputation knife through the opening of the mitral valve and stabbing it through the wall of the left ventricle in the region of the apex, and incise the ventricle along its lateral border, directing the knife through the valve near the lateral junction of the aortic leaflet and posterior leaflet of the mitral valve (F-8, fig. 3). The left ventricular cavity can now be partially opened and any blood clots removed. Extend the incision to the apex of the heart.

f. Open the left ventricular outflow tract by directing the amputation knife up through the aortic leaflet of the mitral valve. Make the incision lateral to the ventricular septum, up into the root of the aorta, reflecting the previously freed pulmonary artery away from the surface of the aorta (F-9, fig: 3). Direct the knife through the aortic valve ring in the region of the commissure between anterior and left posterior valve cusps and up into the aorta.

g. Another method of opening the heart is to make a series of horizontal cuts spaced approximately 1 cm apart, beginning at the apex of the heart, and continuing to the base of the papillary muscles (fig. 5). This method is preferred in demonstrating involvement of the ventricular wall in cardiac hypertrophy, myocardial infarction, or inflammatory lesions such as abscesses or granulomas.

h. Another method of opening the heart is to make an incomplete horizontal cut on the posterior surface of the ventricles so that the apex of the heart can be flexed permitting examination of the valves from below (fig. 6). Continue the dissection as outlined in the "blood flow" method.

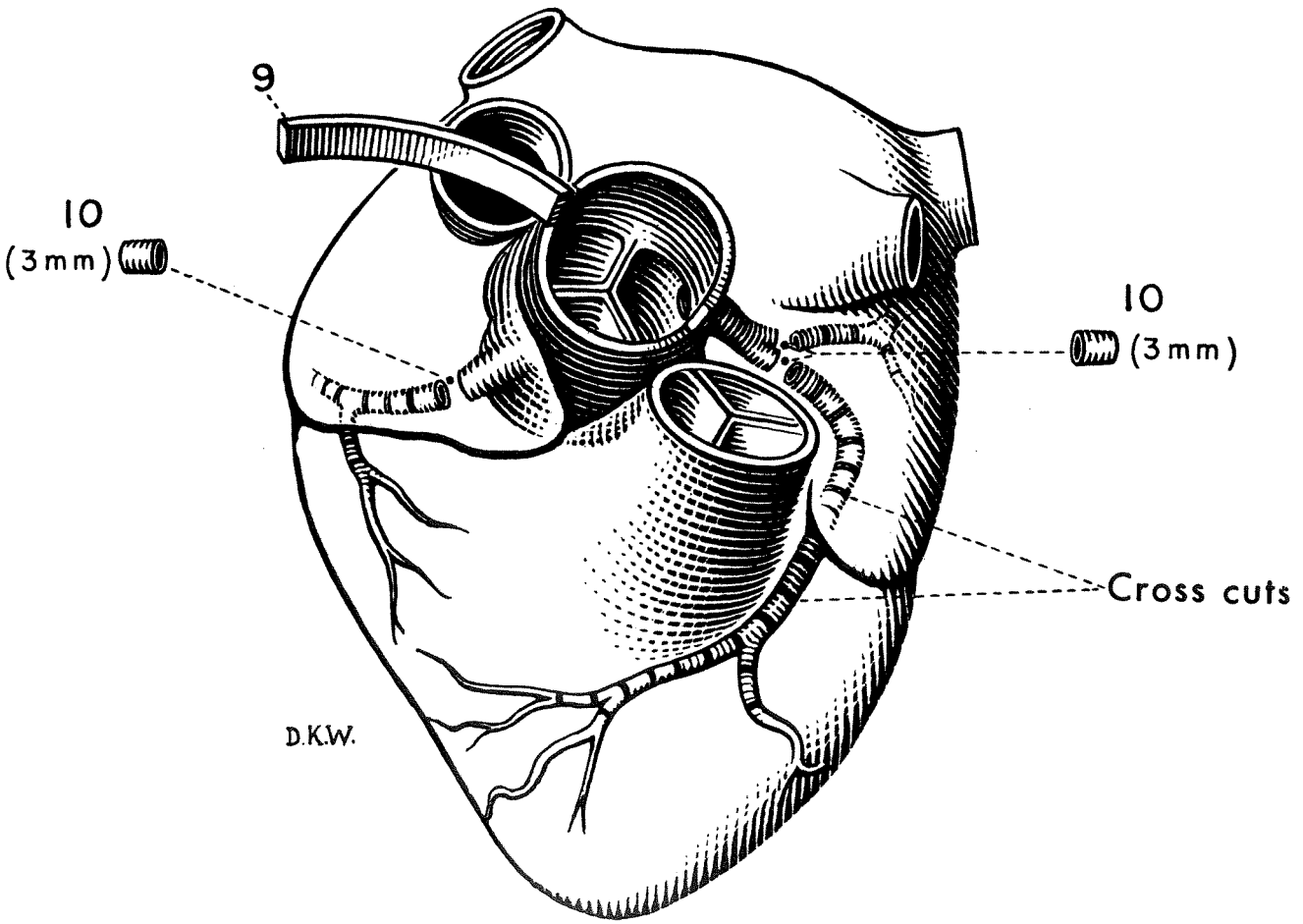

Figure 4.

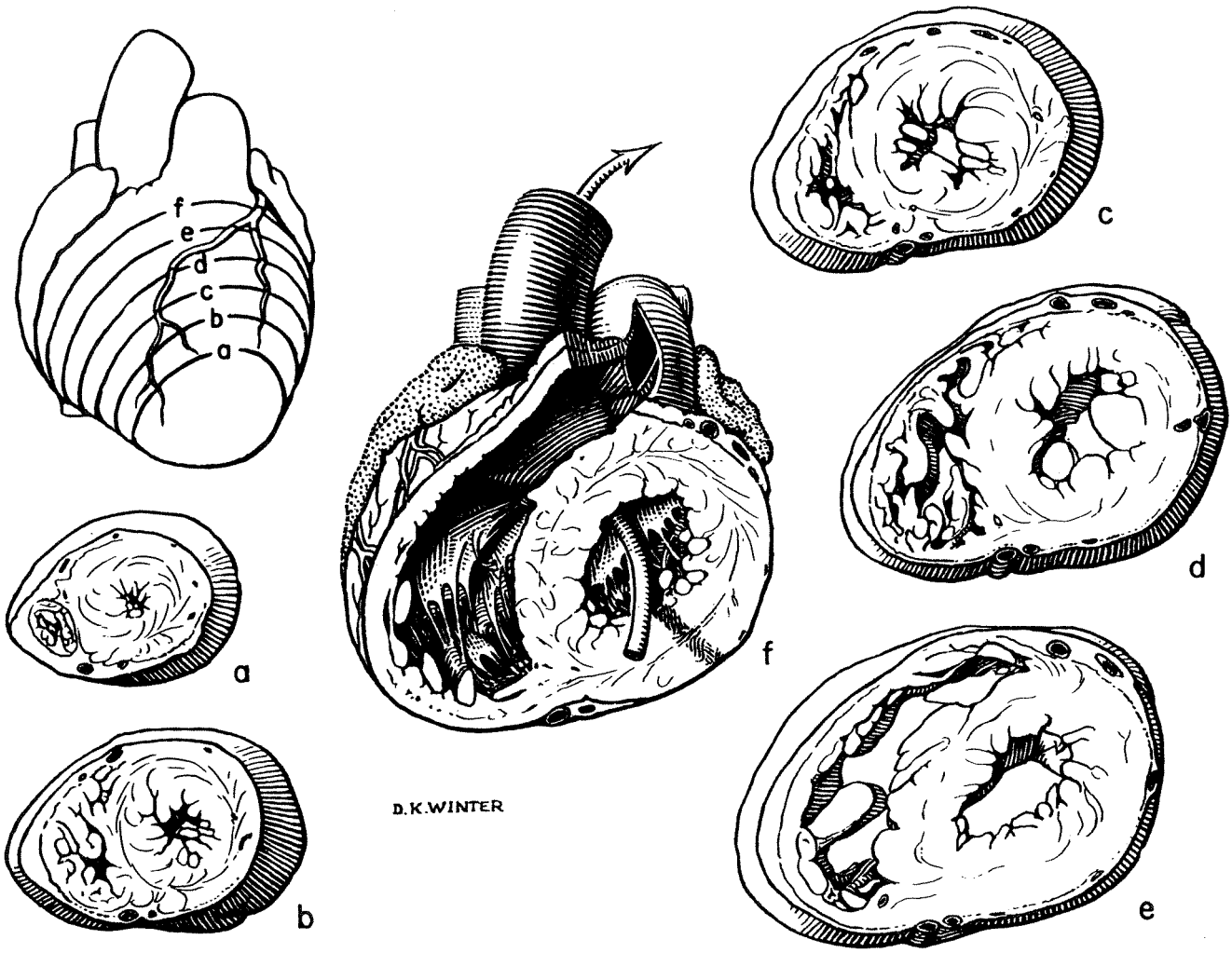

Figure 5.

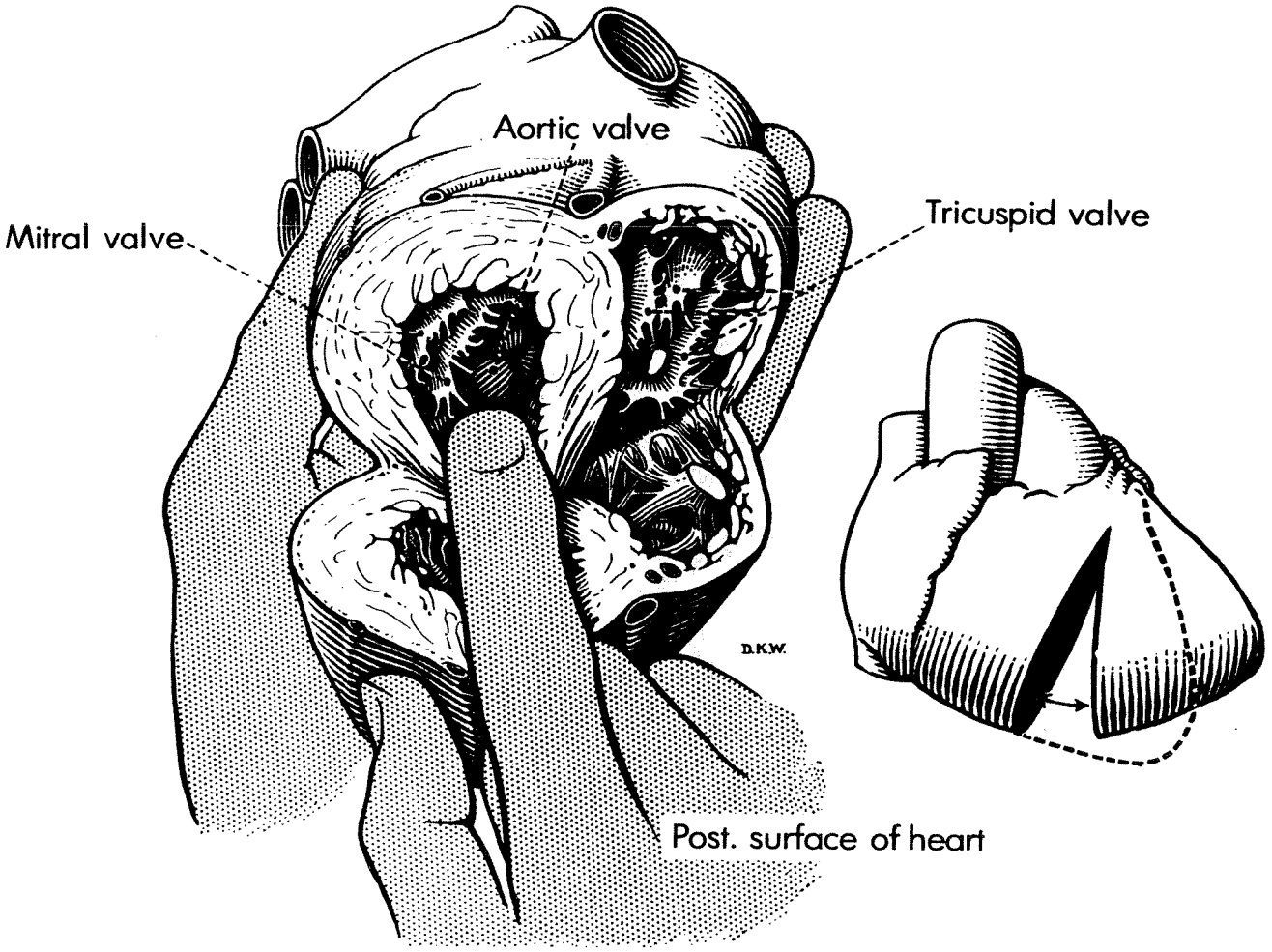
Aortic valve
Mitral valve
Tricuspid valve
D.K.W.
Post. surface of heart

Figure 6.

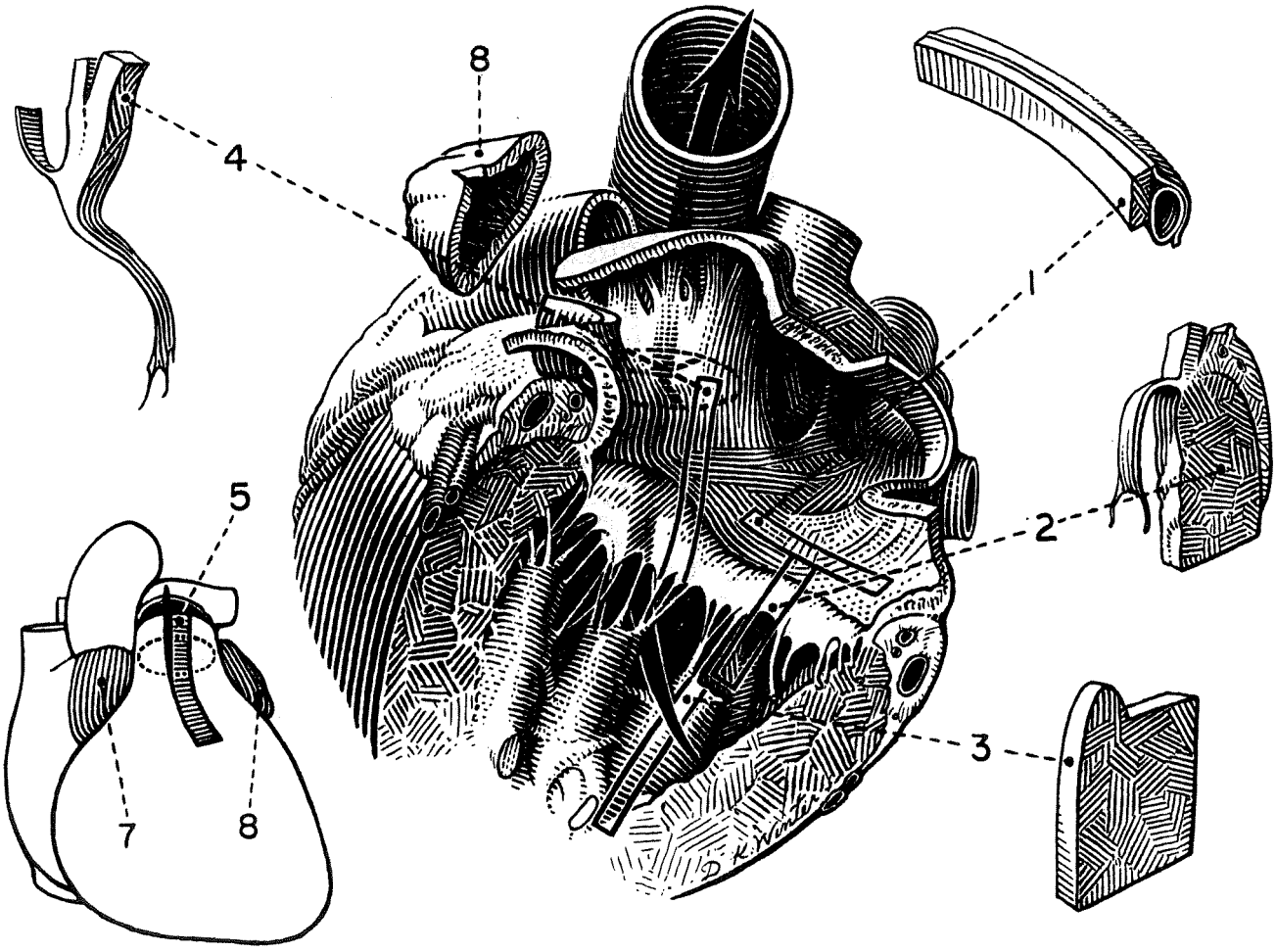

Figure 7.

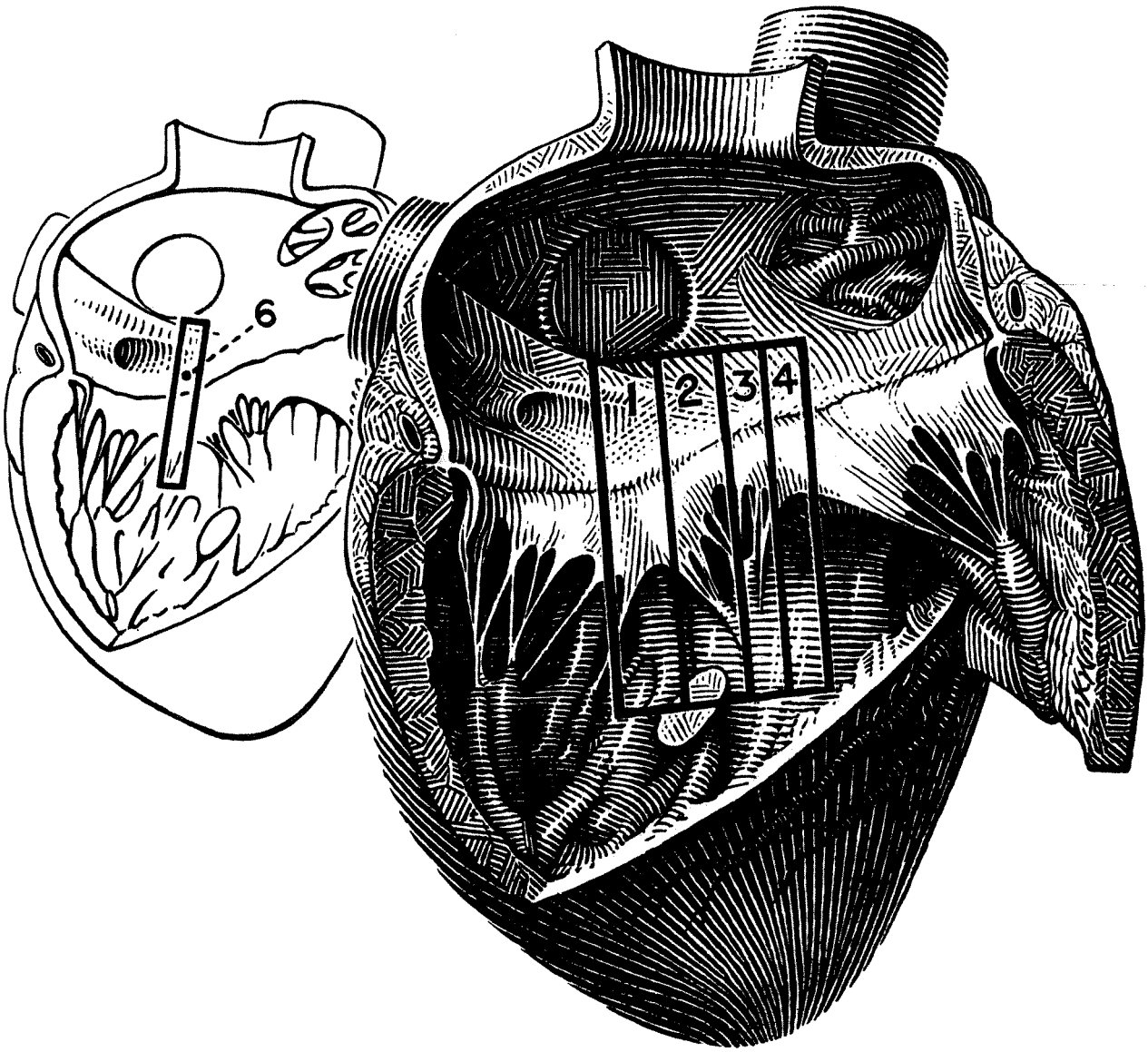

Figure 8.

22. Histologic Examination

a. In diseases associated with pancarditis such as the collagen vascular diseases, Whipple's disease, etc., it is advisable (Gross et al [4]) to take tissue for histologic examination from the following sites:

Block I: Posterior border of left atrium toward the interatrial septum, approximately 1 cm above the insertion of the posterior leaflet of the mitral valve (1, fig. 7).

Block II: Posterior leaflet of the mitral valve. From the slot made by removal of the left atrial block cut downward toward the apex so that the blade passes through the posterior leaflet of the mitral valve and the entire thickness of the adjacent myocardium. Extend the incision about 3 mm below the free edge of the valve. Make a parallel cut and remove the block (2, fig. 7).

Block III: Posterior papillary muscle of the left ventricle. Make a longitudinal incision with a scalpel, starting at the apex of the posterior papillary muscle and coming down its base. Use a parallel incision to remove the block (3, fig. 7).

Block IV: Tissue from aorta, aortic valve, and mitral valve. Insert a pair of scissors beneath the anterior leaflet of the mitral valve so that one blade lies against the atrial surface of the valve and the other against the posterior (noncoronary cusp) of the aortic valve. Carry the incision upward through the middle of the posterior cusp of the aortic valve and through the lower portion of the aorta. Make a parallel incision and remove the block (4, fig. 7).

Block V: Pulmonary artery and valve. Cut across the pulmonary artery about 2 cm above the pulmonary valve. Make a second incision through the center of the anterior cusp of the pulmonary valve in the direction of the apex of the heart, cutting through the anterior cusp, the pulmonary arterial ring and down into the wall of the right ventricle. Remove the block by means of a parallel incision (5, fig. 7).

Block VI: Right atrium and right ventricle. Cut through the wall of the right atrium and septal leaflet of the tricuspid valve about 1 cm above the septal leaflet and 5 cm lateral to the septal anterior commissure. (The blade of the knife should emerge just below the posterior cusp of the aortic valve.) Cut downward toward the apex of the heart through the wall of the right ventricle to a point 1 cm below the free edge of the valve. Make a parallel incision approximately 2 mm to the left, and remove the block (6, fig. 8).

Blocks VII and VIII: The atrial appendages. Cut through the atrial appendages about 1.5 cm from their tips. Make a parallel incision 3 mm medial to the first and remove the blocks (7 and 8, fig. 7).

Block IX: Aorta. Cut the aorta transversely 2 cm above the aortic valve for a distance of 3 cm. Make a parallel incision 3 mm above the first and remove the block (9, fig. 4).

Block X: Coronary arteries. Blocks of tissue 3 mm in thickness are cut from both coronary arteries about 1.5 cm from their origin from the aortic valve (10, fig. 4).

Obviously these sampling patterns can be modified if indicated by the gross findings. Careful dissection and inspection of the heart will often lead to a different sampling pattern not necessarily requiring eight blocks. If no heart disease was suspected clinically and no gross lesions are present, sections for histologic examination can be made adjacent and parrallel to incisions used for opening the cardiac chambers. If valves are sectioned, the valve rings and adjacent myocardium are included for orientation.

b. When a conduction defect is suspected, histopathologic study of the AV node, the bundle of His, and the bundle branches is indicated, according to Lev, Widran, and Erickson. [5] A block of tissue is taken and divided into four parts as illustrated in figure 8. See reference for details. If gross staining of the left bundle branch radiation is desired, Lugol's iodine solution may be applied onto the septal surface of the heart, rendering blue the relatively glycogen-rich conducting fibers of the left bundle branch. The main bundle and the proximal portion of the right bundle branch are not superficial enough to be demonstrated by this technique. Positive results can be expected only within 90 minutes after death.

c. If functionally significant valve lesions are present, the valves are examined and photographed intact. Measurements of the valve orifices are then obtained. The opening (effective orifice) between the free edges of the valves is measured in two dimensions and the valve is

---

[4] Gross, L., Antopol, W.; and Sacks, B.: A standardized procedure suggested for microscopic studies on the heart with observations on rheumatic hearts. *Arch. Path.* 10:840-852, 1930

[5] Lev, M.; Widran, J.; and Erickson, E. E.: A Method for the Histopathologic Study of the Atrioventricular Node, Bundle, and Branches. *Arch. Path.* 52:73-83, 1951.

left intact. When studying hearts containing prosthetic valves, the excised valve, previously sent to surgical pathology, is obtained and examined along with the heart.

23. Procedures for Certain Cardiac Conditions

a. In congenital heart disease, careful anatomic dissection is essential to identify anomalous systemic venous connections or abnormalities of the aortic arch system. These anomalous blood vessels must be identified *in situ,* preferably photographed, and tagged with an appropriate label before they are removed from the body. The heart is then removed with the lungs, as well as the uppermost portion of the liver and hepatic veins attached. It is mandatory that these hearts be fixed in formalin at least 48 hours before dissection in order to maintain spatial relationships. Modifications of the routine dissection of the heart are made whenever grafts, abnormal valves, or other lesions are to be left intact. If desired, the intact fixed heart may be forwarded to the Armed Forces Institute of Pathology.

b. When a pulmonary arterial embolus is found, its original site should be searched for in the right atrium and auricular appendage, the femoral and iliac veins, the veins of the upper and lower extremities, and the pelvic veins.

c. Air embolism in the heart can be demonstrated only at the time of autopsy, and a different method of opening the heart and great vessels is required.

(1) Venous air embolism may be associated with tubal patency test, pneumothorax, pneumoperitoneum, pneumoencephalography, intravenous infusion, childbirth, or operations on neck and thorax. A large amount of air (100 to 150 ml) is required to cause death; arterial air embolism to the left side of the heart from tears in the lungs or pulmonary veins requires less. Air trapped in the left side of the heart may be embolic to the coronary or cerebral vessels.

(2) Expose the sternum and costal cartilages by a simple midline incision from just below the sternal notch to the symphysis pubis. This incision prevents introduction of air into the heart from severed superficial neck veins. Reflect the skin and muscles. Cut the rib cartilages laterally through the level of the second rib. Do not incise the sternoclavicular joint. Sever the diaphragm from the sternum. Lift up the sternum and break it to expose the pericardium. Ligate the aorta tightly proximal to the origin of the great vessels. Lift the pericardium from the surface of the heart and incise its anterior surface for a distance of 3 cm. Elevate the edges of the incision with forceps and inspect the contents, parietal pericardium and epicardium. In cases of fatal air embolism the right side of the heart may have a balloon-like appearance. Take cultures of the fluid in the pericardial sac to rule out postmortem gaseous decomposition and clostridial or other anerobic infections which may simulate air embolism.

(3) Fill the pericardial sac with water and submerge the heart. Make a single superficial cut across the left circumflex coronary artery and the descending branch of the left coronary artery; take care not to enter the chambers of the heart. "Milk" the left coronary arteries with the finger toward the incision; this allows air bubbles, if present, to be detected in the water. Repeat the procedure with the right coronary artery. Incise under water the right atrium, right ventricle and pulmonary artery, and exert slight pressure to release trapped pockets of air. Examine the left atrium, left ventricle, the superior vena cava, the inferior vena cava, and the pelvic veins in a similar manner.

24. Trachea and Bronchi

a. Dissect remnants of the pericardial sac from the underlying structures to expose the trachea and main bronchi. Ordinarily the trachea is transected just below the larynx and is removed along with both lungs.

b. In special cases, such as death due to drowning or aspiration of foreign bodies, the tracheobronchial tree, which can be freed from the lung by bisecting the main bronchi immediately after their division at the level of the carina, should be carefully exlored. If a foreign body is suspected, radiography, with or without contrast media, can be utilized. Complete occlusion of the trachea or of one of the main stem bronchi may be present when there is obstruction to the flow of formalin introduced from either end. If there is partial occlusion, this can be determined with a probe prior to opening the tracheobronchial tree. The thickness of the bronchial walls, the structure and configuration of the cartilaginous plates, as well as the absence or fracture of any the cartilaginous plates, should be recorded. The mucosal surface should be examined for its intactness and the presence of ulceration, expecially in individuals maintained on respirators via tracheostomy tubes. Sections of ulcers, especially those penetrating to the level of the cartilaginous plates, focal mucosal thickening, leukoplakia and small zones of mucosal hemorrhage should be submitted for microsopic examination.

25. Lungs

a. Examination in situ. The gross examination of the lungs in situ should be approched systematically. Examination of pleura, number of pulmonary lobes, contour and volume of each individual lobe should be noted.

Alterations of the pleural surface such as fibrinous or fibrous adhesions, the color of the lung as viewed through the pleura, the presence or absence of pleural plaques, calcifications or nodules should be recorded. Abnormal impressions of the pleural surface, such as might be produced by the superior vena cava or alterations of the contour of the thorax, especially in cases in which there are fractures of the ribs, should be recorded.

b. Culture. Methods for obtaining lung tissue for bacteriological, fungal or viral culture include either the use of a heated metal plate touched to the pleural surface, or localized cleansing of pleural surface with acetone or alcohol, thus providing sterile access to subjacent pulmonary tissue. Slice the tissue with sterile instruments and apply the cut surface to glass slides for touch preparations. Gram, Methenamine-silver (for *Pneumocystis*), acid fast and fungus stains may be applied. Wet preparations may be prepared by scraping the cut surface. The remining tissue should be ground with an equal amount of saline for various culture methods.

(1) *Viral:* Remove approximately 1 gram of lung tissue from the suspected areas. If the material is to be delivered to the virology laboratory within 2 hours, store the tissue at 4 degrees C. If greater delay is anticipated, quick freeze the tissue and store at -70 degrees C. Note: Respiratory syncitial virus is destroyed by freezing and should be stored at a higher temperature.

(2) *Tuberculosis:* If tuberculosis is suspected, the lung should be fixed in a 1:1 mixture composed of 10 percent formalin and a 50 percent alcohol solution. If inflated with fixative, allow 48 hours for fixation or 1 week if immersed in fixative. Note: Formalin alone does not inactivate the tubercle bacillus.

c. Inflation fixation of lung. After obtaining the culture, the site of incision can be repaired so that intrabronchial instillation of fixative can be accomplished. Either one or both lungs can be inflated. The left lung is easier to inflate because of its longer main stem bronchus. Inflation can be carried out by instillation of 10 percent formalin, properly buffered, by means of hydrostatic pressure with attachments to a fixed formalin container with the fluid level of the formalin being approximately 15 centimeters above the level of the lungs. This pressure may be varied, but in most instances represents the end respiratory pressure. This technique gives excellent fixation and is the preferred method of examining lung parenchyma. If bronchi are obstructed, then perfusion of the lung with formalin can be accomplished by cannulating either the pulmonary veins or pulmonary arteries. In routine autopsies, the perfusion with formalin should continue for at least 24 and preferably 48 hours. If morphometric measurements are desired, then a week's perfusion may be necessary. After the lung is fixed, sections may be taken at 1.5 cm intervals, using the Gough-Wentworth technique. Slice the fixed lung into sagittal sections, starting posteriorly. If it is necessary to have a quantitative volume determination of either lung or individual lobes, the formalin inflated lung prior to sectioning can be placed in water and the displaced amount of water can be used to determine the volume of the lung or lobe.

d. Special Studies.

(1) *Immunology:* Tissue sections $1 \times 1 \times .5$ cm should be quick frozen for immunologic studies and stored at -70 degrees C.

(2) *Electron microscopy:* Selected areas for electron microscopic studies should be removed, cut into 1 mm^3 (cubic millimeter) sections and fixed in buffered 3 percent glutaraldehyde or other suitable fixatives. If rapid preservation of lung parenchyma for electron microscopy is necessary, then immediate fixation of a portion of lung parenchyma can be accomplished prior to opening the chest by transthoracic injection of 3 1/2 percent glutaraldehyde into lung parenchyma. The additon of methylene blue will assist in identification of the segment of lung so perfused.

(3) Special studies for vascular changes include the utilization of either latex or gelatin. Cases that deserve such special techniques should be referred to centers that have the appropriate equipment and experience in performing these rather complicated procedures.

e. Examination of lung.

(1) Prior to sagittal sectioning of the lung, the carinal, hilar, and bronchial lymph nodes should be examined individually, and alterations in color, firmness, as well as the presence or absence of metastases or granulomas, should be recorded. If distribution of metastases is important, each lymph node group should be identified separately. Although sections of main stem and segmental bronchi are not routinely submitted, they are necessary in diagnosing chronic bronchitis. Cross sections of bronchi can be obtained prior to the sagittal plane cutting. The pulmonary arteries should be examined for atherosclerosis and thromboemboli.

(2) If a primary neoplasm of the lung is suspected, wider sagittal planes or dissection of a fresh lung by cutting along the bronchial planes will help to determine the site of origin within the bronchus. Sections submitted for microscopic examination should be identified as to their exact origin; i.e., side, lobe, and bronchial segment. Tumors of lung should be described in detail as to their location, including relationship to pleura and bronchi, size, number, consistency and color.

(3) If a fresh lung is utilized, cut along the bronchial ramifications as a method of examining the lung parenchyma, then touch preparations of the lung neoplasm and surrounding parenchyma can be done and collection of intrabronchial material can also be utilized as a positive control for premortem cytology.

f. Demonstration of emphysema.

(1) After 1 inch sections of lung are cut, they may be floated in water in order to determine the degree of emphysema. By floating the inflated and fixed specimens on a liquid solution, the distal air parenchyma is expanded, and the degree of remaining pulmonary parenchyma can be estimated. The volume of individual lobes, their contour and shape can be estimated, and by palpation, zones in which there is alveolar filling can be examined. Regional aeration or consolidation can also be determined on sagittal plane sections.

(2) Utilization of barium nitrate and sodium sulfate solution. In some cases of minimal emphysema, if is necessary to accentuate the alveolar septa, and this can be accomplished by using a saturated solution of barium nitrate and a saturated solution of sodium sulfate. A sagittal section of lung parenchyma approximately 1 inch in thickness is rinsed of formalin, blotted dry, and then immersed in a pan large enough to hold the lung tissue and the barium nitrate solution. Permeation of the lung parenchyma by this solution can be assisted by focal compression and release of the lung parenchyma, comparable to squeezing a sponge. After this has been accomplished, the lung may be blotted dry and then immersed in sodium sulfate solution. The same kneading procedure of the lung parenchyma may be necessary in order to admix the solutions and have proper impregnation of the lung parenchyma by barium sulfate. This lung section may then be rinsed and examined under water with a dissecting microscope to determine the degree of emphysema. Photographic documentation can also be performed at the same time.

g. Determination of Pneumoconiosis. A weighed portion of lung parenchyma in terms of grams of dried lung can be digested by the use of Chlorox, spun down or filtered, and the particles of dust per gram of dry lung will express the concentration of dust within the lung parenchyma. Sections should be taken from the subpleural versus medial, and an upper versus lower lobe in order to provide representative counts of different portions of the lung parenchyma. Iron stains may assist in counting the number of ferruginous bodies.

h. Photographic documentation of lesions within the lung can be performed at different stages of the autopsy. Massive air trapping as can be seen with total occlusion of a sublobar bronchus, or atelectasis secondary to occlusion of a more proximal bronchus, may best be demonstrated by photography in situ. Photographs to demonstrate emphysema should be taken while the lung is suspended within an aqueous solution. Restoration of color to a formalin fixed lung section can be accomplished by the addition of 95 percent alcohol for a period of 1 to 2 hours.

26. Examination of the Larynx, Pharynx, Hypopharynx, Tongue, Thyroid, and Parathyroid

a. When there is extensive disease of these structures it is advantageous to remove all the neck organs as a unit. To accomplish this, the skin, together with the attached platysma muscle and portions of the pectoral muscles, is dissected from the underlying tissue and retracted as far superiorly as possible. The muscles of the neck will be exposed and enlarged cervical lymph nodes can be noted. Further dissection will reveal the submaxillary glands in the submaxillary triangles. The thyroid gland is brought into view by dissection and lateral retraction of the infrahyoid muscles. With blunt dissection each common carotid artery is dissected from the carotid sheath and retracted away from the larynx and trachea along its entire course in the neck. Avoid cutting the carotid arteries during this procedure because of their importance to proper embalming of the head. These vessels are ligated with long strings and then severed at their origins from the aortic arch on the left and the innominate artery on the right. The patency of the internal carotid arteries can be tested by injecting them with physiological solution of sodium chloride after the brain has been removed.

b. The extrinsic muscles of the tongue are cut through their attachment to the mandible and styloid process with the amputating knife. The stylopharyngeus muscle is severed from the styloid process at the same time. The soft palate and uvulva are cut from their attachments. The mobilized tongue is drawn inferiorly and the posterior wall of the pharynx and esophagus separated from the underlying tissues. The lower respiratory tract, including the trachea, bronchi and lungs, may be left attached to the upper air passage or the trachea, while the proximal portion of the esophagus may be transected. In this way the tongue, the pharynx, the pharyngeal muscles, the larynx, the trachea, the thyroid, the parathyroids, and the proximal portion of the esophagus are removed *en bloc*. After examination of the surface of the tongue, multiple transverse sections are made.

c. Dissection of the parathyroid glands is facilitated

by removal of the neck structures *en bloc* so that there will be landmarks. The parathyroids are sought from the posterior aspect. The prosector is more likely to find all parathyroid glands if he is seated and has a spotlight directed on the field. Some pathologists prefer to fix the specimen in formalin before attempting to locate the parathyroid glands, because they are firmer and a deeper yellowish brown than in the fresh state. The upper parathyroid glands are usually found embedded in the deep cervical fascia between the esophagus and the posterior aspect of the upper portions of the lateral lobes of the thyroid. The lower parathyroids are usually found in the deep cervical fascia along the inferolateral aspect of the lateral lobes of the thyroid. Occasionally one or more parathyroids are embedded in the thyroid gland or are located inferior to the gland in the upper anterior mediastinum. The normal parathyroid glands are yellow-brown structures that are distinct in color and consistency form the surrounding softer yellow fat and firmer gray lymph nodes. In cases in which the parathyroid glands are of unusual interest, all the tissue from this region should be saved for microscopic examination in the event that all the glands are not identified grossly. After the parathyroid glands are removed, the thyroid gland is dissected from the larynx and multiple sections are made through it.

d. The upper air passage should be examined for evidence of obstruction before it is opened. Next, the hypopharynx, including the epiglottis and the pyriform sinuses, should be examined. The upper portion of the esophagus is opened posteriorly and dissected away from the posterior wall of the larynx. The larynx is then opened longitudinally along its posterior aspect to reveal the vocal cords.

27. The Oral Cavity

a. The oral cavity is one of the most overlooked areas in postmortem examinations. Pathologic conditions related to the major disease process responsible for the patient's death or to chemotherapeutic agents used in treating his illness may be present in the oral regions. Metastatic or metabolic diseases, or debility resulting from a prolonged chronic, terminal illness, to mention just a few, may also be reflected in these tissues. Such conditions should be described and discussed in the final autopsy report. However, rigor mortis often tenders adequate examination here very difficult and therefore prosectors may be discouraged from conducting thorough oral examinations. But important conditions relating to the cause of death may be found here. On occasion, falling out of bed or seizures in terminally ill patients have resulted in the displacement or fracture of prosthetic appliances. These may block the larynx or compress the epiglottis resulting in death by asphyxiation. Without a thorough examination of the oral cavity, this could easily by overlooked. One non-mutilating method of gaining access to the oral cavity locked in rigor mortis is by the use of the Molt mouth prop which is designed to force and hold the mouth open. After the neck organs are removed (see para 26), the oral cavity posterior to the teeth can be visualized.

b. A thorough examination of the oral region should include visual and digital examinations of the labial mucosa by everting and and palpating the upper and lower lips. The buccal mucosa, buccal alveolar mucosa, lingual and palatal alveolar mucosa, hard and soft palate, the dorsum, ventral and lateral borders of the tongue and the floor of the mouth, should be examined visually and by palpation. Examination for palpable minor salivary glands and lymph node enlargments should be included. The cortical plates of both the maxilla and the mandible should be thoroughly palpated for thinned areas of erosion, crepitis, perforation, sinus tracts, etc., which may indicate the presence of central lesions of the jaws. If portable x-ray or panoramic radiograph equipment is available, a fast radiograph could be most useful in exposing such central lesions. Any tissue deviation from normal, either in the soft tissues or within the bone should be sampled for histologic examination. At times there may be a neoplastic process involving the periodontium, teeth and pulp of one or several teeth, with bone destruction and root resorption. The ideal procedure for good gross and histologic examinations of such lesions would be an *en block* resection. If the prosector is not experienced in this procedure, the hospital oral surgeon or senior residents in the oral surgery department could be invited to the morgue for consultation or to actually perform the resection. The importance of this procedure is that it retains the relationship of the intraosseous lesion to the roots of the involved dental structures and the surrounding contiguous bone.

28. Mesentery and Intestine

a. Excise the greater omentum close to its attachment to the stomach. The superior mesenteric artery and vein can be examined when the transverse colon and its mesentery are drawn superiorly. By this maneuver the root of the mesentery and its vessels will usually be exposed. In an obese subject it will be necessary to remove fat to bring the vessels to view. Open the vein and the artery. Examine the mesentery by multiple sections across the mesenteric arteries, veins, and lymph nodes. Tie the jejunum with double ligatures for a few centimeters below the ligament of Treitz. Use a sharp, long knife to separate the intestine from the mesentery as close as possible to the intestine. On reaching the ileocecal region, incise the

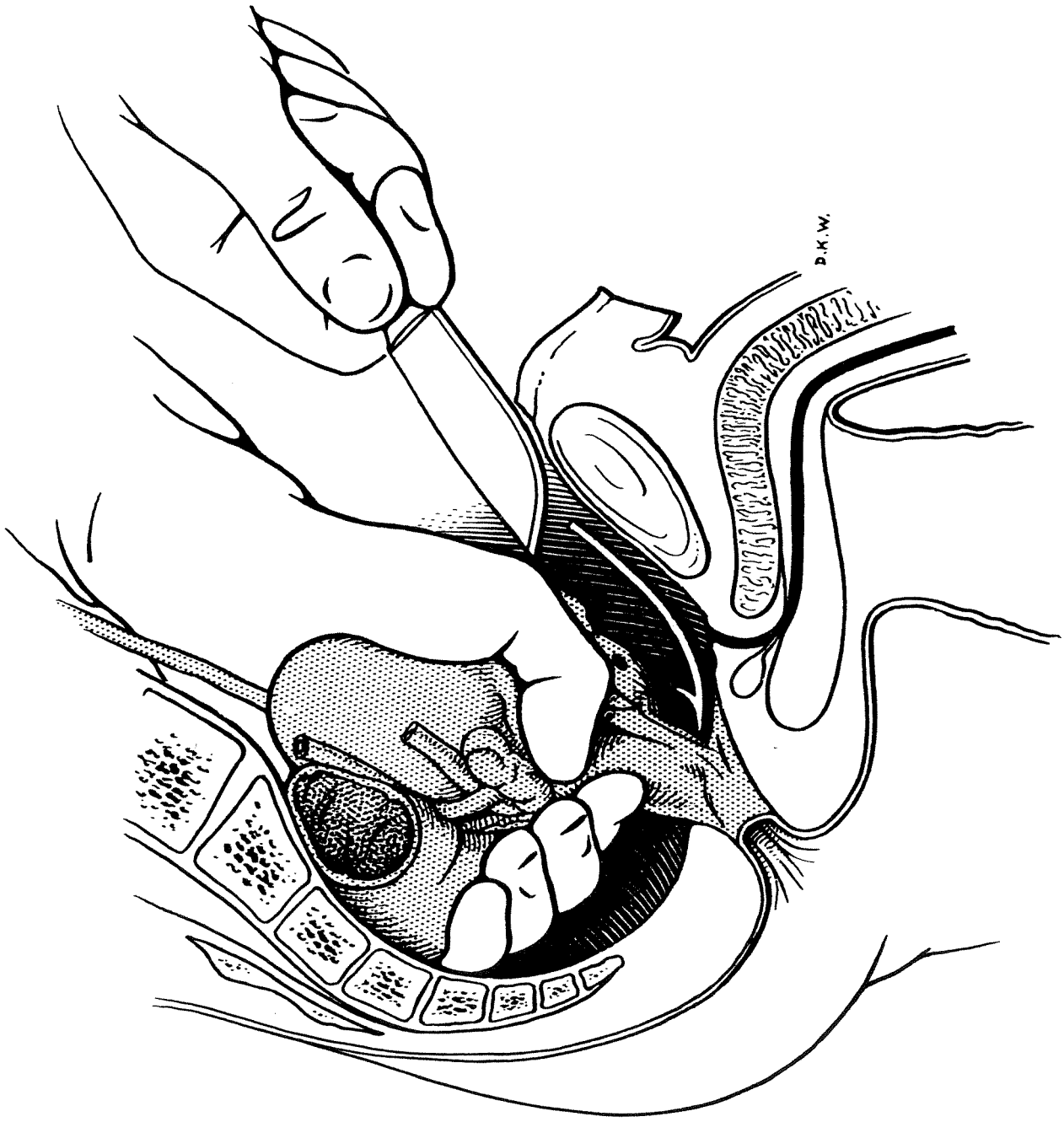

Figure 9.

peritoneum of the posterior abdominal wall and lift the cecum and ascending colon free from the surrounding tissues. Separate the transverse colon from its attachments to the stomach, and raise the descending colon away from the posterior abdominal wall. Displace feces from the sigmoid and rectum by stripping upward into the descending colon. Place double ligatures about the sigmoid colon 5 to 6 cm. above the sigmoidorectal junction. Cut between the double ligatures around the jejunum and colon and lift the entire intestine form the body.

b. The rectum is removed along with the bladder as indicated in figure 9 and described under *Urinary Tract.*

c. Remove the mesentery of the small intestine by severing its attachment to the posterior abdominal wall. Open the small intestine with blunt scissors or enterotome along the mesenteric attachment, and the large intestine along one of the taenia. The appendix may be examined by multiple cross sections or by a longitudinal incision through the lumen. As the intestine is opened, note the fluidity, color, and other characteristics of its contents. Take sections of representative regions. Do not rub the fingers over the mucosa or wash it with water before the sections are placed in fixative. Record the thickness, consistency, and color of the mucosa and of the wall as a whole.

29. Spleen

Examine the anteror surface of the pancreas, the splenic artery, the vein on the superior surface of the body and tail of the pancreas. Lift the spleen, divide the vessels at the hilum, and remove the spleen. Weigh the organ and measure its length, breadth, and thickness. Expose the parenchyma by a single incision extending from the greatest convexity toward the hilum. Further incisions parallel to the first should be made 3-5 mm apart (particularly, if the patient is suspected of having Hodgkin's disease). Touch imprints should be made if a hematologic process is present or suspected. If enzyme studies are contemplated, air dry the imprints for fixation and do not fix in methanol.

30. Lymph Nodes

Any enlarged lymph nodes should be incised and the cut surface examined. Take note of any replacement of the lymph node by tissue foreign to the node (malignancy or infectious process). Touch imprints may be made to help to elucidate the cause of any enlargement. If enzyme studies are contemplated, air dry the imprints for fixation and do not fix in methanol.

31. Gallbladder, Bile Ducts, and Nearby Vessels

The gallblader, bile ducts, and nearby vessels are usually examined *in situ:* Open the second part of the duodenum and locate the ampulla of Vater; Squeeze the gallbladder and note whether or not bile issues from it. Pull the duodenum anteriorly to expose the retroduodenal distal portion of the common bile duct. Nick the duct, and with a small scissors, open it proximally into the cystic and hepatic ducts and distally into the ampulla of Vater. Note the circumference of the common bile duct, and look for stones, tumors and strictures. Open the gallbladder, note its contents, examine the mucosa and wall, and collect the bile in a clean dry glass container, saving this for toxicologic study if needed. Within the hepatoduodenal ligament, the hepatic artery is usually to the left of the common bile duct, and the portal vein is posterior; these should be opened and explored. Nearby lymph nodes should be examined and sampled. The prosector may find it more convenient and instructive to dissect this region from the posterior aspect after removal *en masse* (see para 60-73), especially if the portal vein and its tributaries are obstructed by tumor or thrombus, or if a portacaval shunt is present.

32. Esophagus, Stomach, and Duodenum

If there is no pathologic change to indicate the desirability of keeping the liver, bile ducts, and duodenum in one piece, cut across the structures in the hepatoduodenal ligament and remove the duodenum, pancreas, stomach, and esophagus *in toto.* Extend the previous incision in the anterior surface of the first part of the duodenum along the greater curvature of the stomach and up the anterior wall of the esophagus. Note the character of the stomach contents, the thickness, rugae of the mucosa, and other features of the walls. Extend the incision in the second part of the duodenum so as to open the entire length of the third part.

33. Pancreas

Examine the pancreas by making multiple cross sections or by a single frontal section extending from the inferior border to the superior border. On the cut surface locate the pancreatic duct; note its size and content, and the character of its wall. With small sharp-pointed scissors open the pancreatic duct. Separate the pancreas from the duodenum by dissection. Weigh it and measure the long axis, the width of the head, and the average depth. Select blocks of the head, body, and tail for microscopic study. The islets are most numerous in the tail. This block should be used for routine sections, but the other blocks should be saved in case they are needed.

34. Liver

After dividing the duodeno-hepatic and gastro-hepatic

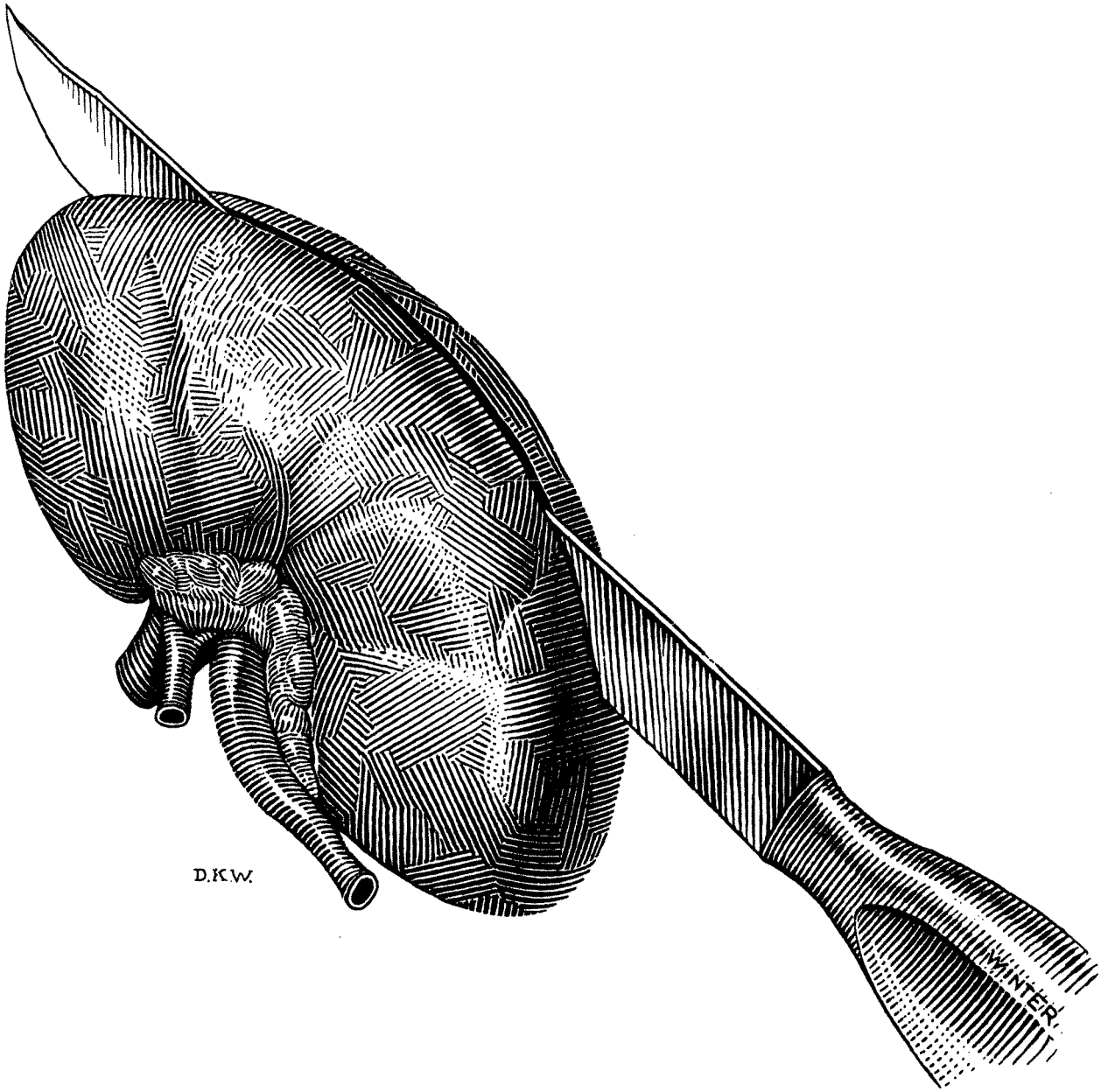

Figure 10.

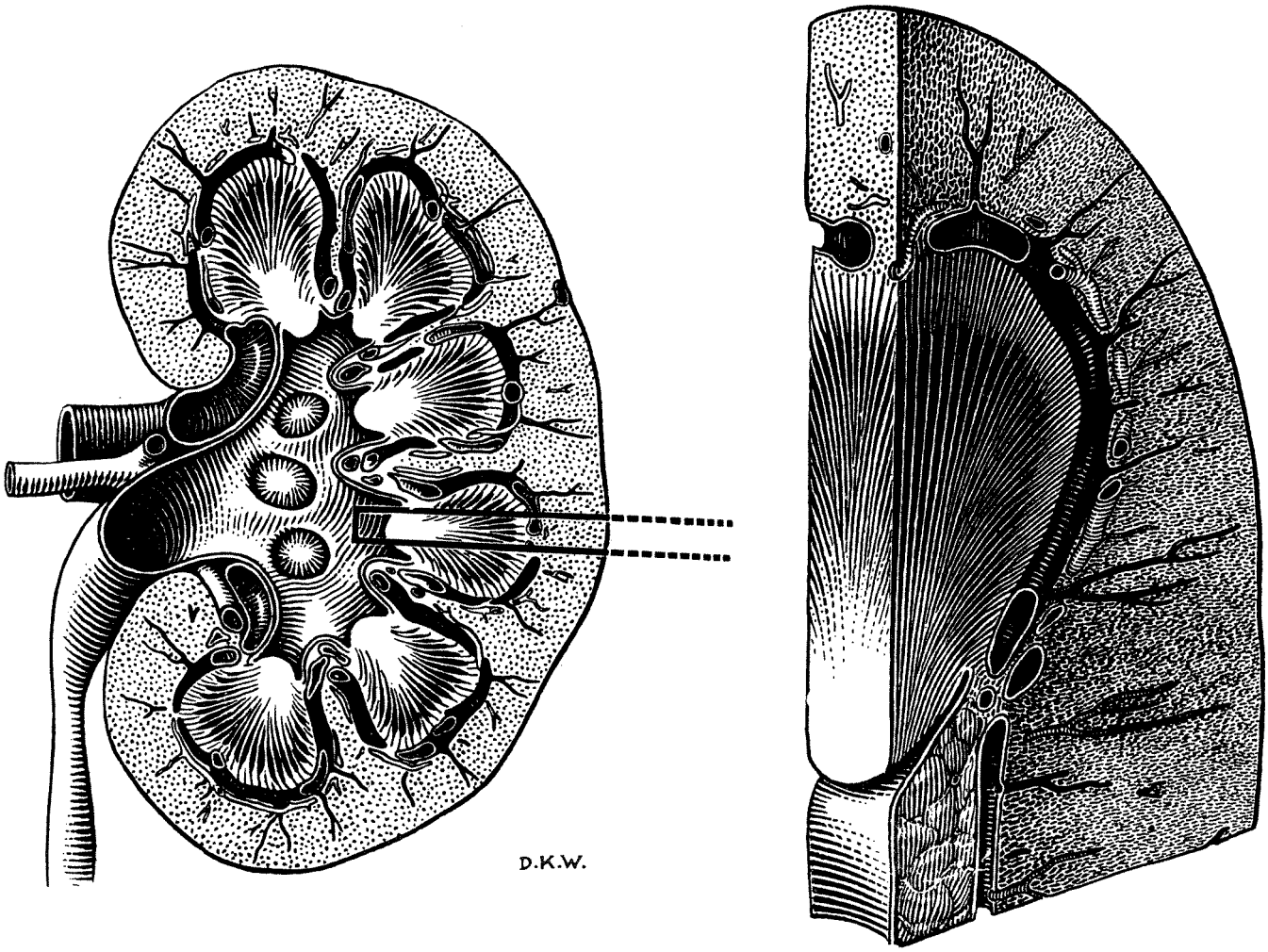

Figure 11.

ligaments, remove the liver by dividing its attachments to the diaphragm and cutting the hepatic veins (usually 3) where they join the inferior vena cava. Explore the hepatic veins for obstruction. Weigh and measure the organ and describe the exterior surface. Slice with a long knife, each parallel slice about 2 cm thick: Describe the color, consistency, and architectural pattern. Pay special attention to the hilar region. Take representative blocks. (See paras 113 and/114 for toxicologial specimens, and paras 147 and/148 for other special studies).

35. Adrenal Glands

Free the adrenal glands by dissection and remove extraneous tissue. Weigh the organs if the size is abnormal and examine the cut surface by making parallel sections. Place a part or all of each organ in 10 percent formalin.

36. Aorta and Vena Cava

a. Use an enterotome to open the aorta along the anterior surface. Inspect the intima, the wall, and the orifices of each of the principal branches. The orifices should be opened. If there is no pathologic change in the renal arteries or renal veins, they may be divided at a point 1 cm from the aortic orifice. If the arch of the aorta is to be removed, the 3 major branches (innominate, left common carotid, and left subclavian arteries) must be ligated about 2 cm. above their origins and severed below the ligatures which should be left with ends at least 5 inches long for the use of embalmers.

b. Open the inferior vena cava from the bifurcation of the iliac veins to the level of the diaphragm.

37. Urinary Tract

Remove urine from the bladder with a syringe and needle if indicated. With a finger or blunt instrument separate the bladder from the extraperitoneal tissues of the retrosymphysial space so that the bladder and prostate are completely free from the pelvic wall. Futher dissection with the fingers posteriorly will separate the rectum from the body wall. A knife or curved scissors may be used to cut the urethra distal to the prostate and the rectum not less than 2 cm above the anorectal junction. Reflect the pelvic organs upward and outward, exposing the great iliac vessels. Free the kidneys and ureters by retracting them toward the midline from surrounding structures and remove them by a sharp dissection along with the bladder, internal genitalia, and rectum from the body in one block (fig. 9).

38. Kidneys

With a long knife divide the kidney into anterior and posterior halves by a straight, sharp single incision along the longitudinal axis of the convexity, as indicated in figure 10. With scissors open the pelves and the ureters, the renal artery and vein and their major branches. Record the weight, length, breadth, and depth of each kidney after severing the ureter. Strip the capsule to expose the surface of the parenchyma. If the kidney is small, record the number of pyramids. For histologic study remove a block of tissue 3 to 5 mm thick, including cortex, medulla, and pelvic mucous membrane from each kidney as shown in figure 11. Measure the thickness of the cortex and the thickness of the entire renal substance and if indicated, the diameter of renal artery and the ureters.

39. Urinary Bladder

Note whether the bladder is of normal size and configuration, or dilated or contracted. Open the bladder by a vertical incision on the anterior surface extending from the fundus to within a few millimeters of the internal urethral orifice. Invert and inspect the mucosa and wall. Select a block to include all layers of the wall for fixation.

40. Prostate

The prostate is examined by multiple coronal sections 5 to 6 mm apart, extending from the base of the bladder to the apex of the prostate. Inspect the mucosa of the urethra. Place one complete coronal block, including the posterior lobe, in fixative.

41. Rectum and Sigmoid

Open the rectum with an enterotome along the posterior midline. Remove fecal material and examine the mucosa and wall. Dissect the rectum from the posterior wall of the bladder and from the prostate to display the seminal vesicles in men. In women dissect the rectum from the vagina.

42. Seminal Vesicles

Multiple longitudinal incisions, 2 to 3 mm. apart, serve to expose the wall and the lumens of the vesicles. The thickness, the character of the wall, and the physical characteristics of the seminal fluid should be noted. Place a representative block in fixative.

43. Testes and Epididymides

a. Remove the testes by enlarging the inguinal canal, inverting the scrotum, and cutting the attachment of the tunica vaginalis to subcutaneous tissue of the lower part of the scrotum. If there are related pathologic changes in the genital tract, the testes should be mobilized before the pelvic organs are removed, as that the entire length of the vasa and the attachment to both the epididymides and the seminal vesicles are preserved.

b. Open the tunica vaginalis and note the amount

and physical characteristics of the fluid it contains. Incise testes and epididymes. If abnormality exists, record the weight and measurements. Observe the thickness of the tunica, the tissues of the epididymis, and the consistency of the testis. With forceps determine the ease with which the tubules "string" from the cut surface of the testis. Place a block from the opposite half in fixative.

44. Vas Deferens

Examine the vas deferens by multiple cross sections without completely dividing the structure. Note the size and richness of the pampiniform plexus and inspect the thrombi.

45. Examination of the Female Genitalia and Breasts

a. In autopsies of women the internal female genitalia are removed with the bladder and the rectum. Examine the bladder and separate it from the anterior surface of the vagina. Open the vagina along each lateral wall with knife or scissors. The incisions can be carried superiorly through the cervix and lateral walls of the uterus to the cornua, which exposes a larger portion of the endometrium for inspection. Record the thickness of the endometrium and myometrium, and the greatest length, breadth, and depth of the uterus. Examine the fallopian tubes by multiple cross sections. Bisect each ovary. Inspect the veins and arteries in the broad ligament. Fix blocks from the vagina, cervix, uterus, tubes and ovaries.

b. The mammary glands are conveniently examined after reflection of the skin and subcutaneous tissues over the thorax. Multiple sections from the posterior aspect extending to within a few millimeters of the skin will expose the mammary tissues. If the nipple is diseased it may be removed.

46. Removal and Examination of the Brain

a. When bacteriologic or viral studies of brain tissue are indicated by clinical history or gross appearances, the brain should be removed prior to embalming. For special directions concerning microbiological studies see paragraphs 96 through 108.

b. After examination of the scalp, an intermastoidal incision extending over the vertex of the skull is made with the blade of the scalpel turned outward to prevent cutting the hair (fig. 12). If the subject is bald, the incision should be placed as far posteriorly as possible and may sometimes be hidden by making the incision backward from points about 2 inches above the ear to encircle the scalp posteriorly within the hairline. It is advisable to start the incision behind the right ear and end it behind the left, so that if disfigurement occurs, it will be on the left side of the head. Embalmers regard the right side of the face as the "show" side. Reflect the scalp anteriorly to a line 1.5 cm above the supra-orbital ridge and posteriorly below the occiput. With a sharp instrument mark out the anterior saw cut from behind the ears over the frontal bone and, whenever possible, posterior to the hairline (fig. 13). The posterior cut should extend backward from the lower end of the anterior cut over the occipital bone to the midline at the level of the superior nuchal line, where it should meet with the posterior cut from the other side. The angle formed by the anterior and posterior skull incisions should be from 100° to 120°

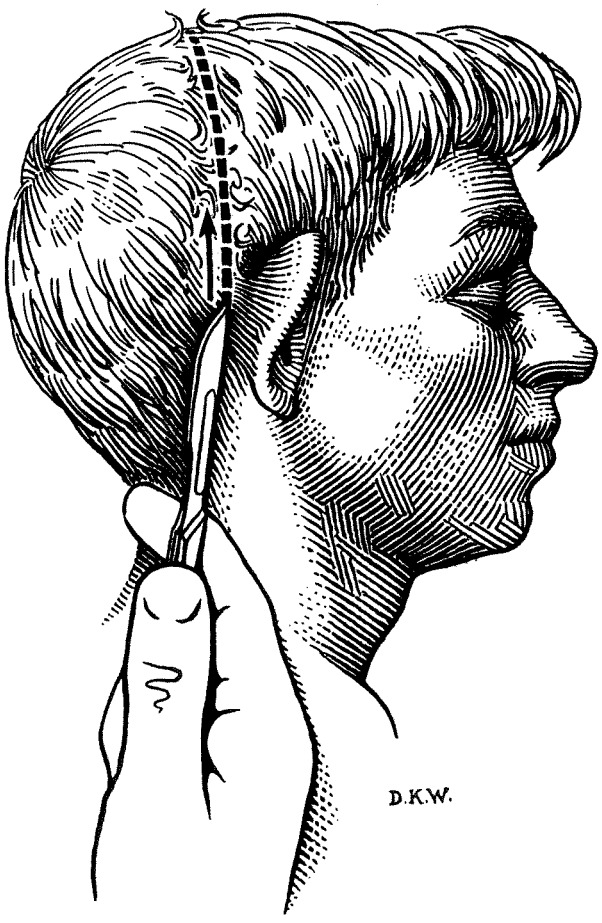

Figure 12.

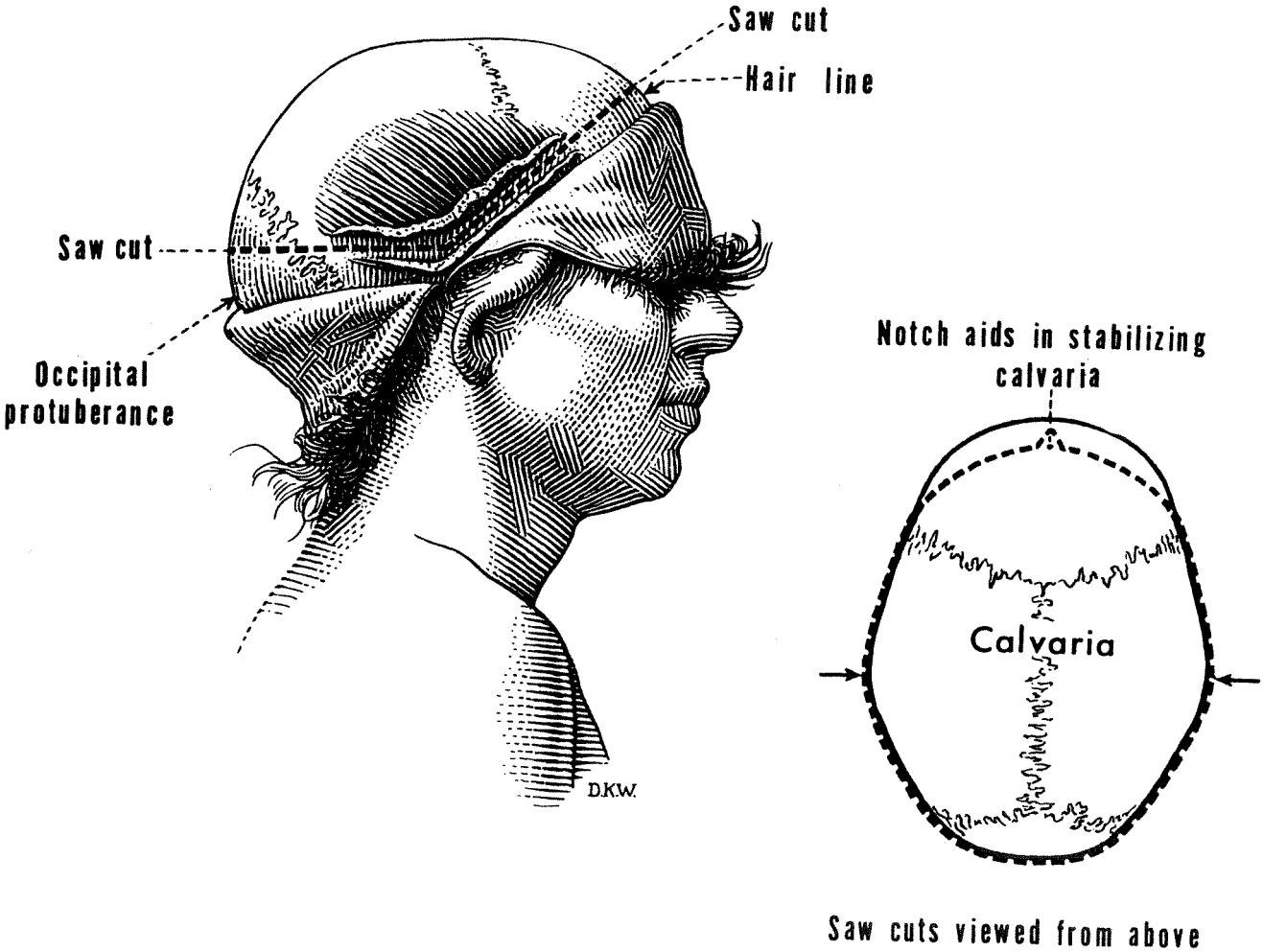
Saw cut
Hair line
Saw cut
Occipital protuberance
D.K.W.
Notch aids in stabilizing calvaria
Calvaria
Saw cuts viewed from above

Figure 13.

and should be so placed that neither limb, if extended, will intersect the external ear. This is of practical importance in protecting the ear from the saw. Use a scalpel to cut the temporal muscle and fascia along the plotted lines, and with a blunt instrument separate the tissues from the bone along the incision. Cut the entire thickness of the skull with fine tooth saw or Stryker saw but do not allow the saw to slip into the brain. Either notch the anterior and posterior saw cuts (fig. 13) or drill small holes on either side of the apex of the saw cut angle in the mastoid areas bilaterally for wire or heavy cord anchoring of the calvarium after brain removal. An alternate technique is to offset the lateral cuts in the skull in a modified "Z" shaped fashion. If there is a question of possible skull fracture, do not use hammer and chisel in removing the calvarium, since these implements may create fracture lines that will complicate medicolegal cases. Remove the calavarium, separating it from the underlying dura by blunt dissection between bone and dura. Inspect the superior sagittal sinus by opening it with scissors. Cut the dura with scissors along the edges of the bone and reflect it toward the midline. Use scissors to cut the falx cerebri anteriorly in the interhemispheric fissure and pull the dura posteriorly, cutting the cerebral veins as necessary and the great cerebral vein of Galen in the pineal fossa. With the left hand lift the frontal lobes, cut the very thin olfactory nerves beneath the olfactory bulbs and lift the olfactory bulbs and tracts. Cut the optic nerves at the optic foramina. Cut the internal carotid arteries. The left hand is shifted to support the cerebral hemispheres in the parieto-occipital region. The infundibulum and pituitary stalk can then be cut and cranial nerves III–XII are severed in order as the brain is supported to prevent traction on the cerebral peduncles. Place the left hand *beneath* the parietal and occipital lobes to support the weight of the brain and cut the tentorium cerebelli on each side at its peripheral attachments laterally and posteriorly. The dorsal surface of the cerebellum is thus exposed. The posterior cranial fossa is exposed and the remaining cranial nerves and the vertebral arteries can be severed. The vertebral arteries should be severed below the opening of the foramen magnum so that posterior inferior cerebellar arteries are included with the brain. Finally, the cervical cord is transected as far inferiorly as possible. This is best accomplished by a long-handled scalpel. The brain should settle gently into the left hand unless the occipital saw cut is too high, in which case, remove the brain by lifting it with both hands, being careful that all attachments are severed. The brain should be weighed in the fresh state and this data recorded both in the protocol and on the container of fixative in which it will be suspended. Two common errors that produce damage to the brain during removal are: (1) Failure to cut the tentorium or falx, and (2) failure to cut the vein of Galen.

c. After removal, fix the brain and spinal cord in 10 percent neutral formalin. Incision of the corpus callosum is optional. If the corpus callosum is incised to permit better fixation of the internal structures, a 1 cm cut should be made in the posterior part. Unnecessary distortion is produced when the entire corpus callosum is incised. Careless incision of the corpus callosum will damage the thalamus and basal ganglia. Suspend the brain by passing a string, attached to the edges of a jar containing *not less than* 1 gallon of fixative, beneath the basilar artery. The brain should be allowed to harden for 10 to 14 days before sectioning. *Important:* The fixing fluid should be changed during the first 24 hours and at the end of one week. An alternate method of suspending the brain in formalin is to tie the string loosely around the midbrain. This will preserve the shape of the basilar artery but it will produce a groove in the cerebellum or corpora quadrigemina. Cutting the brain in the fresh state is rarely necessary and greatly hampers interpretation. Fresh cutting, when unavoidable, is expedited somewhat by wetting the knife with 80–95 percent alcohol prior to each cut and by placing the cut surface firmly aganist a glass surface. The intact fixed brain and spinal cord may be forwarded to the Armed Forces Institute of Pathology together with appropriate clinical information.

d. Sectioning the fixed brain: Sections may be made in the horizontal or coronal plane, but the coronal plane is usually preferred. Sagittal, parasagittal, or oblique planes are used in special cases such as missile wounds or midline lesions. Horizontal planes are preferred for comparison with computerized tomography (CT) scans. Briefly, the usual technique involves serial coronal sections of the cerebral hemispheres at 1 cm intervals after careful inspection of the surface vessels, cranial nerves, "midline" structures; i.e., cingulate gyri, unci, mammillary bodies, pineal recess, and brainstem, following removal of the brainstem and cerebellum by thin knife section across the cerebral peduncles in a plane perpendicular to the brainstem and aqueduct. The latter procedure will permit inspection of the substantia nigra for pigmentation and an assessment of the caliber of the adueduct of Sylvius. Coronal sections should pass from base to vertex through conventional landmarks such as temporal tips, optic chiasm, mammillary bodies, red nuclei, aqueduct, pineal, etc. Sections may be oriented in PA or AP direction, and careful attention to this will prevent confusion of right and left hemispheres. The brainstem and cerebellum are cut at 0.5 cm intervals in a plane perpendicular to the long axis of the brainstem. The cere-

bellum may be sectioned parallel to the long axis of the brainstem after the initial section (in that plane) separates dorsal cerebellum from the tectum of the pons. Neuroanatomical atlases are most often published in these planes of section.

47. Examination of the Base of the Skull

a. Fractures of the Base. For demonstration of fractures the dura should be stripped from the bone. This is best done by winding it onto a hemostat attached to the cut edge of the dura. Some pathologists prefer to use "gas pliers." In either case the dura should be stripped immediately after the brain is removed and before chisel and hammer are used, since they may cause fractures.

b. Pituitary Gland. The posterior clinoid processes are broken away from the gland using a chisel or conventional wire cutters. The diaphragm of the sella is incised around its periphery and the pituitary gland removed by sharp dissection with gentle traction on the stalk. The entire gland is fixed in 10 percent formalin and later sectioned either horizontally or sagittaly. If a sagittal slice is used, additional sections of the left and right pars lateralis should be cut perpendicular to the mid sagittal slice, otherwise important changes in the center of each lobe will be missed. The National Pituitary Agency extracts critically short growth hormone from pituitary glands. When there is no history suggesting pituitary pathology and the pituitary is not grossly abnormal, the organ should not be fixed in formalin. The pituitary should be preserved and shipped according to guidelines obtained from the following address; The National Pituitary Agency, Suite 501-9, 210 West Fayette Street, Baltimore, MD 21201.

c. Dural Sinuses, Carotid Arteries, and Gasserian Ganglia. The dural sinuses, notably the cavernous, superior and inferior petrosal, saggital and sigmoidal, are opened with curved scissors. The carotid arteries may be traced through the walls ofthe cavernous sinus and in their canals by use of heavy scissors and a narrow chisel. If there is history of cerebral dysfunction, the patency of the carotids should be tested by slowly injecting saline solution into the common carotids and observing its flow out of the intracranial ends of the internal carotids. Formalin should not be used, because it might harden the features before the embalmer can "set" them. Water is inadvisable, because it may lake blood in the tissue and produce foci of discoloration. Remove the gasserian ganglia from the subdural pockets lateral to the cavernous sinus and place in 10 percent formalin.

48. Examination the Nasopharynx, Nasal and Paranasal Sinus Cavities.

a. The Stryker autopsy saw is preferably utilized for this examination. The first saw cut is made anterior to the hypophyseal fossa (sella turcica) at the base of the anterior clinoid process attachment (fig. 14, No. 1). The saw blade is directed slightly posteriorly (fig. 15) to facilitate replacement of the bone plug later in the restor-

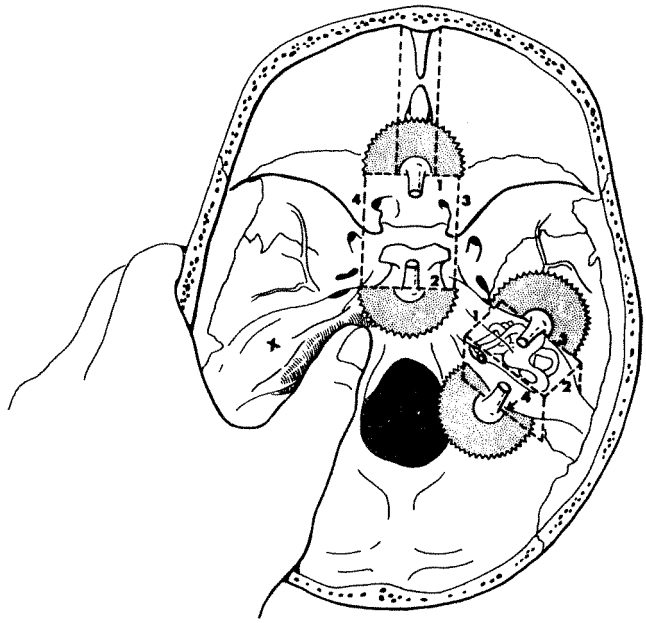

Figure 14.

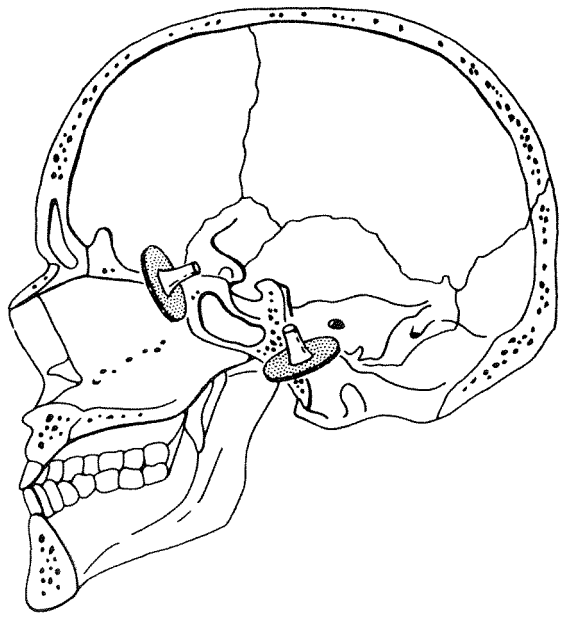

Figure 15.

ation process. The bone is thin and cavernous in this area and little resistance is met but the depth of the cut should be at least 2 cm. The second saw cut is made posterior to the posterior clinoid processes, the blade directed anteriorly and the depth of the cut being at least 2 cm. The bone in this area is quite dense. The third and fourth saw cuts are lateral hypophyseal fossa connecting the lateral ends of the two previous saw cuts (fig. 14, Nos. 3 and 4). The saw blade is slanted medially and this plug is now removed and saved for the restoration process. Any boney, ligamentous and tissue attachments are separated by scissors or chisel. Usually depending on its variable size and anatomy, the interior of the sphenoid sinus is now exposed. (If too large a block is cut to circumvent the sphenoid sinus, there may be a collapse of the face and head, particularly if the temporal bones have been removed.) Following examination of the sphenoid sinus, the wall and floor of the sinus is removed by chisel, scissors or saw. The nasopharynx, nasal choanal area and the superior surface of the soft palate are exposed. To examine the oropharynx and posterior tongue, the soft palate is removed by knife or scissors.

b. To visualize the nasal cavity and remaining paranasal sinuses, an elongated rectangle of bone 1 cm lateral to the crista galli and extending from the anterior margin of the previously removed bone plug to the frontal bone is removed (see fig. 15) and saved for restoration purposes. The underlying attached nasal septum and ethmoid sinuses are easily separated by scissors or knife. The upper portion of the nasal cavity as well as the ethmoid sinuses are exposed. Examination of the lower nasal cavity including the turbinates can be made by trimming away obstructing tissue. Entrance to the maxillary sinuses is accomplished by removing the middle turbinate and entering the sinus through it's medial wall. The orbit need not be disturbed with this examination. The frontal sinus is usually exposed on removal of the rectangular plate, but, if not, this sinus can be easily entered at the frontal portion of the anterior cranial cavity with hammer and chisel.

c. To prepare the nasopharynx, nasal and paranasal sinus for the embalming process, any tissue voids may be filled with liquid plaster of paris. The rectangular bony roof of the nasal cavity and the bone plug of the nasopharynx and sphenoid sinus area are then replaced. These can be sealed by filling the cranial cavity with liquid plaster of Paris.

49. Middle Ear Space

For autopsy examination limited to the middle ear space, the dura is first stripped from the floor of the middle cranial fossa. To identify the bony roof of the middle ear (tegman tympani), the index finger or thumb is placed over the meatus of the internal auditory canal (bony canal of the seventh and eight cranial nerves) and the remaining index finger or thumb of the same hand is extended over the rim of the calvarium edge and placed in the meatus of the external ear canal (see fig. 14). Firm pressure is made on the external canal meatus to compress the soft or cartilaginous outer portion of the canal. At a point midway between the thumb and forefinger, a visual or mental mark is made on the bony floor of the middle cranial fossa (see fig. 14) and this point is the roof of the middle ear space. If aseptic specimen procurement is desired, the bony floor of the middle cranial fossa can be sterilized conveniently by passing a flame (cigarette lighter, gasoline blow torch or bunsen burner) several times over the area. A sterile chisel is utilized to enter the middle ear through the previous designated point on the roof. (The bone at this point is usually paper thin.) The exposed middle ear space can then be adequately examined and exudate tissue and ossicles can be obtained (under sterile conditions if culture studies are appropriate). This area can be prepared for embalming by either filling the middle ear space with plaster of Paris or placing plaster of Paris impregnated pads over the floor of the middle cranial fossa. If desired the entire temporal bone can be removed for further study.

50. Removing the Temporal Bone

a. A Stryker autopsy saw with circular or fan blade is satisfactory for temporal bone removal. A special temporal bone saw attachment for the Stryker saw (the Schuknecht saw) is available commercially but requires special instructions and techniques. Thin bladed osteotomes or hammer and chisel may be utilized but they present quite a challenge in the satisfactory removal of a temporal bone. The cranial nerves are cut at their entrance into the skull prior to brain removal to preserve the seventh and eighth cranial nerve anatomy intact. Cooling the saw blade with a stream of water while cutting will minimize the possibility of heat damage to the delicate inner ear membranous structures.

b. The first saw cut (fig. 14 No. 1) is made vertically and prependicular to the superior petrosal border just anterior to the internal auditory meatus. (The superior petrosal border is the ridge of bone separating the middle and posterior cranial fossa.) This first saw cut is extended laterally and anterior to the squama (the lateral bony wall of the middle cranial fossa) and inferiorly to a depth of approximately 2.5 cm. The second saw cut is made at a point approximately 3 cm posterior to the internal auditory meatus. This second saw cut is made parallel to the first (perpendicular to the superior petrosal border) and likewise extended to the squama and inferiorly ap-

proximately 2.5 cm. The third saw cut is also vertical and essentially connects the lateral ends of the two previous cuts (fig. 14 No. 3) and extending inferiorly to a depth of approximately 2.5 cm. Care is taken not to cut or otherwise damage the squama in order to prevent cosmetic embalming difficulties. A fourth horizontal saw cut (fig. 14, No. 4) is made at the level of the jugular fossa and should correspond to the inferior extent of the first two saw cuts. This fourth saw cut should extend to the lateral skull wall essentially connecting with the third saw cut. The resulting box shaped block can usually be loosened by gentle "rocking" and the cutting of any ligamentous attachments with scissors. If areas of bony union persist then the use of a chisel and hammer will usually easily separate these attachments. Note: If the eustacian tube is to be included with the temporal bone block, then the first saw cut must be made anterior at the posterior clinoid process and parallel to the superior petrosal border.

c. After removal, the specimen is placed in at least 500 ml of 10 percent formalin per pair of temporal bones and the formalin solution changed every 24 hours for at least 3 days. Do not refrigerate removed specimen if histotechnical processing is desired.

d. To satisfactorily restore the temporal bone area for embalming, the internal carotid artery and external ear canal must be sealed. Also if both temporal bones are removed, the skull may be unstable and collapse. Liquid plaster of paris placed in the temporal bone cavities will prevent collapse and adequately seal the carotid arteries and external ear canals. If only one temporal bone is removed, the carotid artery can be ligated with suture material.

51. Removal of Eyes

a. Either the entire eye or the posterior half of the globe may be obtained from within the cranial cavity (*special permission required*). After removing the brain and pituitary, unroof the orbit and expose the optic nerve and eyeball (fig. 16). Apply traction on the extraocular muscles during the dissection to avoid crushing the nerve and eyeball. If the entire globe is removed, caution must be observed to avoid damage to the lids. Dissect the bulbar conjunctiva away from the globe, keeping the knife close to the corneoscleral limbus. The embalmer must be advised to suture the lids and restore the orbit.

b. Fix the eye and attached optic nerve in 300 to 500 ml neutral 10 percent formalin. It is not necessary to open the globe since aqueous formalin will penetrate the sclera and effect good fixation of the retina. After fixation, the eye should be opened with a double-edged razor blade in a horizontal plane so that the macula may be sectioned in line with the optic nerve and pupil.

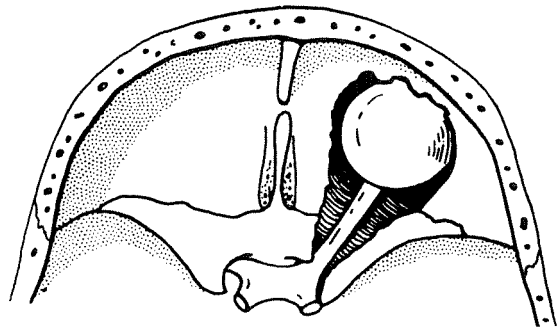

Figure 16.

52. Cisternal Puncture

a. The head is placed in a true lateral position and flexed maximally. Stabilize this position. The needle must be inserted just above the spine of the second vertebra, held at that point by the thumb, and then directed upward in the midline, using the top of the auricle (external ear) as a guide. The needle will usually touch the occiput, but by repeatedly withdrawing it slightly and depressing the point a little at a time it will enter the cisterna magna at such an angle that there is a distance of 2 to 3 cm. between the site of entry and the medulla. The distance from the skin to the cisterna varies, but in adults it is usually 4 to 5 cm. and *seldom* over 6 cm.

b. In some cases it may be more convenient to remove fluid by spinal puncture in the conventional manner.

53. Removal and Examination of the Spinal Cord

a. Approach. The spinal cord can be removed from the posterior or anterior approach. The latter is generally preferred because of the excessive time and labor involved in posterior laminectomy (especially in the adult). The disadvantage of the anterior approach is that dura and nerve roots above the mid-thoracic level are difficult to obtain.

b. Posterior Removal. The body is placed prone on the table, with a block beneath the thorax to arch the thoracic spine. The head is placed over the edge of the table with the face protected by a sponge or towel from deforming pressure. A skin incision is made in the midline from the base of the skull to the sacrum; the paraspinal muscles are retracted laterally and the spinous processes and laminae scraped clean of muscle and fascia. The laminae, close to the spinous processes are cut with a single or double bladed saw or with a specially devised chisel. If they are not entirely cut through, use a hammer and chisel to complete the separation. The spinous pro-

cesses and adjacent laminae are removed *en masse*. A laminectomy should not be done on the first cervical vertebra since it will destroy the rigidity of the connection between the head and the trunk. The spinal cord encased in its dura mater is removed by cutting the spinal nerves lateral to the posterior root ganglia and freeing the epidural tissue by sharp dissction. The cord may be damaged if it is pulled or bent to free it from the spinal canal. A better method is to apply traction in the line of the longitudinal axis of the cord by grasping the dura with forceps and exerting gentle force inferiorly. The dura is opened with scissors along the posterior or anterior midline and the cord is fixed by suspending it in a tall jar of 10 percent formalin, or by pinning the opened dura to a strip of wood in a long narrow covered dish (catheter tray) containing 10 percent formalin. Examination of the cord is made by means of multiple cross sections. Blocks for microscopic study and taken at appropriate levels.

c. Anterior Removal (modified from Kernohan). Following removal of the brain, the upper cervical nerve roots are cut intradurally with a long-handled scalpel as far inferiorly and laterally as possible. (This step may be repeated or extended if undue resistance is encountered later in the course of final removal.) After evisceration of thorax and abdomen, the vertebral column is freed from the attachments of psoas muscle and ligaments, and the large lumbosacral nerve plexi are identified. A generous sampling of peripheral nerve can be obtained from them at this time. Using these nerve trunks as a guide, cut the vertebral bodies (fig. 17) longitudinally from the sacral promentory to mid-thoracic level bilaterally with the large blade of an electric saw (chisel may be used but requires more skill and experience). A transverse cut through the vertebral body or intervertebral disc in the sacral region will permit separation of the vertebral column by grasping it with dry towel in hand. This will incompletely separate at the uppermost limit of the longitudinal saw cuts exposing the spinal cord dura and anterior nerve roots. The roots of the cauda equina should be freed from below and severed transversely. Once these are delivered anteriorly, proceed with extradural dissection dorsally and laterally cutting nerve roots and other attachments from below until the cord in its dural sheath is freed to the lower cervical level. Make encircling incision through the circumference of the dura at the upper limit of exposure. Complete separation of dura from the undissected rostral portion *must* be accomplished before proceeding. Carefully position the patient so that spinal column is straight (neck and head support removed). Sudden, firm traction applied in a straight line caudally will quickly free the entire spinal cord from remaining cervical attachments and it will be easily "delivered" without distortion. If there is excessive resistance, recheck alignment of spine and repeat root sectioning through foramen magnum from above before repeating traction maneuver. This maneuver sacrifices some of the cervical nerve roots, but it is preferred over the alternatives of complete dissection up to the foramen magnum.

54. Examination of Specific Peripheral Nerves and Neuromuscular Apparatus

When indicated, the peripheral nerves and the muscles they supply should be removed through longitudinal incisions in the skin (special permission required). Blocks of nerve tissue should be removed above and below the lesions and fixed in 10 percent formalin. Each block should be tagged individually or placed in a separate bottle of fixative with an identifying label.

55. Bones, Cartilages, Joints, and Bone Marrow

Whenever skeletal or joint disease is known or suspected, roentgenograms should be obtained or consulted to aid in the selection of material. Substantial amounts of bone should always be obtained in any autopsy with bone disease. In many cases it is advisable to obtain the consent of the next-of-kin and to consult with the mortician before removing bones or joints. The mortician may wish to do part of the embalming before or during the autopsy. Bones or cartilage for grafting should be taken only from certain types of cadavers, and the details and technique of selection should be discussed with the clinician who has requested the material.

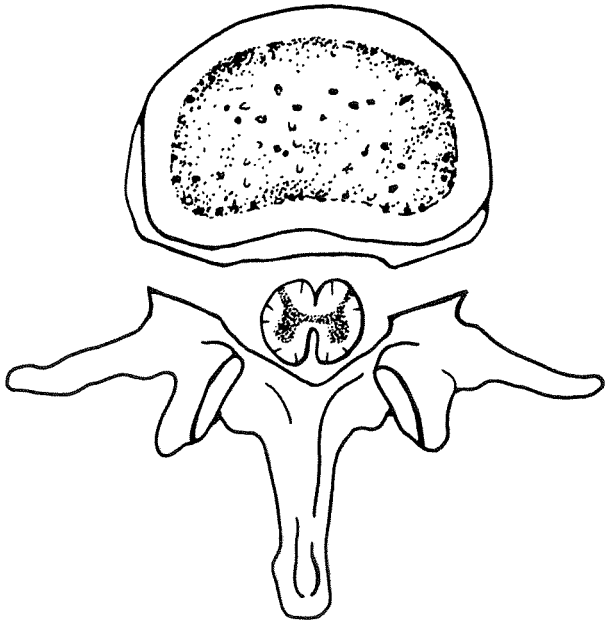

Figure 17.

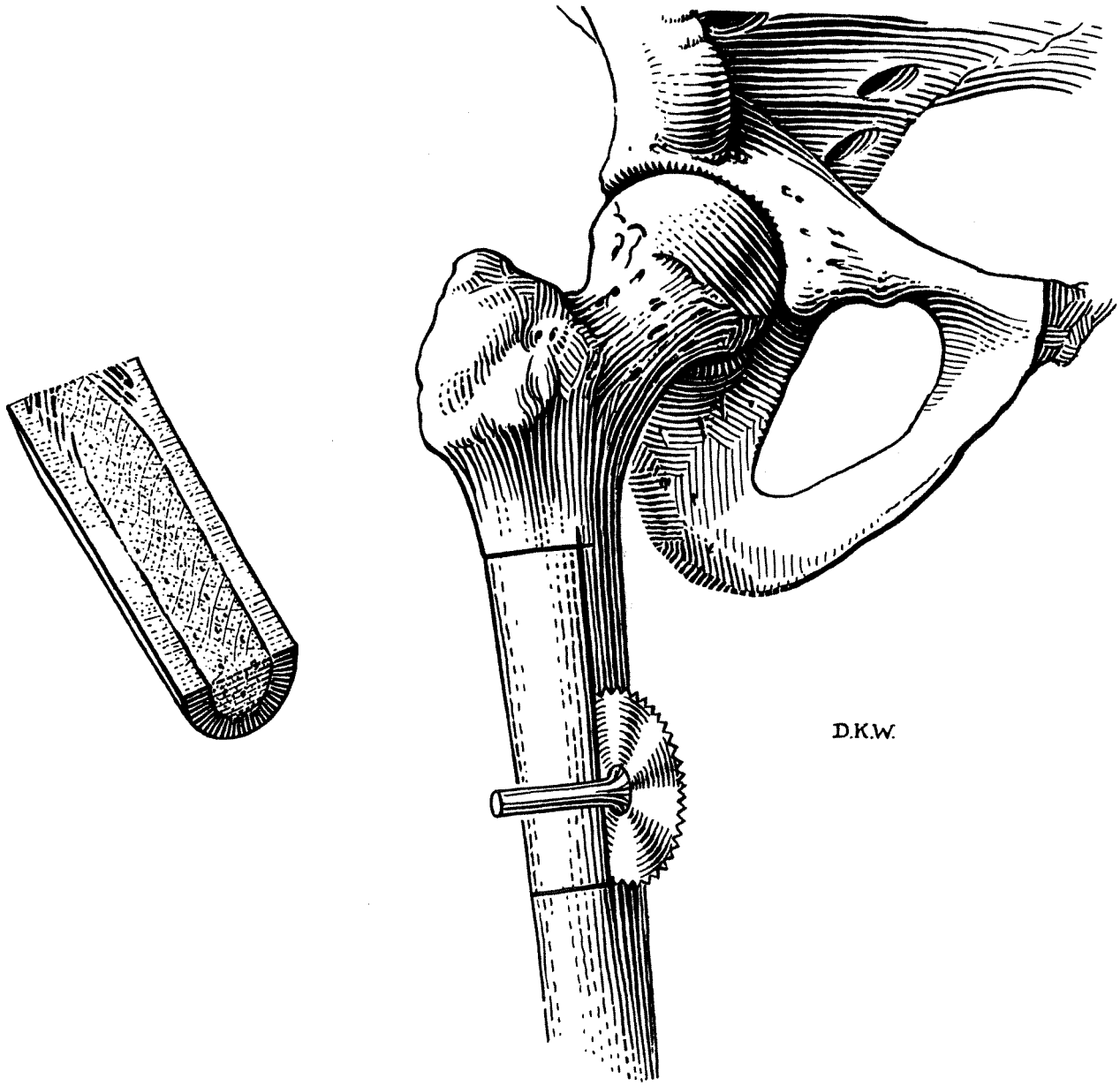

Figure 18.

56. Ribs

The study of nutritional deficiencies, metabolic derangements and other effects on osseous and cartilaginous growth may require the removal of several costochondral junctions. The specimen should include at least 2 cm of costal cartilage and 5 cm of rib (total of about 7-8 cm). The rib farthest from the cartilage should be used for cross-sections. The rest of the specimen should be used for longitudinal sections. These should be split or sawed longitudinally before fixation.

57. Calvarium

In certain anemias infections and other diseases, it is desirable to sample the calvarium. This can be done by removing bone from between two closely placed parallel saw cuts.

58. Digits

The small bones and joints of the hands and feet can be removed through palmar or plantar longitudinal incisions. The skeletal contours can be restored if necessary by inserting wooden substitutes for the resected bones. Special permission is necessary.

59. Extremities

Both proximal humerus and proximal femur, with a little care and effort, can be inverted into the usual Y incision area so that 1/4-1/3 of the length of the upper end of these two bones can be obtained without any special incision. For the humerus, this requires opening the capsule of the joint and inverting the humerus toward the mid-line. For the femur, it requires cutting the inguinal ligament and the superior portion of the acetabulum from within the pelvis in order to invert the upper femur into the pelvis. In both cases, the muscles can be stripped from the bone as the bone is inverted into the body area. In both cases, broom sticks or comparable wood sticks sharpened at one end should be driven into the medullary cavity of the bone that remains, and the proximal end tied with string to the scapula in the case of the humerus, and the pelvis in the case of the femur, in such a way that the limb appears normal externally. A segment of cortex and bone marrow can be removed from the bone shaft as demonstrated in figure 18.

60. Knee Joint

The knee joint can be exposed by an anterior curved incision immediately below the patella. Flex the knee in carry the incision through the quadriceps tendon to expose the joint. To dislocate the joint, cut the capsule and cruciate ligaments and free the muscle attachments. Tissue from the articular surfaces joint capsule, bursae, and tendons may be obtained. If the knee joint is to be removed as a unit, a longitudinal anteromedial incision is employed. In the case of a woman, the distal portion of the incision should be well above the hemline of the dress to be worn. The cooperation of the mortician is essential for this procedure, since loss of contour is invitable. Prosthesis may be accomplished by driving a wooden rod into the cut end of the shaft of the femur and proximal tibia.

61. Sternoclavicular Joints

The sternoclavicular joints are readily removed and offer an opportunity for the simultaneous examination of bone and joint. Prosthesis is generally unnecessary except occasionally to restore contour in women.

62. Vertebrae

The vertebrae can usually be satisfactorily examined either by removing the anterior halves of the bodies by means of a coronal saw cut or by inspecting the blocks obtained in removing the spinal cord by the anterior route. The vertebral column is best removed anteriorly. The entire column can be removed by transecting the intervertebral discs at the upper and lower end of the column and then cutting the pedicles with bone cutters after the muscles have been dissected away. In this manner, the entire length of the vertebral bodies can be removed for study and the entire length of the spinal cord together with the nerve routes will lie exposed and available for study and removal. The rigidity of the vertebral column can be restored by a stick of wood sharpened at both ends to be driven into the remaining vertebral bodies and tied with string via a coarse needle that goes around the stick and posterior to the laminae and spinous processes to hold the stick in place as a substitute for the missing vertebra. Wire and metal should never be used—only wood and string or cord, especially if the body is to be cremated.

63. Bone Marrow

Bone marrow may be obtained by the following methods:

a. Saw through anterior one-third of vertebra to expose the bone marrow. Dig out a block of bone marrow with cartilage knife and place in formalin fixation. Ethylenediaminetetraacetic acid (EDTA) decalcification will give excellent cellular detail and will allow for enzymatic studies such as the Leder stain. EDTA is also suggested if ultrastructural studies are contemplated on this marrow material. Touch imprints should be made if a hematologic process is present or suspected. Do not fix imprints in methanol if enzyme studies are contemplated. If a hematologic problem is not of concern and ultrastructural and enzyme stains are not of concern, Zenker's fluid may be used. Place tissue in 90 ml of Zenker's fluid

in which 10 ml of glacial acetic acid has been added for 24 hours. Usually sufficient decalcification of cancellous bone will have taken place to permit embedding and sectioning.

b. Scoop bone marrow from the femur from the incision demonstrated in figure 18.

c. Resect a segment of rib and squeeze out bone marrow by compressing the rib with a pair of pliers. Make smears on cover slips and slides and stain by Wright's method or with Giemsa stain after fixation for 2 minutes in absolute methyl alcohol. Dilute the bone marrow with an equal amount of serum to obtain thin spreads.

64. Examination of the Tissues of the Arm and Hand

A cardinal principle in all autopsies is that the skin of the face, the neck, the arms, and the hands must not be incised without *specific permission.* If the structures within the arm or hand must be examined, it is sometimes convenient to make a complete circular incision through the skin of the upper arm, and invert and roll the skin downward until the region to be examined is reached.

65. Examination of Tissues of the Face

Examination of the underlying tissues of the face should *not* be performed without *special permission* and important indication. None but the most expert should attempt this examination. The procedure is based upon the following steps: Preparation of a death mask, thorough embalming and hardening of the skin and subcutaneous tissues, dissection of these tissues from the underlying bone, and final restoration by placing the embalmed skin in the death mask and recasting the facial features with plaster of Paris behind the skin.

Section IV. REMOVAL OF THE VISCERA EN MASSE (ROKITANSKY METHOD)

66. Instructions for Removal

a. Following the primary incision and inspection of the viscera of the thorax and abdomen, the first step in the removal of the organs *en masse* is the freeing of the structures in the superior orifice of the thorax from their attachments. The three major branches of the arch of the aorta are ligated close to their origin and divided below the ligatures, which should be left with ends at least 15 inches long for the use of embalmers. The trachea and esophagus are transected just below the larynx. The thoracic organs are elevated, pulled inferiorly, and separated by blunt or sharp dissection from the vertebral column. Sometimes it will be advantageous to remove the tongue, larynx, pharynx, thyroid glands, and parthyroid glands along with the organ mass. Since it is necessary to leave the carotid arteries intact for embalming of the face and head, it is necessary to observe each step so that all visible branches of the carotids can be ligated to prevent excessive leakage from the main arteries during the injection of embalming fluid.

b. The second step is the separation of the diaphragm and peritoneum from the lateral and posterior abdominal walls. On each side the diaphragm is cut from its attachment to the body wall in such a way that the incision enters the abdominal wall extraperitoneally. By blunt dissection the remainder of the diaphragm and the entire lateral and posterior peritoneal walls are separated from the underlying tissues. Dissection is carried posteriorly to the vertebral column, behind the kidneys and the adrenal glands.

c. The third step is the separation of the abdominal organs from the vertebral column. This is best accomplished by lifting the thoracic organs onto the left side of the body and rotating the abdominal organs to expose the right side of the vertebral column. By sharp dissection the vena cava and aorta are separated from the vertebral column. The mass of thoracic and abdominal organs are replaced in the body cavity until attachments in the pelvis are severed. The fourth step is the insertion of a finger or blunt instrument into the extraperitoneal tissues of the retrosymphysial space and the separation of the bladder and prostate (or vagina) from the pelvic wall. Further dissection posteriorly will separate the rectum, which some pathologists tie by double ligatures 2 cm apart and about 2 cm above the anorectal junction. An amputation knife is employed to cut the urethra and associated structures as close to the pelvic outlet as is convenient. The rectum is severed 2 cm above the anorectal junction (fig. 9). The pelvic organs may then be reflected upward and outward, exposing the great iliac vessels, which are divided along the brim of the pelvis. All of the tissues can be separated from the curve of the sacrum and the convexity of the lower lumbar vertebrae by blunt dissection. The entire organ mass can now be lifted from the body.

67. Removal of External Genitalia

a. If it is necessary to remove the tissues of the floor of the pelvis or part or all of the external genitalia, the incision in the abdominal wall should be extended inferiorly over the symphsis pubis to the base of the penis

or to the crest of the labia majora. The symphysis pubis is divided with a large blunt cartilage knife and the legs abducted to expose the urogenital triangle. Further dissection will depend on the exigencies of the case.

b. In men the skin is incised on the dorsal surface of the penis, the contained tissue dissected free and taken with the pelvic organs, or a deep incision is made around the penis and scrotum to free these structures and leave them in continuity with the other pelvic viscera.

c. In women an incision around the labia and through the deep tissues will permit the entire external genitalia to be removed along with the pelvic organs.

68. Lungs

See paragraph 25.

69. Abdominal Viscera

Place double ligatures about the jejunum just below the ligament of Treitz. Beginning at the ileocecal valve, separate the colon by sharp dissection from the surrounding tissues as far as the rectosigmoid, which earlier was divided from the rectum.

70. Intestine

Use a long, sharp knife to separate the intestine from the mesentery as close as possible to the intestine. Open the intestine with blunt scissors or an enterotome along the mesenteric attachment. As the intestine is opened note the fluidity, color, and other characteristics of the intestinal contents. Take sections of representative regions. Do not rub the fingers over the mucosa or wash it with water before the sections are placed in fixative. Record the thickness, consistency, and color of the mucosa and of the wall as a whole. Open the colon along one of the taenia. The appendix may be examined by multiple cross sections or by a longitudinal incision through the lumen. Place selected segments of the wall of several parts of the intestine in fixative.

71. Stomach and Duodenum

Extend the previous incision in the esophagus along the greater curvature of the stomach and in the anterior midline of the duodenum, thus exposing the interior of the stomach and duodenum and the major papilla. Note the character of the contents and the state of the mucosa and wall.

72. Liver, Gallbladder, Ducts and Porta Hepatis

See paragraphs 31 and 34.

73. Spleen and Splenic Vessels

The superior surface of the pancreas should be exposed and the splenic artery and vein examined by multiple cross sections or by longitudinal incisions. The spleen may now be separated by division of the structures of the hilum. The parenchyma is exposed by a single incision extending from the greatest convexity toward the hilum. Further incisions should be parallel to the first. Fix a characteristic part of the organ including the capsule.

74. Lymph Nodes

See paragraph 30.

75. Pancreas

Measure the organ. Dissect it away from the adjacent structures and weigh it. Make numerous parallel cross sections. Examine the ductal system and the appearance of the parenchyma. Take blocks from the head, body, and tail. The tail contains more islets and should be routinely processed for microscopic examination. Other blocks should be processed later if abnormalities are found in the tail during the microscopic study. Remember that early examination of the pancreas during the course of the autopsy will reduce the amount of autolysis likely to occur.

76. Retroperitoneal Structures in the Midline

Place the organs on the table with the posterior surface upward. Use scissors to open the iliac veins and the inferior vena cava as far superiorly as the right renal artery, which should not be divided until it is opened. Dissect and examine the retroperitoneal lymph nodes. Open the iliac arteries and the aorta as far superiorly as the arch. Notice the size and character of the orifices of the major branches of the aorta, particularly the renal arteries.

77. Adrenals

From the region of the angle formed by the diaphragm, the aorta, and the kidneys, dissect and remove the adrenal glands. Free them of all extraneous tissue, weigh them, and examine by making parallel sections. Place all or part of both in 10 percent formalin.

78. Aorta and Vena Cava

Free the kidneys and ureters from the surrounding tissue and separate the aorta from the root of the mesentery by sharp dissection, noting the size and thickness of the wall of all branches. Reflect the aorta, renal arteries, and kidneys downward, following the ureters to the bladder. The kidneys, ureters, bladder, and associated structures can now be studied as a unit.

79. Other Organs

a. Esophagus.

(1) The next step in the dissection and examination

of the viscera is to open the esophagus along the posterior midline. Examine the mucosa and wall. Elevate the esophagus and dissect it free from the adjacent posterior mediastinal structures as far inferiorly as the cardia. Cut a block and place in fixative.

(2) The thoracic and abdominal viscera may then be separated from one another by division of the inferior vena cava just above the caval hiatus in the diaphragm, leaving the diaphragm with the abdominal organs.

b. Kidneys (para 38.)

c. Bladder (para 39).

d. Prostate (para 40).

e. Rectum (para 41).

f. Seminal Vesicles (para 42).

g. Testis and Epididymis (para 43).

h. Vas Deferens (para 44).

i. Female Genitalia and Breasts (para 45).

CHAPTER 3
PEDIATRIC AUTOPSIES WITH SPECIAL REFERENCE TO INFANTS AND FETUSES

Section I. PRELIMINARY CONSIDERATIONS

80. General

The paragraphs dealing with various phases of autopsies performed on adult bodies are applicable to children and older infants, but special attention must be given certain details and the procedures modified in the case of newborn infants and fetuses.

81. Permission

a. A fetus under 22 weeks gestation, born dead, and measuring less than 25 to 28 cm in length, is generally considered a surgical specimen or abortus. In such a case no autopsy permit, death certificate, or burial ceremony is required. It is important to know the local law in this respect since it varies somewhat in different localities. The local coroner, Medical Examiner or Public Health Officer should be consulted for legal procedures.

b. Regardless of the time of gestation or the measurements, a newborn infant that shows any evidence of life, even though it be only momentary, after complete birth, must be registered as a live birth, and a death certificate filed.

c. Legal permission is required to perform an autopsy on any child born alive, regardless of length of gestation or measurements. Such permission is also required in the case of newborn infants which are born dead but have developed to the stage of viability (para 7*c*).

82. Proper Care of the Body

Viable infants and fetuses which are to be viewed after autopsy should be examined in such a manner that no incisions or mutilations will be visible. If there is little or no hair on the scalp, the skin incision for opening the head should be made as far posteriorly as practicable.

83. Clinical History

Since little or no history of the infant may be obtained, the clinical record of the mother should be consulted. Facts concerning pregnancy, labor, delivery, and past history, especially with regard to illnesses and pregnancies, may supply significant information. In some cases the blood type of mother and father and serologic studies for Rh antibodies in the mother are invaluable in final evaluation of the autopsy. Past history of siblings may also be helpful.

Section II. TECHNIQUE

84. Variations

The autopsy technique for newborn infants and fetuses varies in certain detail from that used in adults or older children as follows:

a. External Examination. Special attention should be given to the fontanels, the umbilicus, the umbilical cord, and the placenta. Careful inspection for evidence of maceration, cyanosis, injury and skin lesions should be made. The body should be weighed on an accurate scale and the measurements of the crown heel (standing) and crown rump (sitting) height should be taken. Other important measurements should include the head, chest and abdominal circumference, arm span and foot length. Anomalous development should be noted and photographed if possible. In cases of infectious disease of the central nervous system, an attempt should be made to obtain cerebrospinal fluid aseptically from the cisterna magna. This fluid can be used for smears, cell count and cultures.

b. Primary Incisions. The primary incisions are the same as that used for adults, except the scalp incision is placed as far posteriorly as practicable. Air within the thoracic cavity can be checked for by opening the chest under water and observing for escape of air bubbles. This may also be accomplished by inserting a needle with attached syringe between the ribs and attempting to draw air into the syringe. This should be performed on both sides of the chest. When the chest is opened, blood for typing, serologic tests and culture may be obtained.

c. Organ Removal. By using the method of block dissection and removal, the relationships of the various structures can be better preserved. For example, anomalies of the cardiovascular system or genitourinary system can be shown to advantage by removing the heart and lungs or the entire genitourinary system as a unit.

d. Brain and Spinal Cord.

(1) The skull of a young infant or fetus is opened by the Beneke technique. Parasutural cuts which avoid the dural venous sinuses are made with a scissors, and a parietal flap folded down on each side. By gently pushing aside the cerebral hemispheres and lifting the occipital poles of the brain it is possible to examine the region of the great vein of Galen, the falx cerebri, and the tentorium cerebelli for tears and hemorrhage.

(2) In older infants or children, the skull must be cut with a saw, as in adults. The spinal cord can be removed by either an anterior or posterior approach, similar in principle to the methods used in adults.

85. The Placenta and Umbilical Cord

Autopsy of a newborn infant or fetus is not complete without examination of the placenta and umbilical cord. In most cases it is possible to determine whether twins are of single or of double ovum type by microscopic examination of the septum between the two amniotic cavities. In other cases, the weight and size of the placenta as well as the microscopic examination of the chorionic villi will aid in establishing a diagnosis of hemolytic disease of the newborn, congenital syphilis, or other disease.

86. Cause of Death

a. Although the physician in charge of the patient is responsible for signing the death certificate, he usually depends on the pathologist for help in establishing the cause of death. In many cases, the pathologist will be unable to find anatomical evidence of the cause of death, especially in an infant or child, but a careful study of the historical events and attention to details of the autopsy, together with microscopic examination, will often produce important evidence.

b. See appendix C: table 3, Average Weights and Measurements of Normal Organs (Infants and Children); table 4, Organ Weight in Relation to Body Weight in Newborn Infants; table 5, Criteria for Classification as to Period of Development.

c. For more details see: Potter E.L. and Craig, J.M.: *Pathology of the Fetus and the Infant.* Year Book Medical Publishers Inc., 1975.

CHAPTER 4
AIRCRAFT ACCIDENT AUTOPSIES

Section I. GENERAL

87. Directives

The performance of autopsies on aircrew fatalities is an essential procedure in the investigation of an aircraft accident. In addition, autopsy examination of other fatalities who die as a result of the accident frequently yields information that assists in determination of the cause of the accident. The importance of postmortem examinations to flight safety cannot be overemphasized. The following governing directives should be consulted:

a. Joint Army, Navy, Air Force.

(1) AR 15-97; BUMEDINST 6510.6A ENCL (1); AFR 161-41: Joint Committee on Aviation Pathology.

(2) AR 95-30;OPNAVINST 3750.16A; AFR 127-11; CG 307: Participation in a Military or Civil Aircraft Accident Safety Investigation.

b. Army.

(1) AR 40-21: Medical Aspects of Army Aircraft Accident Investigation.

(2) AR 95-5: Aircraft Accident Prevention, Investigation, and Reporting.

(3) AR 385-10: Army Safety Program.

(4) AR 385-40: Accident Reporting and Records.

c. Navy.

(1) BUMEDINST 6510.6A: Aviation Pathology Program.

(2) Manual of the Medical Department, US Navy, Article 17-24, Post-Mortem Examinations and Autopsies.

(3) OPNAVINST 3750.6K: Navy Aircraft Incident and Ground Accident Reporting Procedures.

(4) Navy Safety Center Memo 14-MN, 3750, 27 August 1979.

d. Air Force.

(1) AFM 127-1: Aircraft Accident Prevention and Investigation.

(2) AFM 127-2: USAF Accident/Incident Reporting.

(3) AFR 127-4: Investigation and Reporting US Air Force Mishaps.

(4) AFR 160-109: Medical Investigation of Aircraft Accident Fatalities.

88. Persons Authorized to Perform Aircraft Accident Autopsies

The autopsy should be performed by a pathologist, preferably one with special training in aviation or forensic pathology.

89. Knowledge of Accident

a. The flight surgeon should assist the prosector and provide information concerning the circumstances of the accident. The autopsy should not be undertaken without specific knowledge of the accident, such as history of the flight, suspected cause of the accident, position of the aircrew, etc. It is helpful to visit the scene of the accident to gain firsthand information. Photographs of the body and aircraft are indispensable.

b. If the cause of the accident is well established, the prosector should try to determine how the crew member sustained his injuries and what measures can be taken to prevent similar injuries to others. *If the cause of the accident is unknown,* the prosector should gain as much information about the accident as possible before he starts the autopsy. The autopsy should be a meticulous study and should utilize as many adjunctive techniques as needed. An adequate number of radiographs and photographs should always be obtained. It is better to have an excessive number of photographs or radiographs rather than find out too late that too few were taken.

Section II. RECORDING OF DATA

90. Medical Report of Aircraft Accidents

The medical investigations of aircraft accidents are reported in accordance with AR 385-40, OPNAVINST 3750.6K, AFR 160-109 and AFM 127-2.

91. Report of Autopsy

a. DD Form 1322 (Aircraft Accident Autopsy Report) (fig. 19) will be used. This form should be used as a checklist and should be supplemented by a narrative autopsy report (see para 92-95), toxicology report, photographs and radiographs.

b. The following information amplifies and explains pertinent data required and method of preparation:

(1) *Items 1 through 12,* deal with administrative data; in item 5 the time sequence of the accident should

be expressed as date and time of day. Item 6 should give the altitude at the time of emergency; and if this is unknown it should be estimated.

(2) *Items 13 through 16,* deal with the major injuries incurred and the circumstances of the accident. Items 15 and 16 should be as complete as possible and where indicated item 16 should be supplemented with photographs.

(3) *Item 17, Condition of Wearing Apparel,* concerns the condition of wearing apparel and protective equipment and should contain all details observed. Additional sheets of paper can be attached for full information if necessary.

(4) *Items 18 through 20, Condition and Exposure of Body at Site of Crash.* Item 18 in particular should offer information regarding the details of the condition of the body and the possible elements to which it has been exposed; the remainder of the form is concerned with observations at autopsy.

(5) *Items 21 through 24, Condition at Autopsy,* deal with the general inspection of the body surfaces. Any external observations which were not obvious on inspection at the site of the accident should be added in item 22.

AIRCRAFT ACCIDENT AUTOPSY REPORT

(Attach additional sheets of 8 x 10½ paper, as required)

DATE: 15 JAN 76

1. LAST NAME · FIRST NAME · MIDDLE NAME	2. GRADE	3. SERVICE NO./ SOCIAL SECURITY ACCOUNT NUMBER	4. AGE
DOE, JOHN JAMES	1/LT	123-45-6789	25

5. TIME *(Date, Days, Hours)*

LAST REPORT FROM PILOT	CRASH	CASUALTY SURVIVED	DEATH	AUTOPSY	6. ALTITUDE AT TIME OF EMERGENCY *(Estimated)*
1457 EST 15 JAN 76	1502 EST 15 JAN 76	SUDDEN DEATH	1502 EST 15 JAN 76	1800 EST 15 JAN 76	800 FEET

7. AIRCRAFT TYPE	7. AIRCRAFT NUMBER	8. CRASH SITE
T-33A	11-111	3 MILES S. E. OF ZIPPY AFB, COLORADO IN OPEN PLOWED FIELD

MEDICAL MEMBER OF BOARD

9. NAME	10. RANK/GRADE	11. SERVICE NO./ SSAN	12. ORGANIZATIONAL UNIT
ROBERT R. STACK	MAJOR	123-40-4321	4TH USAF HOSPITAL

13. MAJOR INJURIES *(List anatomical findings in order of importance stating probable cause of death and if possible, check which injuries were incurred ante- or post mortem.) (Attach additional sheets of paper, if required.)*

14. CHECK APPROPRIATE NUMBER TO INDICATE WHEN INJURIES WERE SUSTAINED: *1- In aircraft in air; 2- In aircraft on ground; 3- On ejection; 4- Other; 5- Indeterminate when received.*

LINE	INJURIES	ANTE-	POST-	1	2	3	4	5
A	PARTIAL DECAPITATION W/AVULSION OF BRAIN	X		☐	☒	☐	☐	☐
B	RUPTURE OF AORTA	X		☐	☒	☐	☐	☐
C	MULTIPLE FRACTURES	X		☐	☒	☐	☐	☐
D	3RD° BURNS, ENTIRE BODY		X	☐	☒	☐	☐	☐
E				☐	☐	☐	☐	☐

15. GIVE BRIEF DESCRIPTION OF FACTORS AND EVENTS LEADING TO ACCIDENT AND OTHER PERTINENT INFORMATION OR SUGGESTIONS

ON BANK FOR FINAL APPROACH, PILOT EXPERIENCED FLAMEOUT WITH SUDDEN LOSS OF ALTITUDE. PLANE CONTACTED GROUND LEFT WING AND NOSE LOW ALTITUDE. EXPLOSION AND FIRE ON IMPACT

16. STATE BRIEFLY POSITION AND DISTANCE OF BODY OR FRAGMENTS WITH RESPECT TO AIRCRAFT WRECKAGE

INTACT BODY FOUND IN COCKPIT OF BURNING AIRCRAFT.

17. CONDITION OF WEARING APPAREL

ITEM	PRESENT	MARRED	TORN	DIS-COLORED	BURNED	IN-PLACE	OFF-BODY	OTHER
HARNESS	X				X	X		
PROTECTIVE HELMET	X	X			X		X	
VISOR	X				X			
OXYGEN MASK	X				X			
GLOVES	X				X			
CLOTHING	X		X		X	X		
SHOES OR BOOTS	X	X			X	X		
OTHER *(Specify)*								

CONDITION AND EXPOSURE OF BODY AT SITE OF CRASH

18. CONDITION *(Gross description, extent of fragmentation and details of exposure of fragments.)*

PARTIAL DECAPITATION WITH POSTMORTEM 3RD DEGREE BURNS.

20. EXPOSURE ☐ NONE

	FIRE PRIOR TO CRASH		WATER
X	FIRE AFTER CRASH		DIRT, MUD, ETC.
X	FUEL	X	OTHER *(Specify)* FOAMITE

SPECIFY TIME AND DEGREE

10 MINUTES - SEVERE

19. COULD THE DECEASED HAVE TAKEN SEVERAL BREATHS BETWEEN TIME OF CRASH AND TIME OF DEATH ☐ YES ☒ NO

DD FORM 1 JUN 60 1322 REPLACES AF FORM 800, OCT 56, WHICH WILL BE USED UNTIL STOCK IS EXHAUSTED.

Figure 19 (1).

CONDITION AT AUTOPSY

21. BODY		22. REMARKS	23. PRESERVATION			
X	COMPLETE	3RD DEGREE BURNS ENTIRE BODY AVULSION SKIN & SUB-CUTANEOUS TISSUE EXTREMITIES	X	GOOD		ADVANCED POST MORTEM CHANGES
	RIGHT ARM AMPUTATED			EARLY POST MORTEM CHANGES		PUTREFACTION
	LEFT ARM AMPUTATED		24. STATE OF NUTRITION			
	RIGHT LEG AMPUTATED		☐ NORMAL		☐ OBESE	☒ SLENDER
	LEFT LEG AMPUTATED		THICKNESS OF SKIN AND SUBCUTANEOUS TISSUE OF ABDOMINAL WALL (CM) 2 CM			
X	DECAPITATED		WEIGHT OF BODY 150		LENGTH OF BODY 68"	
	DISINTEGRATED					

25. EXTERNAL/SKELETAL EXAMINATION

(Supplement with photographs where possible. Attach additional sheets of 8 x 10½ paper, as required.)

In each instance during External Examination specify exact location of the injury, abrasion, amputation, burn and degree, contusion, discoloration, hemorrhage, whether pre-existing or acquired. Also give opinion as to possible cause of injury.

In each instance during Skeletal Examination specify exact location and type of fracture or dislocation. X-rays to be used where possible. Give opinion as to probable direction and magnitude of force causing injury. Available skeletal diagrams should be used.

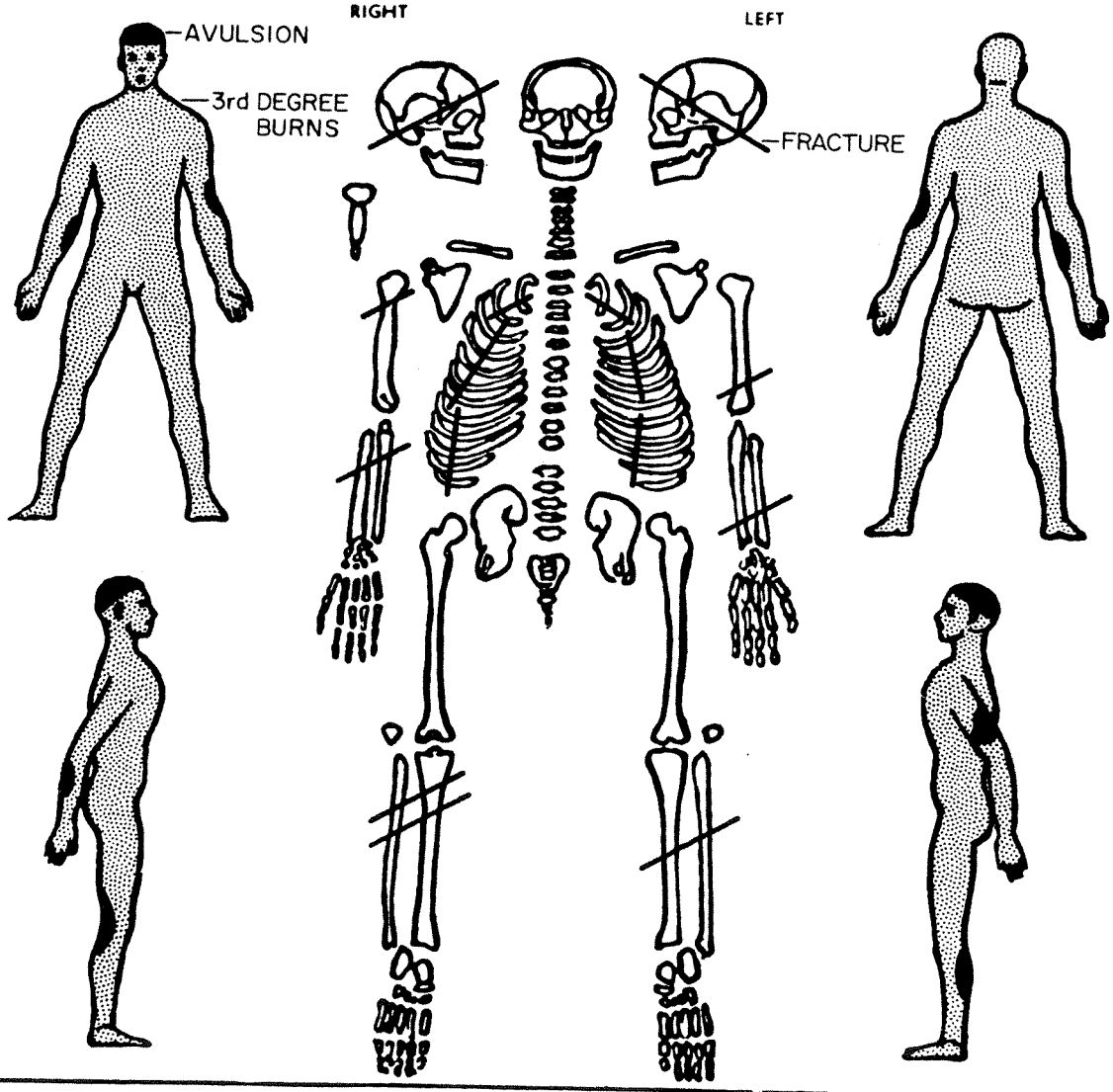

2

Figure 19 (2).

INTERNAL

(The degree of injury should be assessed as Mild +; Moderate ++; Severe +++; or Extreme ++++; Organs showing significance pathologic changes should be preserved. Attach additional sheets of paper, as required.)

26. BRAIN

(The whole brain should be preserved in 10% N. Formalin after tissue is removed for toxicology.)

☐ NORMAL ☒ MISSING ☐ AIR EMBOLISM	WEIGHT ------	PRE-EXISTING LESIONS	CONTUSION	HEMORRHAGE (Degree)

LACERATION	CONDITION OF CEREBRAL VESSELS (Especially basilar)

27. SPINAL CORD

(Spinal cords are important, remove at all times)

☐ NORMAL ☐ MISSING	PRE-EXISTING LESIONS NONE	DAMAGE SUSTAINED LACERATED SUPERIOR END

28. SINUSES

☒ NORMAL ☐ MISSING	HEMORRHAGE	OTHER

29. GLOTTIS

☐ NORMAL ☐ MISSING	LESIONS (Degree)	HEMORRHAGE

30. MIDDLE AND INNER EAR

	NORMAL	MISSING	HEMORRHAGE (Degree)	OTHER (Specify)
RIGHT	X			
LEFT	X			

31. EYES

	NORMAL	MISSING	HEMORRHAGE (Degree)	OTHER (Specify)
RIGHT			SEVERE	BURNED
LEFT			SEVERE	BURNED

32. ORAL CAVITY

☒ NORMAL ☐ MISSING	OTHER LESIONS NONE

33. LARYNX

☒ NORMAL ☐ MISSING	EDEMA NO	FRACTURE OF CRICOID BONE YES	FRACTURE OF THYROID BONE NO	HEMORRHAGE (Degree) MODERATE	OTHER (Specify)

34. PLEURAL SPACE

	NORMAL	MISSING	PNEUMOTHORAX	HEMOTHORAX (CC)	OTHER (Specify)
RIGHT			YES	175 cc.	
LEFT			YES	800 cc.	

LESIONS OF PLEURA

35. TRACHEA

☐ NORMAL ☐ MISSING	VOMITUS ------	BLOOD YES	OTHER ------	EVIDENCE OF ANTE-MORTEM BURNING NO

36. LUNGS

(Specify lesions by lobes when indicated)

	RIGHT	LEFT
NORMAL		
WEIGHT	520 GM.	465 GM.
MISSING		
ATELECTASIS	X	X
EDEMA		
RUPTURE		
FAT EMBOLISM		
HEMORRHAGE	X	X
EMPHYSEMA	X	X
MOTTLING — RIB MARKING		
MOTTLING — NO RIB MARKING	X	X
EVIDENCE OF DROWNING	NO	NO
OTHER (Specify)		

37. GREAT VESSELS

☐ NORMAL ☐ MISSING	PRE-EXISTING LESIONS SLIGHT ATHEROSCLEROSIS

TRAUMA (Describe) RUPTURE OF AORTA 2 CM. INFERIOR TO LEFT SUBCLAVIAN ARTERY.

38. PERICARDIUM

☒ NORMAL ☐ MISSING

PRE-EXISTING LESIONS NONE	
HEMOPERICARDIUM (CC) NONE	
PETECHIAE ON VISCERAL SURFACE NONE	
RUPTURE NO	OTHER (Specify) NONE

3

Figure 19 (3).

INTERNAL (Continued)

38. HEART

[X] NORMAL	[ ] MISSING	[ ] EVIDENCE OF AIR EMBOLISM	WEIGHT 300GMS	PATENT FORAMEN OVALE (State size) NO	PRE-EXISTING LESIONS (Describe) NONE

INJURIES (Describe)

DEGREE	INVOLVEMENT	CAUSE	ENDOCARDIAL RUPTURE
------	NONE	------	------

FULL THICKNESS RUPTURE	STATE OF CORONARY VESSELS (Describe)
------	NORMAL

40. PERITONEUM

[X] NORMAL	[ ] MISSING	PRE-EXISTING LESIONS NONE

OTHER LESIONS	TYPE & AMOUNT OF FLUID
NONE	NONE

41. STOMACH

[X] NORMAL	[ ] MISSING	PRE-EXISTING LESIONS NONE

DISTENTION	RUPTURE
NO	NONE

NATURE OF CONTENTS: PARTIALLY DIGESTED FOOD

42. INTESTINES

[X] NORMAL	[ ] MISSING	PRE-EXISTING LESIONS NONE

DISTENTION (Describe)	HEMORRHAGE (Degree)
NO	NONE

OTHER LESIONS (Include mesentery): NONE

43. LIVER

[X] NORMAL	[ ] MISSING	WEIGHT 1500GMS	PRE-EXISTING LESIONS NONE

TRAUMA (Degree and cause): NONE

OTHER LESIONS (Describe): NONE

44. SPLEEN

[X] NORMAL	[ ] MISSING	WEIGHT 160GMS	PRE-EXISTING LESIONS NONE

TRAUMA (Degree and Cause): NONE

OTHER LESIONS: NONE

45. PANCREAS

[X] NORMAL	[ ] MISSING	WEIGHT 100GMS	PRE-EXISTING LESIONS NONE

TRAUMA (Degree and Cause): NONE

OTHER LESIONS: NONE

46. KIDNEY

	RIGHT	LEFT
NORMAL	X	X
MISSING		
WEIGHT	150 GM.	150 GM.
TRAUMATIC LESIONS (Describe)	NONE	NONE
OTHER LESIONS (Describe)	NONE	NONE

47. BLADDER

[X] NORMAL	[ ] MISSING	PRE-EXISTING LESIONS NONE

DISTENTION	CONTENTS	RUPTURED
NONE	20 CC. OF URINE	NO

48. OTHER ORGANS

(Describe any lesions or traumatic changes noted in items listed below.)

THYMUS	THYROID	ADRENALS	GALL BLADDER
NORMAL	NORMAL	NORMAL	NORMAL
TESTIS AND PENIS	**PROSTATE**	**PITUITARY**	**LYMPH NODES**
BURNED	NORMAL	NORMAL	NORMAL

49. BIOCHEMICAL AND TOXICOLOGICAL STUDIES

(In the event studies are not immediately available, please forward)

YES	NO		YES	NO	
X		TISSUE LACTIC ACID FOR HYPOXIA		X	BLOOD SUGAR
X		BLOOD ALCOHOL	X		TISSUE CARBON MONOXIDE
X		TISSUE ALCOHOL	X		BLOOD CARBON MONOXIDE
		OTHER (Specify)			OTHER (Specify)

50. HISTOLOGICAL

(Attach additional sheets giving microscopic description and summary statement as to cause of death, antecedent causes or other significant conclusions.)

51. PATHOLOGIST PERFORMING GROSS AUTOPSY	52. ADDRESS
/S/ JOHN C. JACKSON, MAJOR, USAF (MC)	ZIPPY AFB, COLORADO
53. PATHOLOGIST PERFORMING MICROSCOPIC STUDY	**54. ADDRESS**
/S/ PETER D. QUERIN, MAJOR, USAF (MC)	ARMED FORCES INSTITUTE OF PATHOLOGY WASHINGTON, D. C. 20306

4

Figure 19 (4).

(6) *Item 25, External Skeletal Examination,* deals with the external examination of the skeletal system. A complete study includes photographs and X-rays. Whenever fractures, lacerations, contusions, etc. are found, efforts should be made to ascertain their cause. Are skull fractures caused by striking against the instrument panel or control stick; are fractures of the extremities due to flailing or striking against specific fixed objects; are lacerations inflicted by hurled objects or by impact with some fixed structure on the aircraft? It is important to state whether lacerations are of the incised or bursting type. Fire alone can produce fractures, especially of the skull bones, and also cause loss of an extremity, which should be differentiated from traumatic amputation.

(7) *Items 26 and 27, Brain and Spinal Cord.* Air in the cerebral vessels is a common postmortem finding when veins in this region have been severed and is not reliable evidence of air embolism. Large hemorrhages may appear to be the result of trauma, but a careful search should be made for cerebral aneurysm, especially about the base of the brain. Fire may cause the blood within the cranial cavity to boil and thus produce false epidural hemorrhage. Lacerations, contusions, and similar lesions should be carefully correlated with other findings. If brain tissue is not available, spinal cord may be submitted in the frozen state for lactic acid determination.

(8) *Items 28 through 32, Sinuses, Glottis, Middle and Inner Ear, Eyes, Oral Cavity,* are concerned with other structures within the head. Examination of the inner ears is most important in the study of spatial disorientation or vertigo, and these structures should be removed and forwarded as gross specimens (see removal of temporal bones, para 50, and fig. 14).

(9) *Items 33 through 36, Larynx, Pleural Space, Trachea, Lungs.* Study of the respiratory tract is the subject of above items. Large quantities of blood in the pleural cavity indicate limited survival after an accident, whereas small quantities suggest postmortem trauma. Examination of the larynx, trachea and bronchial tree may reveal particles of black soot which indicate that the crew member inhaled smoke and thus was alive during the fire. It should be determined whether lacerations of the lung were made by rib fractures (and if so, by what ribs) or are the result of a crushing injury without rib fractures.

(10) *Items 37 through 39, Great Vessels, Pericardium, Heart.* The aorta must be examined for lacerations and ruptures. Lacerations may be caused by a fractured bone or compression against the vertebral column; rupture by sudden deceleration. Such ruptures are characteristically located in the ascending arch of the aorta, just distal to the subclavian artery. The heart should be examined for compression, rupture or lacerations. The compression, or "paper bag," type of rupture results from sudden compression of the chest wall; the laceration by a fractured rib or vertebra. The coronary artery should be sectional at 2 mm. intervals to reveal coronary sclerosis and/or thrombosis. The gross diagnosis of decompression sickness depends upon the demonstration of air embolism. The quantity of liberated gas present at high altitude may be reduced when the body is returned to ground level. The presence of air embolism can be determined only at the beginning of the autopsy. After the skin is reflected from the chest, the costochondral cartilages are severed, and the sternal plate is reflected toward the head. The interior mammary vessels should not be cut. The pericardial sac is incised and the edges lifted with forceps to form a cup into which water is poured to submerge the heart. The first incision is made across the coronary artery and the vessels milked by slight finger pressure. Any bubbles released rise to the surface of the water. The right atrium, right ventricle and pulmonary artery are then incised and gentle pressure is applied to force any trapped air out of the chambers. The left artium and ventricle are examined in the same manner. The presence of gas may be due to: (1) Trauma, (2) Postmortem gaseous decomposition, (3) Gas bacillus infections. With reference to (1), air may be introduced as a result of severance of large venous channels such as the jugular veins, lateral sinuses of the skull, etc., to enter the vascular system under negative pressure. This possibility should be ruled out before a diagnosis of decompression sickness is made. To demonstrate the presence of postmortem gaseous decomposition and gas bacillus infections, blood taken at the time of examination must be cultured. For more details on air embolism, see paragraph 23*c*.

(11) *Items 40 through 48. Peritoneum, Stomach, Intestines, Liver, Other Organs.* Examination of the abdominal organs is covered in items 40 through 47. The cause of any traumatic injuries should be determined. For instance, is a laceration of the liver due to rib fractures or a crushing injury that compresses the liver against the vertebral column, and what was the nature of the external force that caused the injury. Collection and preservation of material varies with the factors to be studied (also see AFR 160-109 for details).

(12) *Items 49 and 50, Biochemical and Toxicological Studies—Histological.* Fresh tissue for *toxicologic* examination (including those from cases of suspected hypoxia and carbon monoxide poisoning), should be collected as soon as possible and frozen (dry ice is recommended). The tissue should never be placed in a fixative. When frozen, it should be packed in plastic

bags (a standard stock item) and shipped in a container which holds sufficient dry ice for a trip by air freight or military aircraft. DD Form 1322 (Aircraft Accident Autopsy Report) should accompany the frozen tissue. Brain or spinal cord for lactic acid studies must be shipped frozen because after death most of the lactic acid will otherwise be converted to pyruvic acid in about 24 hours. Blood, liver, muscle, kidney and lung for such determinations as carbon monoxide, alcohol and drugs, must also be refrigerated. The carbon monoxide with hemoglobin is relatively strong and samples of blood have yielded positive results months after death. Many studies are hampered by the small amounts of tissue submitted for toxicologic examination. A general rule is to forward as much tissue to the Armed Forces Institute of Pathology, Washington, DC 20306, as is practicable. Representative tissues for *histopathologic study* should be taken from all available organs following the autopsy and fixed in 10 percent formalin. The volume of fixative should be 15 to 20 times that of tissue. Once the tissue is fixed, it can be shipped in smaller amounts of formalin. These tissue blocks should include the gross lesions and sections from normal tissues as well. The following materials should be shipped as soon as possible to the Armed Forces Institute of Pathology:

(a) Autopsy report.

(b) Information concerning the circumstances of the accident.

(c) Accident report.

(d) Photographs (accident scene and autopsy).

(e) X-rays.

(f) Frozen tissue for toxicology.

(g) Fixed tissue (representative portions).

(h) Slides.

(i) Blocks.

Shipments should be made by air freight. Notification of flight number, time of arrival, and bill of lading number should be communicated to the Armed Forces Institute of Pathology by the fastest means possible. Telephonic notification at Area Code 202 576-2800 (or Autovon 291-2800) is suitable.

Standard Form 503
Revised August 1954
Bureau of the Budget
Circular A-32 (Rev.)

CLINICAL RECORD	AUTOPSY PROTOCOL			
DATE AND HOUR DIED 29 MARCH 1976 8:26 A. M. P. M.	DATE AND HOUR AUTOPSY PERFORMED 31 MARCH 1976 8:15 A. M. P. M.	CHECK ONE		
		FULL AUTOPSY	HEAD ONLY	TRUNK ONLY
PROSECTOR H. S. TRIPLER, CAPT, MC, USA	ASSISTANT	X		

CLINICAL DIAGNOSES *(Including operations)*

1. MYOCARDITIS OF UNKNOWN CAUSE.
2. HYPOCHLOREMIA AND HYPONATREMIA WITH HYPOVOLEMIA.
3. CARDIAC INSUFFICIENCY, SECONDARY TO DG. 1 AND DG. 2.

PATHOLOGICAL DIAGNOSES

CARDIOVASCULAR SYSTEM:
1. MYOCARDIAL HYPERTROPHY, IDIOPATHIC.
2. INTERSTITIAL FIBROSIS.
3. MYOCARDITIS, FOCAL, CHRONIC, SLIGHT.
4. ATHEROSCLEROSIS, AORTA, MINIMAL.

RESPIRATORY SYSTEM:
1. CHRONIC PASSIVE CONGESTION.
2. PULMONARY EDEMA.
3. ATELECTASIS, PARTIAL, LEFT LUNG.
4. INTERSTITIAL FIBROSIS, LEFT LUNG.

SPLEEN AND HEMATOPOIETIC SYSTEM: CHRONIC PASSIVE CONGESTION.

LIVER:
1. CENTROLOBULAR ANOXIC NECROSIS.
2. CHRONIC PASSIVE CONGESTION.

GALLBLADDER AND BILE DUCTS: NONE.

PANCREAS: CHRONIC PASSIVE CONGESTION.

GASTROINTESTINAL SYSTEM: ACUTE DUODENAL ULCERATION, DUE TO CANDIDA ALBICANS.

GENITOURINARY SYSTEM: NONE.

ENDOCRINE GLANDULAR SYSTEM: NONE.

CENTRAL NERVOUS SYSTEM: NONE.

BONE AND JOINTS: NONE.

MISCELLANEOUS: ASCITES.

APPROVED—SIGNATURE
BURTON C. WALKER, LTC., MC, USA

MILITARY ORGANIZATION (When required)	AGE	SEX	RACE	IDENTIFICATION NO.	AUTOPSY NO.
	43	M	CAU	366-08-0012	A-25-56

PATIENT'S IDENTIFICATION (For typed or written entries give: Name—last, first, middle; grade; date; hospital or medical facility)	REGISTER NO.	WARD NO.
COOK, WYLIE M. LT. WASHINGTON ARMY HOSPITAL, MOUNT VERNON, VIRGINIA	14807	10

AUTOPSY PROTOCOL
Standard Form 503
503-104
8-300-20

Figure 20.

CHAPTER 5
SPECIAL PROCEDURES

Section I. DESCRIPTIVE PROTOCOL

92. General Instructions

a. Describe the body as a whole and each organ, avoiding the use of diagnostic terms. Include weights and measurements where indicated, and describe the shape, color, consistency, and natural surfaces of each organ, also lesions and malposition.

b. To facilitate processing at the Armed Forces Institute of Pathology, Standard Form 503 (Autopsy Protocol) (fig. 20) will be used.

c. A *clinical abstract* obtained from the clinical records or furnished by the clinician, and *clinical diagnoses* should be next in order and completed in the format indicated below. When death occurs outside of a hospital, a statement concerning the circumstances surrounding death should be included in the autopsy protocol in lieu of the clinical abstract. These statements should be furnished by investigating officers as prescribed in applicable regulations of the services concerned. In cases of *death from trauma,* the cause should be stated; e.g., gunshot wound, automobile accident, poison (kind), and the circumstances surrounding the death, such as homicide, suicide, accident, etc. See Medicolegal Autopsy, chapter 6.

CLINICAL ABSTRACT

DATE OF ADMISSION:

COMPLAINTS:

1 ._____

2 ._____

3 ._____

HABITS: Alcohol, tobacco, narcotics, etc.

FAMILY HISTORY: List all information bearing on deaths, illnesses and hereditary tendencies.

PREVIOUS PERSONAL HISTORY: List all service in Army, Navy, or Air Force and duty in tropics.

PRESENT ILLNESS: Onset of present illness with chronologic abstract of illness.

PAST ILLNESSES: Include all illnesses, operations, wounds, venereal infections, and tropical diseases.

PHYSICAL EXAMINATION: Weight, height, temperature, pulse, respiration, and blood pressure. List all positive observations by systems.

LABORATORY AND X-RAY FINDINGS: Include *gross photographs,* and other pertinent materials, such as electrocardiographic interpretations or photographic copies of electrocardiograms, and significant X-ray films, or copies of these.

COURSE IN HOSPITAL: To include major therapeutic measures.

DATE AND HOUR OF DEATH:

CLINICAL DIAGNOSES

These should be listed numerically on Standard Form 503, (Autopsy Protocol) as indicated in figure 20.

93. Gross Examination of Organs

a. Initial Procedure. Examine every organ in the body; collect representative sections of each for histologic studies and include skin, muscle, peripheral nerve, bone and marrow.

(1) **GENERAL:** Approximate height and weight, age, color, sex, condition as to development and nutrition, degree of rigidity, character and distribution of lividity and degree of post-mortem decomposition. Detailed description of exterior, beginning with hair and going to feet, including marks of identification, superficial vessels, lymph nodes, and external genitalia.

(2) **PRIMARY INCISION:** Subcutaneous fat, muscles, peritoneum, omentum, subperitoneal fat, position and relations of abdominal viscera, adhesions, fluid, intra-abdominal and mesenteric lymph nodes; height of diaphragm; pleural fluid; pericardium; thymus.

(3) **ORGANS OF NECK:** Thyroid; parathyroids; larynx; pharynx.

(4) **LUNGS:** Weight, relative size, consistency, pleura; cut surface of each lobe; bronchi; hilum; lymph nodes.

(5) **HEART:** Weight, relative size, configuration, epicardium, myocardium, valve leaflets, endocardium, coronary arteries, circumferential measurements of valve orifices and thickness of ventricular walls.

(6) **AORTA AND VESSELS:** Caliber, patency.

(7) **SPLEEN:** Weight, size, consistency; capsule, cut surface; color, dry or moist, markings; character of pulp.

(8) **LIVER:** Weight, surface, consistency, color and markings of surface and parenchyma.

(9) **GALLBLADDER AND DUCTS:** Contents; mucosa.

(10) **PANCREAS:** Weight, consistency, cut surface.

(11) **ADRENALS:** Size, cut surface.

(12) **GASTROINTESTINAL TRACT:** Esophagus, stomach and its contents; intestines; appendix.

(13) **GENITOURINARY TRACT:** Kidney: Weight, size and consistency; capsule, subcapsular surface, cut surface; cortical markings, width of cortex; pelvis, pelvic fat, ureter; large vessels. Urinary bladder: amount and character of contents; mucosa; wall.

(14) **SEMINAL VESICLES:**

(15) **PROSTATE: or UTERUS, OVARIES AND ADNEXA:**

(16) **TESTICLES:**

(17) **HEAD:** Scalp; calvarium; dura, blood sinuses of dura; leptomeninges, fluid or exudate; base of skull.

(18) **BRAIN:** Weight, convolutions and sulci; cerebral blood vessels; consistency; ventricles.

(19) **CORD:** Dura; exudate; leptomeninges; appearance of cross sections at representative levels.

(20) **TEMPORAL BONE:**

(21) **EAR:**

(22) **SINUSES OF SKULL:**

(23) **EYES:**

(24) **BONE MARROW:** Ribs, sternum, vertebrae, shaft of femur (when there is a hematologic problem).

(25) **LYMPH NODES:** Size, consistency, appearance on cut surface.

(26) **MUSCLES:**

(27) **BONES AND JOINTS:**

(28) **BACTERIOLOGIC EXAMINATIONS:**

(29) **CHEMICAL EXAMINATIONS:**

b. Cause of Death. After completion of the gross autopsy the pathologist should supply the attending physician with the important pathologic diagnoses to aid him in establishing the cause of death. In some cases no anatomical cause of death can be found at autopsy. In some cases subsequent microscopic, chemical and bacteriological examination will change the pathologic diagnosis. Such changes must be reported to the clinician or to the local bureau of vital statistics. In the case of a medicolegal autopsy, the pathologist is responsible for determining the cause of death and uncovering evidence which may be of legal importance. See chapter 6.

94. Microscopic Description of Organs

a. **HEART:** Epicarduim, epicardial fat, endocardium, myocardium, interstitial tissue, valves, vessels.

b. **LUNGS:** Pleura including mesothelium and subpleural fibrous tissue, lobular septa and pulmonary veins, diameter of terminal bronchioles and pulmonary arteries, contents of bronchovascular rays, thickness of alveolar septa and alveolar contents.

c. **LIVER:** Capsule, architecture (including location and degree of fibrosis), changes in liver cells (degeneration, necrosis, storage of normal or abnormal metabolites), changes in biliary system (canaliculi, cholangioles, interlobular ducts), changes in reticuloendothelial cells (Kupffer cells, portal macrophages), changes in vessels

(central veins, portal vein and hepatic artery branches), degree of inflammation in lobules or portal areas and types of inflammatory cells. *Gallbaldder:* mucosa, tunica propria muscularis and serosa.

d. **PANCREAS:** Acinar parenchyma, islets, ducts, vessels.

e. **SPLEEN:** Capsule, malpighian bodies, red pulp, trabecule, vessels.

f. **ADRENALS:** Cortex, medulla, tumors, vessels.

g. **KIDNEYS:** Glomeruli, tubules, interstitial tissue, vessels, pelvic mucosa.

h. **PELVIC ORGANS:**

(1) Bladder: Mucosa, submucosa, muscularis.

(2) Prostrate: Glands, stroma, hyperplasia, inflammation.

(3) Seminal Vesicles: Mucosa, infection, concretions.

(4) Testes: Tubules, basement membrane, atrophy, spermatogenesis.

(5) Uterus: Endometrium, myometrium, tumors, vessels.

(6) Vagina: Mucosa and submucosa.

(7) Ovaries: Stroma, cysts, corpora albicantia and lutea, vessels, follicles, germ cells

i. **LYMPHATIC SYSTEM:** Capsule, architecture, follicles, stroma, pigment, reticulo-histiocystic components.

j. **THYROID:** Acini, stroma, degenerative changes.

k. **BONE MARROW:** Proportion of fat to hematopoietic elements. Normoblasts, myeloid elements, megakaryocytes. Hyperplasia or hypoplasia.

l. **SKELETAL SYSTEM:** Condition of trabecular bone, osteoblastic and osteoclastic activity.

m. **BRAIN:** Meninges, parenchyma, vessels, perivascular infiltrations, ependyma.

95. Final Summary of the Case

No autopsy protocol is complete without a final summary in which the prosector evaluates his findings and correlates them with the clinical history. Such a summary should consist of:

a. An abstract of about 100 words of the pertinent clinical history and of the clinical diagnostic problem. It should not duplicate the detailed clinical abstract which is furnished by the attending physician.

b. A concise statement of the principal gross and microscopic observations at autopsy. This should not be a copy, but an abstract, of the diagnosis sheet.

c. A discussion of the pathogenesis of the illness and the evolution of the structural changes which eventually led to death, based on the autopsy findings and the clinical history.

d. Where applicable, a discussion of the effects of therapy.

e. The prosector should state what he learned from the case or what the case should teach.

Section II. EXAMINATION FOR MICROORGANISMS

96. Postmortem Investigation

An adequate postmortem investigation of the tissues for microorganisms is as important as the morphological study and may yield the only positive proof of the exact nature of a pathological process. The pathologist is responsible for the collection of the material for culture. If a bacteriologist is available, he should collaborate with the pathologist in the selection and collection of material for cultures.

97. What To Culture

If indicated, prepare aerobic and anaerobic cultures of the heat's blood on both solid and liquid media. If the lesions suggest a possible bacterial cause, prepare cultures from other tissues too. If a sulfonamide or antibiotic has been administered, collect specimens for culture in large amounts of media containing 0.1 percent agar to reduce the concentration of the drug; hold the cultures for a least 1 week before reporting them sterile.

98. How to Obtain Material For a Culture

During the course of an autopsy the surface of the organs becomes grossly contaminated. Precautions must be taken to destroy these contaminating organisms and to secure material for culture from the deeper tissues only. Hold a spatula over a gas burner until it is red hot and apply it to the surface of the tissue from which the culture is to be taken. Hold the spatula on the area until the tissue is seared and thoroughly dry. Do not allow the area to become contaminated by contact with surrounding tissue and fluids before the culture is taken.

99. Techniques

There are several techniques for securing material for culture:

a. Heart's Blood. Plunge a pipette (glass tube drawn to a point and sterilized) or a sterile hypodermic needle (18 to 20 gauge, 3 in.) attached to a 20 ml sterile syringe, through a seared area on the wall of the atrium or ventricle

and draw the blood by suction. If the heart has already been removed from the body, blood sometimes can be obtained from the femoral vein, portal vein, or vena cava.

b. Solid Viscera. With a sterile, sharp instrument break the surface in a seared, dry area and plunge a sterile applicator stick, with its end lightly covered with cotton, into the substance of the organ. Withdraw the stick and replace in the sterile test tube, but do not allow the portion of the applicator held by the fingers to enter the tube. A small amount of sterile broth or normal saline solution must be in contact with the swab in the test tube, otherwise the culture will soon dry and be worthless. If actual tissue is desired, remove a block of about 1 ml with sterile forceps and scissors from beneath the seared surface. Place the block in a sterile container and later grind it in mortar with sterile broth. Use the suspension to inoculate appropriate media.

c. Leptomeninges. If the dura is intact after removal of the calvarium, it may be reflected form the cerebral hemisphere and cultures of the leptomeninges taken with a swab or pipette without searing of the surface. Otherwise, the leptomeninges must be seared with the heated spatula, which may kill the organisms immediately beneath it. To obtain viable organisms the swab or pipette should be inserted through the seared area and directed through the subarachnoidal space into an adjacent unheated, uncontaminated region.

d. Deep Freezing for Subsequent Cultures. Representative fresh tissues frozen at the time of necropsy may prove essential to diagnosis in the event that histologic study indicates a need for cultures.

Special Cultures. Many microorganisms grow poorly or not at all on routine culture media, therefore, the bacteriologist should be given full information concerning the exact nature of the disease and the character of the lesions, in order that he may do intelligent and accurate work. The more important diseases requiring special conditions for cultivation and isolation of the microorganism are tuberculosis, tularemia, brucellosis, pertussis, gonorrhea, and influenza. For preservation of material form spirochetal diseases, draw blood or tissue fluid into capillary tubes, 8 to 10 cm in length. Seal the ends of these tubes by melting the glass in a flame. The *Treponema pallidum* may remain active for as long as 48 hours under these conditions.

100. Study of Fungi

a. Direct microscopic examination of pus, other fluid, or material form ulcers should be examined without staining by placing a drop on a slide and pressing it gently under a cover glass to make a thin smear. If necessary, the material may be cleared by placing it in a drop of 10 percent potassium hydroxide on a slide, covering with a glass slip and gently warming the slide.

b. Spinal fluid should be examined in the same way as pus, except that it should be centrifuged and the sediment examined directly. When cryptococcosis is suspected, place a drop of sediment in a drop of India ink on a slide, cover with cover slip.

c. All materials from cases of suspected myotic infection should be *cultured* for fungi regardless of whether fungus cells are found on direct examination. As a routine procedure, it is suggested that blood agar plates be streaked, and Sabouraud's glucose agar slants inoculated, with material obtained from lesions. The blood agar plates should be incubated at 37° C. and the Sabouraud's slants kept at room temperature.

101. Smears

Direct examination of smears stained for bacteria may yield valuable information. In many protozoal diseases, thick films of blood or tissue fluid should be prepared. Touch a clean slide to a drop of blood or tissue pulp and allow it to spread over an area about 1 cm in diameter. Dry at 37° C. for one hour, or in a horizontal position at room temperature overnight in a dust-free atmosphere. Such smears should be stained with Giemsa stain within 48 hours, because they deteriorate on standing.

102. Disposition of Cultures

If a skilled bateriologist is not available locally, send the material collected at autopsy immediately to a bacteriological laboratory. Attach a short note containing information that will serve as a guide in the selection of culture media and conditions of incubation. In smaller laboratories the pathologist may carry out the simpler isolations and identifications, but material from all important and doubtful cases should be sent to a laboratory equipped for bacteriological examinations. If the pathologist or clinician knows that a patient with an unusual bacterial disease is on the wards of the hospital, he should consult with a bacteriologist in order to anticipate what autopsy material will be required to establish the diagnosis. If facilities for bacteriological studies are not available, the blood and tissues collected at autopsy should be placed in sterile vessels, frozen with dry ice, and shipped to a bacteriological laboratory. Pertinent data should be sent with the specimens.

103. Handling and Shipping Instructions

Information concerning the handling and shipping of specimens for examination for microorganisms may be obtained from area laboratories, TM 8-340/NAVMED P-5083/AFM 160-28/VA IB 11-13, "Methods of Preparing Pathologic Specimens for Storage and Shipment": AE 40-31/BUMEDINST 6510.2E/AFR 160-55, "The Armed Forces Institute of Pathology and Armed Forces Histopathology Centers"; and AFM 160-52, "Laboratory Procedures in Clinical Bacteriology."

Section III. SPECIAL STUDIES OF VIRAL DISEASES

104. Suspected Viral Diseases

a. In any case of suspected viral disease, steps should be taken to identify the typical histological changes in the tissue and to isolate the virus.

b. For cytological studies fix representative blocks of tissue in Bouin's fluid or Zenker's fluid and cut in the usual way. For the isolation of the virus, not less than 10 gm of fresh tissue should be removed with sterile precautions from the lesions.

c. In view of the opportunities provided for diagnosis by means of tissue culture, submit fresh frozen tissues for isolation viruses. Samples of fluids such as whole blood, respiratory tract-exudate, or intestinal content should be frozen separately. Each specimen of fresh tissue or fluid should be placed in a *separate* sterile, airtight container of glass, metal, or plastic and sealed to prevent the entrance of carbon dioxide. The acidity of absorbed carbon dioxide is detrimental to many virsuses and may inactivate them. If possible, the material should be quick-frozen in dry ice, but it can be preserved in 20 volumes of 50 percent buffered glycerol for each volume of tissue.

d. Directions for the preparation of *sterile buffered glycerol* are:

(1) Citric acid 21 gm. to 1,000 ml double distilled water.

(2) Anhydrous Na_2HPO4 28.4 gm to 1,000 ml double distilled water.

(3) Take 9.15 ml of (1) above and 90.85 of (2) above to make 100 ml of buffer solution pH 7.4.

(4) Mix equal parts of (3) above and C.P. glycerol; fill cork-stoppered specimen bottles half full and sterilize at 15 lb. of steam pressure for 30 minutes.

e. If buffered glycerol is not available, sterilize a solution containing 50 percent glycerol and 0.9 percent sodium chloride. If dry ice is available, place each 10 gm sample of tissue in a separate sterile test tube or glass bottle and keep frozen.

f. In viral diseases of the central nervous system it is desirable to have blocks of fresh tissue, about 10 gm each, from the following 9 regions:

(1) Temporal lobe, including the hippocampus.

(2) Motor cortex.

(3) Olfactory bulbs.

(4) Midbrain.

(5) Thalamus.

(6) Pons and medulla.

(7) Cerebellum.

(8) Cervical cord.

(9) Spinal cord as indicated.

g. Blocks of tissue immediately adjacent to the tissue removed for viral studies should be fixed in Zenker's or Bouin's fluid for microscopic study. Blocks should not exceed 2 mm in thickness. Specimens from cases of rickettsial disease should be fixed in Regaud's fluid.

h. At autopsy, obtain enough blood aseptically to provide approximately 10 ml of serum. The blood should be refrigerated immediately, the serum separated as soon as possible and stored without preservative in a tightly stoppered sterile tube. The tube should be labeled with the patient's name, autopsy number or other identification and the date of collection. It should be refrigerated or frozen and submitted with the tissue for virus isolation, together with any serum previously obtained from the patient. The serum may be used to obtain a disgnosis by serological means in the event that a virus is not isolated.

105. The Collection and Handling of Brain Tissue at Autopsy for the Diagnosis of Rabies

a. A face shield or goggles and rubber gloves to protect the prosector are essential during the exposure and removal of the brain. Take 1 gm blocks of tissue aseptically from the hippocampus, cerebellar cortex, medulla, pons, thalamus, and cerebral cortex of one cerebral hemisphere and pool for virus isolation. If virus isolation is to be attempted on the same day, refrigeration is adequate; if not, freeze the pooled tissue.

b. Take from the opposite cerebral hemisphere approximately 1 gm blocks of tissue from the hippocampus, cortex of the cerebellum, and the frontal and parietal lobe of the cerebrum. Fix one-half of each block in

Zenker's fluid. Make impressions from the other half of the blocks by pressing slides on the cut surface, and stain while still *moist* with Seller's stain. If the impressions cannot be stained at once they may be fixed while still *moist* for two minutes in absolute C.P. methyl alcohol.

106. Technique for Negri Bodies in Impressions

a. Seller's Stain. Immerse slides while the impression is moist in Seller's stain for 1 to 5 seconds depending on thickness of impression. Rinse gently under running tap water, and airdry (do not blot). Examine thin areas with the oil-immersion lens. Negri bodies stain bright cherry red. They are round or oval bodies up to 23 microns in diameter, in which vacuoles containing basophilic granules usually can be demonstrated. Cytoplasm of nerve cells stains purplish-blue, nuclei and nucleoli deep blue, and stroma pink. The formula for Seller's stain is:

(1) Stock Solution A. Dissolve 1 gm of basic fuchin in 100 ml of absolute, acetone-free C. P. methyl alcohol.

(2) Stock Solution B. Dissolve 1 gm of methylene blue in 100 ml of absoulte, acetone-free C. P. methly alcohol.

(3) Store both solutions in glass-stoppered bottles.

b. Working Stain. Take one part of Stock Solution A (basic fuchsin) and mix with two parts of Stock Solution B (methylene blue). Mix but do not filter.

107. Technique for Negri Bodies in Smears

a. With a small scissors cut through Ammon's horn (hippocampus). Clip a piece from the cut surface no larger than a grain of rice (a portion of the hippocampus previously removed may be used). Also use a piece of tissue from the cerebellar cortex.

b. Transfer tissue to a clean slide near one end. Press this out flat by means of another slide. Draw the top slide along the length of the bottom one, leaving a thin smear.

c. Stain with Seller's stain by the same technic as described for impressions. *It must be stained before it dries.* If staining cannot be done immediately, fix for 2 minutes while the smear is still moist in absolute C. P. methyl alcohol.

108. Technique for Negri Bodies Zenker Fixed Tissue (Schleifstein's Stain)[1,2]

a. Wash Zenker-fixed tissue for 24 hours in running tap water. Embed in paraffin and cut sections at 6 microns.

b. Solutions:

STOCK SCHLEIFSTEIN'S STAIN

Solution A

Basic fuchsin	1.8 gm
Methylene blue	1.0 gm
Glycerin	100.0 ml
Methyl alcohol	100.0 ml

This solution will keep indefinitely.

[1] Schleifstein, J.: *Am. J. Public Health.* 27:1283-1285, 1937.
[2] Luna, L.G. (Ed): *Manual of Histologic Staining Methods of the Armed Forces Institute of Pathology.* Third Edition. McGraw-Hill Book Co., New York, 1968.

Solution B

Potassium hydroxide, 1:40,000 aqueous solution, or tap water which is slightly alkaline.

Working Schleifstein's Solution

Solution A	10 drops
Solution B	20 ml

Mix the working solution in a small vial immediately before use.

5% IODINE SOLUTION

Iodine	5.0 gm
Alcohol, 70%	100.0 ml

5% SODIUM THIOSULFATE (HYPO) SOLUTION

Sodium thiosulfate	5.0 gm
Distilled or tap water	100.0 ml

c. Staining Procedure:

(1) Deparaffinize sections in usual manner. Run through absolute and 95 percent alcohols to distilled water.

(2) Remove mercury precipitates in 5 percent iodine solution for 5 to 10 minutes.

(3) Rinse in running tap water for 2 minutes.

(4) Clear in 5 percent soduim thiosulfate solution for 5 to 10 minutes.

(5) Wash in running tap water for 10 minutes, rinse in distilled water.

(6) Place sections on warm electric hot plate, flood with freshly prepared Schleifstein's solution, and steam gently for 5 minutes.

(7) Cool and wash quickly in tap water.

(8) Decolorize and differentiate each slide individually by gently agitating in 90 percent alcohol until sections are faint violet color.

(9) Dehydrate with 2 changes of 95 percent alcohol, clear with xylene, and mount in Permount.

d. Results:

(1) *Negri bodies*—deep magenta.

(2) *Cytoplasm*—bluish violet.

(3) *Erythrocytes*—copper.

Section IV. IMMUNOLOGICAL EXAMINATION

109. Relation of Virus to Disease

The isolation of a specific bacterium or virus from the tissues does not prove that it is the cause of the disease from which the individual died. The bacterium may be a contaminant or a secondary invader. A virus found after animal passage may be virus indigenous to the animal used for experimental inoculation. Proof of the relation of a bacterium or virus to the disease may be obtained by the demonstration of immune bodies in the serum. In all autopsies on patients suspected or known to have died of a bacterial or viral disease, 25 ml of blood should be removed under sterile conditions from the heart and placed in sterile centrifuge tubes.

110. Preservation of Serum

Immediately on completion of the autopsy, the sample of blood should be centrifuged, the serum removed with sterile pipettes and kept in sterile tubes in the refrigerator. If possible, tubes of serum without preservative should be held and shipped frozen in dry ice. An alternative is to hold the serum samples under refrigeration and ship via air mail. Preservatives are not recommended because they interfere with neutralization tests. When neutralization tests are not indicated and delivery to the laboratory may be delayed, 0.3 percent cresol may be added as a preservative.

SECTION V. RADIOACTIVE CADAVERS AND SPECIMENS

111. Precautions in Handling

a. Every institution that employs radioisotopes in diagnosis or therapy should have available for consultation a radiological safety officer. It is the responsibility of this officer to provide advice and the necessary radiation monitoring to insure the safety of those personnel who may be exposed to ionizing radiations.

b. With the ever increasing application of high levels of radioactivity in diverse fields of nuclear energy production, industry, scientific research and medicine, there is the remote but proportionately increasing possibility of fatalities occurring either directly in consequence of radiation exposure or with radioactive contamination, internal or external, as an incidental factor. Whereas those bodies that had received carefully measured and documented radioactive substances as a therapeutic effort have more or less predictable radioisotope burdens often with specific visceral localization and calculable radioactive decay patterns, those victims of accidents where radioactive isotopes may be an etiologic factor or an incidental contaminant are frequently of indeterminate nature and quantity. In most instances the body radioactivity will be largely in the form of surface contamination and provision is to be made for a complete body scrub down. This decontamination is best accomplished under the direct supervision of the radiological safety officer. The wash and rinse waters used in this procedure are to be handled and disposed of in the same manner as other radioactive wastes and in compliance with established regulations. Every effort should be made to identify the radioactive contaminants and determine levels of activity before the autopsy is begun.

c. The bodies of patients who died following therapeutic administration of radioisotopes may also constitute a potential hazard to morgue attendants and those individuals performing the autopsy. It is the responsibility of the physician who transfers the body to the morgue to see to it that the body is properly identified, carefully monitored, and labelled with a radioactivity precautions tag indicating type and quantity of radioisotope and time of administration, radiation level at the time of monitoring, and the decay rate of the isotope used.

d. The pathologist should not perform an autopsy on a radioactive body without consultation with the radiological safety officer, and this officer or his qualified designated representative should be present at the autopsy to monitor the opened cadaver as well as the removed viscera. When there is a potentially significant health hazard to the morgue personnel, caution and prudence must override any impulse or pressure to proceed with the autopsy. There is never any reason for needlessly exposing the prosector or his staff to potentially harmful radiation levels. Intense radioactivity may predicate a delay in beginning the autopsy, in which case the body must be stored in a secured area. Radioactive decay is essentially exponential and a judicious postponement of several hours may suffice to significantly reduce the radioactivity of short-lived isotopes. Since dosage is determined not only by the radiation level but also by the duration of exposure, the pathologist may limit the dosage to himself by increasing the speed of the postmortem examination or by alternating with another pathologist. It is advisable to remove the principal focus of radioactivity (fluid and/or tissue) as soon as possible transferring it to a safe container with minimal spillage.

e. According to the National Council on Radiaton Protection and measurements, the maximum permissible yearly dose is 5.0 rems to the whole body, and five times as much to the hands and forearms. Every reasonable effort should be made to keep well below these prescribed levels.

f. The clothing and exposed skin surfaces of the pathologist and assistants must be protected from contamination by radioactive materials. A long, heavy, rubber apron should be worn beneath the usual cotton operating gown. Fluids which may contaminate the gown will be absorbed by the cloth rather than reach the trousers and shoes. High rubber boots or disposable plastic shoe covers can be worn during particularly hazardous autopsies. Close contact with radioactive foci emitting the more penetrating beta radiations is a major concern. For this reason the hands, wrists, and forearms should be protected by long, double, heavy rubber gloves. The face should not be allowed to come close to radioactive foci in the examination of body cavities or organs. If this precaution is observed, the face need not be protected by a mask. However, body fluids which may inadvertently splash the face should be washed off immediately with several rinses of tap water. It is especially important to protect the eyes with spectacles or goggles.

112. Handling, Disposition, and Storage of Radioactive Material

a. Radioactive organs and body fluids should be either stored or discarded expeditiously under the direction of the radiological safety officer. In some cases, blood, urine, and serous fluids may be drained directly into the sewer system if authorized by the radiological safety officer. Otherwise, these fluids as well as organs and radioactive tissue specimens must be stored in thick-walled containers bearing radioactivity warning labels listing their levels of radioactivity and safe time for disposition. During the period of significant radioactivity, the containers should be stored in a specified safe location.

b. Foci of intense radiation should not be handled directly. Forceps, at least 10 cm in length, and a long knife are used to manipulate or resect organs and to remove sectioned pieces of organs. Drainage tubes and trochars are held with forceps during the withdrawal of radioactive blood and body fluids.

c. After the organs, tissues, and fluids of greatest radioactivity have been removed, additional monitoring of the body by the radiological safety officer will indicate what further precautions are needed in completing the autopsy. If the level of radiation is not greater than 30 mr/hr measured 1 cm from the tissues, the gloves and clothing previously described will be adequate protection and the tissues can be handled directly. The radioactivity in any given localized area will depend on the time elapsed since administration of the isotope. As examples, the decay rate of Au^{198} is about 25 percent per day and that of I^{131} is roughly 9 percent per day. The probable radioactive content of the body at certain times after various doses can be ascertained from the radiological safety officer or from chart 1.

d. After completion of the autopsy, the cleaning of the autopsy room and disposition of instruments, gloves and other material should be surpervised by the pathologist and the radiological safety officer. The body should be tagged with a radioactivity precautions label indicating to the mortician the presence of radioactive material, dosage, radiation level at time monitored, and the decay rate of the radioisotope used.

Chart 1. Probable radioactive content of body at various times after various doses

A guide for autopsy consideration. For values *in italics*, no precautions are necessary except wearing surgical rubber gloves. For values *not* in italics, consultation with radiological safety officer is indicated.

Dose of isotope	Days elapsed since treatment							
	1	2	3	4	6	8	10	15
Au^{198}	Gold remaining in injected cavity							
mC	*mC*	*mC*	*mC*	*mC*	*mC*	*mC*	*mC*	*mC*
150	115	90	69	52	32	20	12	*3*
125	96	75	58	44	27	16	10	*3*
100	77	60	46	35	21	13	8	*2*
75	58	45	35	26	16	10	6	*2*
50	38	30	23	18	11	7	*4*	*1*
40	31	24	18	14	9	5	*3*	*1*
30	23	18	14	10	6	*4*	*2*	*1*
I^{131}	Iodine remaining in thyroid gland following dose for ablation of normal thyroid tissue							
60	18	16	14	12	10	8	6	*4*
50	15	13	12	11	9	7	5	*3*
40	12	10	9	8	7	5	*4*	*2*
30	9	8	7	6	5	*4*	*3*	*2*
20	6	5	5	*4*	*4*	*3*	*2*	*1*
10	*3*	*3*	*2*	*2*	*2*	*1*	*1*	*1*
I^{131}	Iodine remaining in functioning metastases following therapeutic dose post-thyroidectomy. (There are maximal; usually much smaller)							
100	20	18	16	14	12	9	7	*4*
75	15	13	12	11	9	7	5	*3*
50	10	9	8	7	6	5	*4*	*2*
35	7	6	5	5	*4*	*3*	*2*	*1*
20	*4*	*4*	*3*	*3*	*2*	*2*	*1*	*1*

Section VI. COLLECTION AND SHIPMENT OF SPECIMENS FOR TOXICOLOGICAL EXAMINATION

113. Preservation and Shipment of Specimens and Continuity of Custody of Evidence.

a. One copy of the DD Form 1323 toxicology form (fig. 21) and a copy of the completed Gross Autopsy Protocol should be forwarded with the material for toxicology studies. All suspected intoxicants, toxic agents, or drugs should be clearly indicated. Immediate collection and refrigeration is essential. Embalming fluids or formaldehyde fixation of specimens invalidate most toxicology studies. Specimens, except those from aircraft accidents, should be sent to the toxicology laboratory designated to do the work for that military or Federal service. For directions concerning shipment of specimens from aircraft accident fatalities see paragraph 114.

b. Tissue specimens for toxicological examination should be collected under the sepervision of the pathologist performing the autopsy and will consist, whenever possible, of the following: Liver, brain, kidney, lung, blood, urine, and stomach contents. (Precautions should be taken to prevent contamination of the specimen during the course of the autopsy.) Toxicological examination requires approximately 250 to 500 grams of brain, liver, kidney, and lung, 20 ml of blood, and all urine available. The amount of tissue available will govern the amounts submitted. Individual tissue specimens, that is brain, liver, etc. should be placed in separate plastic bags. Blood and body fluids can be shipped in clean plastic bottles or plastic, leakproof bags. As an added precaution, the plastic bottle should be inclosed in a plastic bag. It is recommended that heavy polyethylene plastic bags (.005 or .006 gauge) be used as individual specimen containers. The specimen should be placed in the plastic bag, as much air as possible evacuated from the bag, and the bag then heat-sealed, knotted, or securely fastened with a rubber band. As an added precaution, the tissue should be enclosed in a second bag in which a tag with all identifying data should be placed; e.g., identification of contents, weight or volume, name or individual, and date material was obtained. It is recommended that a paper label only be used in identifying frozen specimens, since plastic labels may cause camphor odors to permeate the specimens and give false determinations. Heat-seal or fasten the second bag, as indicated above, and prepare for shipment. (Formalin fixed tissue for histopathology should not be packed with the frozen tissue for toxicology). Specimens from cases which have legal implications should be sealed and packaged before certifying witnesses. Mark each container so that it can be identified in court as the individual work of the person who collected the specimen. Keep all specimens so prepared safely locked until they are shipped or otherwise delivered to the toxicologist.

c. It is imperative that frozen specimens and dry ice are not packaged in sealed cans or any container which will not permit gas to escape through vents or the walls. Gas pressure within a sealed container presents a great potential hazard and could cause the container to burst. Do not inclose dry ice in a thermos bottle. When packing for shipment, the specimen and the autopsy protocol should be placed in a stout cardboard box filled with pieces of dry ice and enough filler (sawdust, styrofoam, etc.) to fill and insulate the box. The box should be large enough to hold 8 to 10 pounds of dry ice for a shipping time of 24 to 36 hours, and should be sealed with tape, then wrapped in several layers of heavy paper. A plastic-insulated box is available on the Federal supply schedule; its nomenclature is "Box, Plastic, Insulated; Meat, Dairy Products, and Laboratory Samples." The specimens should be shipped by air freight to the appropriate toxicology laboratory.

114. Shipment of Specimens from Aircraft Accidents

a. In cases of Aircraft Accident Fatalities, toxicological studies are performed at the Armed Forces Institute of Pathology in accordance with AR 40-21, BUMEDINST 6510.6A, AFR 160-109 and TM 8-340/NAVMED P-5083/AFM 160-28/VA IB 11-13." Although the presence of toxic substances may not be immediately suspected in aircraft accident victims, tissue should be forwarded to the AFIP for examination. Prompt collection of fresh tissue is essential, and it is imperative that no fixative come in contact with tissues for toxicological analysis. Freezing (dry ice) is the prescribed method of preservation and the specimens should be packed as prescribed in paragraph 113.

b. Each specimen continer should be labeled "FRAGILE—RUSH—SPECIMENS FOR TOXICOLOGICAL EXAMINATION (AIRCRAFT ACCIDENT)" and forwarded by air freight to The Director, Armed Forces Institute of Pathology, Washington, DC 20306. Notification of flight number, time of arrival, and bill of lading number should be communicated to the Armed Forces Institute of Pathology by the fastest means possible. Telephonic notification at Area Code 202 576-2800 (Autovon 291-2800) is suggested.

TOXICOLOGICAL EXAMINATION - REQUEST AND REPORT

(Submit in Triplicate)

TO: US Army Medical Laboratory
Dept. of Pathology (WRAMC)
ATTN: Toxicology Laboratory
Ft. Meade, MD 20755

FROM: Laboratory Service
Womack Army Hospital
Ft. Bragg, NC 28307

SECTION A - MEDICAL REPORT

(If examining physician is other than recording authority, his signature must appear on this medical report)

1. NAME OF PATIENT (Last, first, middle initial)	2. SERVICE NUMBER	3. AGE	4. SEX	5. RACE
Anderson, Phillip P. A/2c	866-23-0101	18	M	Cau

EXAMINATION

6. HOUR	7. PLACE	8. DATE	9. TIME & DATE OF DEATH
1000	Laboratory Service, Womack Army Hospital	5 July 1976	0400 hrs, 5 Jul 76

RECENT MEDICATION

10. PRESCRIBED OR ADMINISTERED
Thorazine

11. IN POSSESSION OF PATIENT
None

12. CONTAINERS FOUND IN PROXIMITY OF PATIENT
1 pint bottle gin, partly empty, in rear seat area of car

SPECIMEN COLLECTION — 13. HOUR AND DATE: 1200, 5 Jul 76

SPECIMEN	AMOUNT	PRESERVATIVE (Freezing preferred)
14. Blood	20 ml	Freezing
15. Urine	50 ml	Freezing
16. Bile	5 ml	Freezing
17. Liver	500 gm	Freezing
18. Kidney	150 gm	Freezing
19. Brain	500 gm	Freezing
20. Gastric contents	250 ml	Freezing
21.		

22. SUMMARY OF EXAMINATION AND/OR AUTOPSY *(Include clinical history, any routine or special laboratory tests performed, and other pertinent information which may suggest drug or poison ingestion)*

Airman found dead in front seat of his automobile on isolated secondary road. Windows of vehicle were partly closed. No external evidence of injury. Autopsy showed no specific cause of death on gross examination. There is a history of deceased being on Thorazine medication for nervousness. Urine examination was negative for sugar and + for alcohol by qualitative study. Request analysis for CO, alcohols, Thorazine.

23. DATE	24. NAME AND TITLE OF REQUESTER	25. SIGNATURE
5 July 1976	JOHN P. DOE, Capt, MC, Pathologist	/s/ John P. Doe

DD FORM 1 JUN 60 1323

Figure 21 (1).

SECTION B - CHAIN OF CUSTODY

(Each individual charged with custody of specimen must complete information below)

SIGNATURE	ORGANIZATION	HOUR	DATE	CONDITION OF SPECIMEN
26. Henry Smith	Laboratory Service Womack Army Hospital	1215	5 Jul 76	Frozen
27. Joseph Jackson	Toxicology Laboratory Ft. Meade, MD	1500	6 Jul 76	Frozen
28. L. Henninger	Toxicology Laboratory Ft. Meade, MD	0800	7 Jul 76	Frozen
29.				
30.				

SECTION C - TOXICOLOGY REPORT

31. LABORATORY	32. DATE	33. CASE NUMBER
Toxicology Laboratory, Ft. Meade, MD	7 Jul 1976	1086

LABORATORY ANALYSES	
34. GASES Hydrogen Cyanide; Carbon Monoxide	Blood CO - % Saturation - Less 10%
35. VOLATILES Cyanide; Ether; Ethanol; Acetaldehyde; Methanol; Formaldehyde; Chloral Hydrate; Chloroform; Phenols and Cresols; Methyl Salicylate; Common Aromatic Hydrocarbons, (e.g. Benzene, Aniline, etc.)	Ethanol - Blood - 400 mg/dl Methanol - None found in blood.
36. ACIDIC COMPOUNDS Barbiturates; Salicylates; Dicoumarol; Acetanilid; Phenacitin; Antipyrine; Tri- and Di-Hydric Phenols; Theophylline; Caffeine	Blood Barbiturate - None found.
37. BASIC COMPOUNDS Alkaloids, Amphoteric Alkaloids, (i.e. Morphine and Morphine Derivatives); Antihistaminics; Tranquilizers	Chlorpromazine - 25 micrograms/dl blood No opiates found in blood, bile or liver.
38. METALS AND METALLOIDS Antimony; Lead; Mercury; Silver; Bismuth; Arsenic	
39. CORROSIVES Sulfuric; Hydrochloric and Nitric Acids Sodium and Potassium Hydroxides and Carbonates	
40. INORGANIC NONMETALLIC COMPOUNDS Bromides, Fluorides, Borates	
41. SPECIAL ANALYSES Any analyses not included above which are specifically requested or warranted by case history	

42. REMARKS

Chlorpromazine (Thorazine) concentration is compatible with a therapeutic level.

43. DATE COMPLETED	44. TOXICOLOGIST	45. OFFICER-IN-CHARGE
7 Jul 76	/s/ L. Henninger	/s/ F. E. Shideman, Major, MC

Figure 21 (2).

Section VII. CYTOGENETIC ANALYSIS

115. Indications

Most developmental anomalies associated with chromosomal abnormalities are noticeable at birth. Few, if any, become apparent after birth. Studies should be done on newborns with two field areas or system anomalies such as mid-face plus cardio-vascular, except where it is obviously not a chromosomal abnormality, such as conjoined twins or syringomyelia. There are a few single developmental field defects associated with minor chromosomal abnormalities, such as severe microcephaly, but these are unusual. Ambiguity of sexual development also warrants investigation.

116. Procedures

a. General. Three types of tissue can be obtained for cytogenetic analysis; peripheral blood, bone marrow and solid tissue, primarily connective tissue. To be evaluated, the cells must initiate division, therefore, they must be alive and capable of undergoing division.

b. Peripheral Blood. Peripheral blood obtained by cardiac aspiration under sterile conditions is usually satisfactory for culture, if obtained within a few hours post mortem, and as long as 12 hours post mortem if the body has been refrigerated (uncoagulated blood is needed). Longer delays are frequently unsuccessful due to the death of the lymphocytes or to bacterial growth in the circulatory system. The blood should be treated according to the chromosome culture techniques prescribed by the laboratory or the culture kit; i.e., placed into aqueous heparin solution to allow separation of the RBC for the macro technique or directly into the culture tubes for the micro technique. If culture media is not available, use approximately 1,000 U. of aqueous heparin per 5 ml whole blood and mix well. Heparinized blood can be kept refrigerated for more than 24 hours with fair success of culture. Do not use lithium heparin or heparin with alcohol or formaldehyde.

c. Bone Marrow. Bone marrow aspirate from the proximal tibia of newborns and infants can be treated like adult bone marrow aspirates and examined at two to four hours after aspiration. The same technique as for the Philadelphia chromosome should be used.

d. Solid Tissue. Primary tissue cultures are more difficult to establish, take weeks to grow and require more care than the other methods, but have been successful using connective tissue obtained 2 or more days post mortem. The optimal tissues are fascia biopsies or fetal tissue removed under sterile conditions. Only a few millimeters of tissue are necessary. Separate the dermis and epidermis from the fascia before the biopsy of the fascia is attempted. The biopsy should be placed in culture media or a balanced salt solution until the tissue culture can be set up.

e. Sex Chromatin. X chromatin can be analysed in preparations of smooth muscle or hair roots using standard or special stains. Y chromatin can be analysed in touch preparations, frozen sections or peripheral blood smears. Fixed tissues can not be used for Y chromatin analysis.

Section VIII. FIXATION OF TISSUE FOR ELECTRON MICROSCOPY

117. Selection of Tissue

Tissue to be used for Electron Microscopic study should be treated as follows:

a. Place tissue in a fixative especially prepared for electron microscopic study, or

b. Use a dual purpose fixative, which can preserve tissue for both light and electron michoscopy.

c. Small (30 ml) bottles of fixative should be stored in the refrigerator for easy retrieval.

d. The tissue should be cut into cubes 1 mm in thickness to allow for rapid penetration of fixative.

e. Specimen should be obtained with an absolute minimum of postmortem change.

f. Tissue to be used for electron microscopy, should be obtained from the original free surface exposed to the fixative.

118. Fixation

a. McDowell and Trump's Formaldehyde-Glutaraldehyde in modified Millonig's buffer.[1] This fixative is excellent for both light and electron microscopy. Fine structural perservation has been obtained in human and rat kidney, liver, pancreas, brain, heart, bronchus, lung and neoplasms. This fixative remains stable for at least 3 months if stored at 4°C. Paraffin blocks can be deparaffinized to give good information for fine structure.

b. Zamboni's Paraformaldehyde (PAF). This fixative is excellent for clarity and sharpness in electron

[1] McDowell, E. M. and Trump, B. F.: Histologic Fixative Suitable for Diagnostic Light and Electron Microscopy. *Arch. Path. Lab. Med.* 100: 405-414, 1976.

microscopy. It is stable, not light sensitive, has a long shelf life and may be used without post-osmication.

119. Formulae for Fixatives

a. McDowell and Trump's Formaldehyde-Glutaraldehyde in modified Millonig's buffer. Add 1.16 gm sodium dihydrogen phosphate monohydrate ($NaH_2PO_4 H_2O$) and 0.27 gm sodium hydroxide (NaOH) to 88 ml water. The add 10 ml formaldehyde (38–40%) and 2 ml 50% glutaraldehyde. The final pH should be 7.2.

b. Zamboni's Paraformaldehyde. To dissociate paraformaldehyde into formaldehyde heat 20 gm of paraformaldehyde and 150 ml of double filtered, saturated aqueous solution of picric acid. Add drops of 2.52 percent NaOH (in water) to alkalize (solution clear). Filter solution and allow it to cool. Make up to 1 liter with phosphate buffer (3.31 gm $NaH_2PO_4H_2O$, 33.77 gm $Na_2HPO_47H_2O$, and 17.88 gm Na_2HPO_4-anhydrous, dissolved in 1 liter of water). This fixative should have a final pH of 7.3, and an osmolarity of 900 milliosmoles.

Section IX. POSTMORTEM CHEMISTRY

120. Use

Postmortem chemistry values have been found to be of use in such situations as establishing a cause of death when no anatomic cause of death is found, further evaluation of anatomic lesions found, and showing possible chemical abnormalities responsible for death when no autopsy is performed. Because of the wide use of automation in the hospital chemistry laboratory, many pathologists perform routine postmortem chemistries on body fluids. The body fluids usually used are blood and vitreous humor. In this section only a brief discussion of blood and vitreous humor postmortem chemistries will be given; for a detailed discussion of this important topic, including cerebrospinal fluid, the following reference is suggested: Coe, J. I., Postmortem Chemistry: Practical Considerations and a Review of the Literature, *Journal of Forensic Sciences* 19:13-32, 1974.

121. Blood Postmortem Chemistries

a. Blood should be removed from the body as soon after death as possible, and the serum separated from the cells. The blood should be removed from the right atrium of the heart, and ideally a sample should also be removed from a peripheral vein, such as the external iliac.

b. Glucose—It has been found in general that blood glucose decreases due to glycolysis except in hepatic veins, the inferior vena cava and the right side of the heart where it can be increased due to the hepatic glycogenolysis. It is therefore difficult to interpret a low blood postmortem glucose, but increased values can be of some use using certain guide lines. Nondiabetic conditions associated with significant postmortem elevations of glucose include carbon monoxide poisoning, increased intracranial pressure and obstruction of the upper respiratory tract. Antemortem diabetic hyperglycemia may be diagnosed from postmortem serum values when it is known that the blood examined is from a peripheral vessel, that the postmortem interval is short, that the deceased did not die from any condition that might have produced a terminal rise in glucose, and that the glucose values exceed 500 ml/dl. Confidence in the significance of the elevated serum glucose is enhanced by the demonstration of glucose in urine and/or the demonstration of ketone bodies in blood or other body fluids.

c. Blood Urea Nitrogen—Urea nitrogen values in the postmortem serum closely approximates those in the terminal antemortem blood. This substance has been found to be the most stable of any substance studied in the postmortem blood.

d. Creatinine—This substance has been found to be remarkably stable in the postmortem period and to very closely approximate the antemortem blood values.

e. Uric Acid—Studies have shown this substance to have an average value of 5.5 ml/dl to 6.2 ml/dl in the period of time less than 8 hours after death.

f. Cholesterol and Lipids—In the postmortem period, total serum cholesterol remains in the normal antemortem range. It has been found that serum fatty acids, total lipoproteins and beta lipoproteins all remain markedly stable in the postmortem period.

g. Bilirubin—In the normal person there is a small but definite increase in the bilirubin during the postmortem period. In the icteric individual, the postmortem bilirubin concentrations are very similar to the values obtained before death.

h. Protein—There is good correlation between the postmortem and antemortem values of the protein fractions except for a slight decrease in the albumin and a slight increase inthe beta globulin.

i. Acid Phosphatase—There is a marked postmortem elevation in the acid phosphatase values.

j. Alkaline Phosphatase—This enzyme increases during the postmortem period with the values approximately doubling in 8 hours after death and tripling 18 hours after death.

k. Amylase—The blood amylase values are elevated after death with the values reaching a value on the second day after death of three to four times those found before death.

l. Glutamic Oxalic Transaminase and Lactic Dehydrogenase—These enzymes show a striking progressive postmortem increase in concentration.

m. Sodium—The serum sodium begins to decrease immediately after death, and the average rate of fall has been found to be 0.9 mEq/1 per hour.

n. Chloride—Chloride decreases in the postmortem period with the rate of fall being found to be 0.95 mEq/1 per hour.

o. Potassium—There is a marked increase in potassium within the postmortem period.

p. Calcium—Calcium remains constant in the early postmortem period. It should be pointed out that with the Autoanalyzer procedure using cresolphthalein complexone, there is interference from magnesium causing an apparent rise in postmortem calcium.

q. Phosphorus—Both inorganic and organic phosphorus show an increase during the postmortem period.

122. Vitreous Humor Postmortem Chemistries

a. The vitreous humor has been found to be a valuable fluid for determination of postmortem chemistries because it is usually preserved despite serious trauma to the head, and it is much less subject to changes of postmortem decomposition than either blood or cerebrospinal fluid. Also, it has been found that for many substances the postmortem chemical changes occur more slowly in vitreous humor than in blood or cerebrospinal fluid. Approximately 2 ml of crystal-clear fluid can be obtained from each eye. The vitreous humor is aspirated from the lateral angle of the eye (fig. 22).

b. Glucose—It has been found that the vitreous glucose levels are approximately 85 percent of the serum level by the ferricyanide reduction method in the initial postmortem period and then to progressively decrease. It has been found that values over 200 mg/dl in the vitreous indicate antemortem hyperglycemia from diabetes or from some other cause, and diabetic acidosis is easily established by demonstrating ketone bodies in the vitreous. Decreased values of glucose within the vitreous humor are difficult to interpret, but it is thought that hypoglycemia is likely with a vitreous glucose value of less than 20 ml/dl in specimens obtained less than 3 hours after death and there is some predisposing condition such as starvation, chronic alcoholism with hepatic fatty metamorphosis or an islet cell tumor of the pancreas.

c. Urea Nitrogen—This substance has been found to be the most stable of all postmortem constituents in the vitreous humor. Vitreous urea nitrogen is within the normal range for normal individuals, and it parallels the blood urea nitrogen over all ranges of urea retention.

d. Creatinine—This substance has been found to have an average postmortem vitreous level of 1.2 mg/dl compared to an average serum creatinine of 1.5 mg/dl in the same individuals.

e. Enzymes—The vitreous levels of lactic dehydrogenase, glutamic oxalic transaminase, and glutamic pyruvic transaminase have been found to be zero or at minimal levels and to have no relationship to disease.

f. Bilirubin—Studies using the classical Malloy and Evelyn method have found that bilirubin enters the vitreous in small amounts. Studies give a vitreous:serum ratio of 1:220 for total bilirubin, and a ratio for direct acting bilirubin of 1:480.

g. Sodium—Sodium is stable during the early postmortem interval, and values are found to range from 135-151 mEq/1 with an average of 143 mEq/1. Values greater than 155 mEq/1 or less than 130 mEq/1 reflect significant serum deviations.

h. Chloride—Vitreous humor chloride values on normal individuals have been found to vary from 104-132 mEq/1 with an average value of 120 mEq/1. Values below 105 mEq/1 or over 135 mEq/1 are felt to reflect significant antemortem serum values.

i. Carbon Dioxide Content—With the Autoanalyzer technique, carbon dioxide content has been found to vary from 4-27 mEq/1 with an average of 15 mEq/1.

j. Calcium—It has been found that calcium concentrations remain constant during the early postmortem period, and vary from 6.0 to 8.4 mg/dl with an average of 6.8 mg/dl.

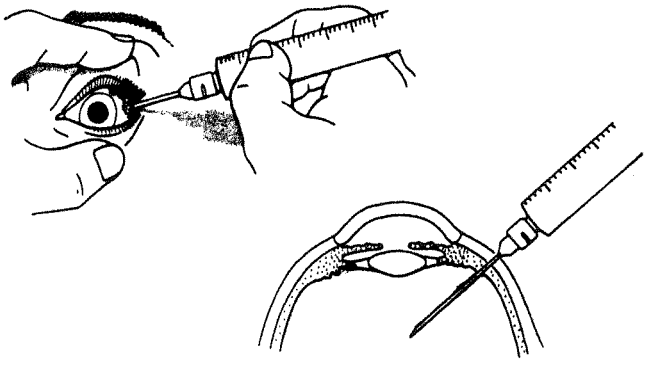

Figure 22.

k. Phosphorus—Inorganic phosphorus levels have been found to vary from 0.1-3.3 mEq/1 with an average value of 1.2 mEq/1.

l. Potassium—Vitreous potassium level rises during the postmortem period and the rise is thought to be independent of environmental factors, with the average rate of rise being 0.17 mEq per hour. The level of vitreous potassium has been used to measure the postmortem interval, but this method is thought to be satisfactory only during the first 12 hours after death.

m. Alcohol—Vitreous humor has been found to be satisfactory for alcohol determination for any of the laboratory procedures now in common use. Blood alcohol equals 0.89 times the vitreous humor alcohol level.

Section X. PHOTOGRAPHY

123. Use

a. Photographs in color or black and white may be used to supplement a report, support a diagnosis, for collection of data, for teaching, for the compilation of a reference file, or for medicolegal purposes. In autopsy photography, special efforts should be made to standardize camera angles and lighting. Do not permit any exaggeration or enhancement of any particular point of interest by camera angle, color filtration, lighting or by the use of lenses of different focal length other than what is considered normal for your camera format. Should your format change, note the circumstances, elevation and angle on the back of the print or on the negative jacket. For medicolegal purposes, any exaggeration or enhancement may result in your photographs being classified as confusing, misleading or even spurious.

b. Photographs of the entire body, including clothing, when supplemented by closeups are often valuable in medicolegal cases. Detail of lesions caused by penetration, impact, pressure, fractures and chemicals may best be shown by closeups, with a separate medium view for orientation purposes. For identification purposes, closeups of occupation marks and stains on the clothing or on the subject are valuable. Backgrounds should be free of extraneous material, and each photograph should show the autopsy number for positive identification. No arrows or pointers should be used to indicate the lesion; the areas covered are then permanently blocked. Overlays may be used on prints and slides to accomplish the same purpose. A ruler or scale should be included in each photographic field on a level with the surface of the body or specimen.

c. Gross specimen photography should be delayed long enough to permit careful dissection of the specimen to exclude all redundant tissue. The specimen should be washed to remove all extraneous material such as blood, fecal material or mucus. Blotting with a soft towel will prevent fluids from dripping on the background and minimize or eliminate highlights; a blotter underneath the specimen will absorb excess fluids. If photographing is delayed or the specimen shows signs of drying, it may be swabbed with a saline solution or 10 percent solution of glycerin. Backgrounds should be white, light grey or black. Modeling clay may be molded into shape to support the specimen in position. Avoid photographing multiple tissue sections if a single section achieves the objective. A dissected specimen can advantageously show internal and external structures in a single photograph. This is particularly true of the kidney or excised neoplasms. Cystic structures should be photographed before they are opened. A closeup of the cyst's interior will emphasize any point of interest, such as papillary projections and solid portions. If the cyst content is of a glare producing mucoid material, photograph it under water. This applies to the delicate villous or papillary neoplasma in hollow viscera such as the urinary bladder. The focal point of the specimen should be in the center and fill most of the photographic field, allowing for the rule or scale.

CHAPTER 6 OBJECTIVES OF THE MEDICOLEGAL AUTOPSY

Section I. PRELIMINARY CONSIDERATIONS

124. Purpose of the Medicolegal Autopsy

The medicolegal autopsy has the special purpose of securing information needed for the administration of justice. This requires a pathologist to direct attention to areas not ordinarily examined during the routine autopsy on a person dying within a hospital. The pathologist performing the medicolegal autopsy should concern himself with circumstances and information gathered from the scene of the incident, as well as what is found on examination of the body within the morgue.

125. Initial Investigation

a. For the pathologist performing the medicolegal autopsy, it is vital to be extremely thorough at every step, because sometimes an item that appeared to be insignificant upon initial examination will later prove to be of crucial importance. The thoroughness required in a medicolegal autopsy should begin with advanced planning, with arrangements being made so that the pathologist will be called to the scene of an incident in any case involving violent death or death under suspicious circumstances.

b. In the event the pathologist cannot visit the scene of the incident, a written preliminary report from the investigative authorities concerning the circumstances surrounding the death should accompany the body to the morgue. The criminal investigators charged with the responsibility of investigating the death should be at the autopsy table and give information to the pathologist concerning the scene, to let the pathologist know what is needed from the autopsy concerning the criminal investigation, and to preserve the chain of evidence in certain types of evidence collected from the body. Photographs and diagrams of the scene where the body was found and the photographs made by the pathologist should be attached to the final autopsy report.

c. It should be a standing rule that neither the clothing nor the surface of the body should be disturbed until examined by the pathologist. In no circumstances should the body be embalmed before performance of a medicolegal autopsy.

d. Restrict witnesses to the autopsy to those whose presence is required either by law or to assist the pathologist. Disclose information regarding the autopsy findings only to those who have a legal right to it.

126. Cause and Manner of Death

In the medicolegal field the terms "*cause of death*" and "*manner of death*" have separate distinct meanings, and these two terms must be understood and kept separated. The *cause of death* is the pathological process sufficient to result in death. The *manner of death* is the circumstances surrounding the incident causing the death. This is the legal opinion expressing or indicating that the death was incurred by natural causes, accident, suicide or homicide, and sometimes the manner of death must be listed as undetermined because there are not sufficient circumstances to make this determination possible.

Section II. AUTOPSY PROCEDURES

127. Scene Visit

a. A visit to the scene of a violent death or death under suspicious circumstances is the first step in a medicolegal autopsy. By inspection of the scene, the pathologist can learn first hand valuable information concerning mechanisms of occurrence and configurations of wounds and injuries found upon the body. The pathologist must be careful that evidence is not disturbed or destroyed by is own examination of the body at the scene. It is advisable to confer with the criminal investigators before moving or disturbing anything at the scene.

b. Even though the criminal investigators will expose photographs at the scene, it is a good idea for the pathologist to take his own photographs for he is in a better position to decide what is medically significant at the scene. Color photographs generally show medical evidence better than black and white.

c. The determination of the time of death must be made at the scene, because it is impossible to make this determination after the body has been in the morgue refrigerator for several hours. All available sources of information should be utilized in determining the time of death. Knowledge of the time of death of a victim of homicide may prove that a given suspect could or could not be guilty. Three sources of information ordinarily relied upon are:

(1) *Witnesses.* Statements from witnesses who claim to have been present at the time of death, to have last seen the decedent alive, or to have first seen the dead body should be taken. Such information may or may not be reliable, and should never be depended upon to the exclusion of other sources of information.

(2) *Rate processes.* An approximation of the time of death can usually be made on the basis of knowledge of length of the time required for the onset or completion of any one of a combination of postmortem changes. When using these rate processes, the time of death is always an approximation, and the time of death should always be given as a range rather than a specific number of hours. Postmortem changes which occur at more or less predictable rates include cooling of the body, livor mortis, rigor mortis, and the stage of postmortem decomposition. Determination of the time of death solely by the observation of the postmortem changes within the body is frought with difficulty, because there are numerous factors which effect the rate at which these changes occur.

(3) *Associated events.* The time of death can be established in relation to certain other events which took place at a known time. In many cases, evaluation of associated events is much more valuable in determining the time of death than observation of postmortem changes within the body. For example, if the ground under the body was dry even though rain has been falling for six hours when the body was found, the inference is that death had occurred before the rain started to fall. If it is known when the victim last ate a meal, the contents of the stomach can be examined and the emptying time of the stomach evaluated; this can be of value in determining the approximate time of death. The number and kinds of associated events that can be useful in determining the time of death is infinite, and their recognition and utilization depend on the alertness and imagination of the pathologist.

d. Place of injury. In the case of an unwitnessed death by violence, it should be established, if possible, that the fatal injuries were or were not received at the place where the body was found. It may be obvious from the nature of the injuries that they could not have been inflicted without coincidental disturbances of the immediate surroundings. Injuries of such a nature as to indicate that the death was preceeded by a violent physical struggle would justify the assumption that they had been received elsewhere if the place in which the body was found was undisturbed. It may be apparent that the decedent bled from his wounds and if not blood is found at the place where the body was discovered, it can be assumed that the injuries were sustained at some other place. The distribution and character of blood drops or smears may be helpful in distinguishing between accident and assault. The distribution of livor mortis and rigor mortis should be carefully ascertained to determine if it is consistent with the position or attitude of the body as found. The medical investigator should view the body and its environment before either has been disturbed.

e. Wounds. Wounds should be examined before the body is moved. If the wounds are characteristic enough to identify them with a particular type of weapon, this type of weapon should be searched for at the scene. In the case of a gunshot wound, it should be ascertained whether there is both an entrance and exit wound or just an entrance wound. If an exit wound is evident, then a bullet should be searched for at the scene. An ejected cartridge case found at the scene may provide valuable evidence as to the identity of the weapon.

f. Trace Evidence. If it is evident that the victim and his assailant engaged in a struggle, trace evidence should be searched for at the scene. This evidence might include hairs or fibers on the hands, clothes, or near the body, or blood or semen stains on the clothing, bed linen or in other areas of the environment. In the poor lighting of the crime scene, it is often easy to overlook trace evidence on the hands. After the hands have been examined at the scene, brown paper bags should be placed over the hands until a more thorough examination can be performed in the autopsy room. It should be noted that fingerprints of the victim are not to be taken at the scene, but these should be taken later in the autopsy room after the hands have been thoroughly examined and undernail scrapings taken as evidence.

128. Extent of Autopsy

A medicolegal autopsy should never be a partial autopsy, and should always include the examination of the brain, neck organs, thorax, abdomen and pelvis. If indicated, the spinal cord should also be examined. The neck organs should always be examined, because sudden death by suffocation can result from the presence of foreign bodies, and there may be fractures of the thyroid or cricoid cartilages due to strangulation. The neck organs should always be examined after the trunk and head to allow blood in the neck vessels to drain away. (See para 139*a*).

129. Clothing

In the medicolegal case, the clothing should be left intact on the body and not removed until the removal is supervised by the pathologist in the autopsy room. Emergency room and morgue personnel should be instructed to leave the clothing on the body when bodies are brought into these areas. In certain types of wounds, for example gunshot wounds and stab wounds, a great deal of information can be gained by careful examination of the clothing and comparing the clothing with the injuries found on the body. In hospital deaths all needles,

catheters, airways, etc., should remain in the body and only removed by the pathologist.

130. Chain of Custody

In medicolegal cases, the chain of custody is very important to ensure that no one tampers with the body without proper authorization. Extra care should be taken to be sure that the refrigerator or the room in which the body is kept is locked at all times. Any physical evidence found in the body, such as a bullet, must be handled extremely carefully to protect it from damage. A bullet found in a body at autopsy should not be handled with forceps because of the introduction of artefactitious markings. The chain of custody of any trace evidence removed from a body must be maintained so that it can be documented in a courtroom proceeding that no unauthorized person had access to the evidence (see fig. 23 or sample documentation). The best way to handle evidence in the autopsy room is for physical evidence to be directly handed to the criminal investigator and the investigator should submit a receipt for the evidence to the pathologist. In the event the criminal investigator is not in the autopsy room, the pathologist must keep the evidence locked in a secure place until it is turned over to authorized persons who will further examine the evidence.

131. Documentation

It is extremely important to document any wounds or evidence found, both for presentation in a possible later court proceeding or for refreshing the pathologist's memory at a later date. Detailed diagrams of all injuries and changes noted on the clothing and body are necessary. Photographs should be made in all medicolegal autopsies because they provide a valuable objective record. Each photograph must have the autopsy number and a scale within the field of view. A photograph of the face should be made for identification purposes. Photographs should be made both with the clothes on and off, and before the wounds are cleaned and after the wounds have been cleaned. As a general rule, color photographs should always be taken, and if black and white prints are needed at a later date, these can be made from the color negatives. Under certain conditions, both black and white and color photographs may be taken. See paragraph 123 for further details concerning photography.

132. Radiographs

In gunshot wound and stab wound cases obtain X-rays of the body regions involved. These may show projectiles lodged in the body or pieces of the weapon broken off internally. If the body is unidentified, get full body X-rays to reveal any abnormality that may aid in later identification. When the possibility of neck injury is suspected, X-rays of the cervical spine should be obtained.

133. Serological and Trace Evidence

In every case of homicide, blood should be removed from the victim for typing. This is useful for attempting to determine whether any blood found at the scene of an incident is from the assailant or the victim. Hairs of an assailant may be found in the hand of the dead person, and abraided epidermis of the assailant may be found beneath the dead person's fingernails. In cases of fatal sexual attack in which rape has preceeded or been coincident with murder, information useful in establishing the identity of the assailant may be obtained by testing the seminal fluid found on the person or clothing of the decedent. It may be possible to determine the blood group to which the assailant belongs even though the seminal stains are old and dry. The specimens (blood, semen, etc.) should be sent to a forensic (crime) laboratory for examination. Each military service has different regulations concerning which laboratory should be utilized; therefore, the local criminal investigative agency should be consulted before any trace evidence is sent to a forensic laboratory.

134. Identification

a. The basic rule of identifying unknown remains is the recording of a careful examination of the unknown remains and comparing this information with information obtained ante mortem. If there is difficulty in examining the remains, such as that caused by postmortem decomposition or mutilation, or if there is difficulty in obtaining antemortem records, then there is a problem with identification.

b. In the usual case, there is no difficulty in identifying the remains as human or nonhuman. If changes of postmortem decomposition are not too advanced, this distinction can be made by means of the precipitant test. Specific antisera are available not only for distinguishing between materials of animal and human origin, but also for identifying the kind of animal from which the material was derived. This type of test can best be performed in the serology section of a forensic laboratory. If the material to be identified includes any part of the bony skeleton, consultation with an anatomist, anthropologist or roentgenologist will be extremely helpful in establishing or excluding human origin. The examination of hair by an expert within a forensic laboratory often makes it possible to decide between animal or human origin.

c. Even if only skeletal remains are found, an anthropologist can determine a great deal of information from a careful examination. According to how much of the skeleton is found, the anthropologist can likely tell the

EVIDENCE PROPERTY CUSTODY DOCUMENT

For use of this form see AR 190-45 and AR 195-5; the proponent agency is US Army Criminal Investigation Command

MPR/CID SEQUENCE NUMBER: 76-CIDO 13-005

CRD REPORT /CID ROI NUMBER: 76-CIDO13-50125

RECEIVING ACTIVITY	LOCATION
Fort Benning Field Office, USACIDC	Fort Benning, GA 31905
NAME, GRADE AND TITLE OF PERSON FROM WHOM RECEIVED [X] OWNER John J. Doe, PFC [ ] OTHER	ADDRESS (Include Zip Code) CO A, 1st Bn, 4th Tng Bde USAIC, Ft Benning, GA 31905

LOCATION FROM WHERE OBTAINED	REASON OBTAINED	TIME/DATE OBTAINED
Person of PFC Doe Room 15, Bldg 101 Ft Benning, GA	Evidence	2100 1 Jan 76

ITEM NO.	QUANTITY	DESCRIPTION OF ARTICLES (Include model, serial number, condition and unusual marks or scratches)
1	1	Brown colored paper bag (Approx 4X5 inches in size) containing suspected marihuana. (Taken from left pocket of shirt worn by DOE).
2	Approx 50	White tablets suspected to contain LSD several of which are broken into smaller particles and crushed into powder form. (The total amount of 50 tablets is based on an estimate of the tablets if they were all in tact) (Taken from the right pocket of shirt worn by DOE and placed into plastic evidence bag).
		xxxxxxxxxxxxxxxxxxxxxxxLAST ITEMxxxxxxxxxxxxxxxxxxxxxxxxxxxxxxxxxxxxxxxx

SAMPLE

CHAIN OF CUSTODY

ITEM NO.	DATE	RELEASED BY	RECEIVED BY	PURPOSE OF CHANGE OF CUSTODY
1 2	1 Jan 76	SIGNATURE /s/ John J. Doe NAME, GRADE OR TITLE JOHN J. DOE, PFC	SIGNATURE /s/ Harvey S. James NAME, GRADE OR TITLE Harvey S. James, SA	Seized for Evidence
1 2	1 Jan 76	SIGNATURE /s/ Harvey S. James NAME, GRADE OR TITLE HARVEY S. JAMES, SA	SIGNATURE /s/ George M. Smith NAME, GRADE OR TITLE GEORGE M. SMITH, SA	Rel to Evidence Custodian
1 2	2 Jan 76	SIGNATURE /s/ George M. Smith NAME, GRADE OR TITLE GEORGE M. SMITH, SA	SIGNATURE Reg. Mail NAME, GRADE OR TITLE 1234	Fwd to USACIL-CONUS for Exam
1 2	4 Jan 76	SIGNATURE Reg Mail NAME, GRADE OR TITLE 1234	SIGNATURE /s/ James Q, Madison NAME, GRADE OR TITLE JAMES Q, MADISON, GS-9	Rec,d at lab for Exam
1 2	6 Jan 76	SIGNATURE /s/ James Q, Madison NAME, GRADE OR TITLE JAMES Q, MADISON GS-9	SIGNATURE Reg Mail NAME, GRADE OR TITLE 5678	Ret to Submitter

DA FORM 4137
1 JUL 76

Replaces DA FORM 4137, 1 Aug 74 and DA FORM 4137-R Privacy Act Statement 26 Sep 75 Which are Obsolete.

LOCATION _____ DOCUMENT NUMBER _____

Figure 23 (1).

CHAIN OF CUSTODY *(Continued)*

ITEM NO.	DATE	RELEASED BY	RECEIVED BY	PURPOSE OF CHANGE OF CUSTODY
1 2	8 Jan 76	SIGNATURE: Reg Mail NAME, GRADE OR TITLE: 5678	SIGNATURE: /s/ George M. Smith NAME, GRADE OR TITLE: GEORGE M. SMITH SA	Rec,d by Evidence Custodian
1 2	10 Jan 76	SIGNATURE: /s/ George M Smith NAME, GRADE OR TITLE: GEORGE M. SMITH, SA	SIGNATURE: /s/ Hugh H. Joyce NAME, GRADE OR TITLE: HUGH H. JOYCE, CPT	Rel to Trial Counsel for Court
1 2	12 Jan 76	SIGNATURE: /s/ Hugh H. Joyce NAME, GRADE OR TITLE: HUGH H. JOYCE, CPT	SIGNATURE: /s/ George M. Smith NAME, GRADE OR TITLE: GEORGE M SMITH, SA	Ret to Evidence Custodian
1 2	14 Jan 76	SIGNATURE: /s/ George M, Smith NAME, GRADE OR TITLE: GEORGE M SMITH, SA	SIGNATURE: Destruction NAME, GRADE OR TITLE: by Burning	Final Disposition
		SIGNATURE NAME, GRADE OR TITLE	SIGNATURE NAME, GRADE OR TITLE	
		SIGNATURE NAME, GRADE OR TITLE	SIGNATURE NAME, GRADE OR TITLE	
		SIGNATURE NAME, GRADE OR TITLE	SIGNATURE NAME, GRADE OR TITLE	
		SIGNATURE NAME, GRADE OR TITLE	SIGNATURE NAME, GRADE OR TITLE	

SAMPLE

FINAL DISPOSAL ACTION

RELEASE TO OWNER OR OTHER *(Name/Unit)* _____

DESTROY Items 1 and 2

OTHER *(Specify)*

FINAL DISPOSAL AUTHORITY

ITEM(S) 1 and 2 ON THIS DOCUMENT, PERTAINING TO THE INVESTIGATION INVOLVING PFC *(Grade)*

John J. Doe, A/1/4, USAIC *(Name)* *(Organization)* (XXXARE) NO LONGER

REQUIRED AS EVIDENCE AND MAY BE DISPOSED OF AS INDICATED ABOVE. *(If article(s) must be retained, do not sign, but explain in separate correspondence.)*

HUGH H. JOYCE, CPT, JAGC	/s/ HUGH H, JOYCE	12 Jan 76
(Typed/Printed Name, Grade, Title)	*(Signature)*	*(Date)*

WITNESS TO DESTRUCTION OF EVIDENCE

THE ARTICLE(S) LISTED AT ITEM NUMBER (S) 1 and 2 (WAS) (WERE) DESTROYED BY THE EVIDENCE CUSTODIAN, IN MY PRESENCE, ON THE DATE INDICATED ABOVE.

Hubert L. Harrison, Ft Bng FO	/s/ HUBERT H HARRINGTON
(Typed/Printed Name, Organization)	*(Signature)*

Figure 23 (2).

age of the individual at death, sex, race, stature, and acquired individual characteristics that are evident in the skeletal system.

d. If an intact body is found, the most reliable method for identification in the United States is fingerprints. The Federal Bureau of Investigation has a large repository of fingerprint data with which to compare the fingerprints of unknown individuals. Even with decomposed bodies, it is sometimes possible to get adequate fingerprints with special techniques, and sometimes it is necessary to remove the distal portions of the fingers and send them in individually labeled containers to the Federal Bureau of Investigation.

e. Examination of the unknown individual's teeth and comparing abnormalities noted with antemortem dental records is another extremely valuable way of establishing identity. A dentist is very valuable for recording the data from the unknown remains and helping to obtain antemortem dental records. There is no central repository for dental records; therefore, it is necessary to get these records from individual dentist's offices. With mutilated bodies, it is sometimes necessary to remove the maxilla and mandible for later use in identification.

f. In the examination of any unknown remains, it is extremely helpful to get an X-ray examination of the remains. With careful X-ray examination it is possible to get information relating to the age of the deceased, individual characteristics that might be helpful in identification, and finding bullets and other foreign bodies that might otherwise be overlooked.

g. The performance of a careful autopsy many times can give valuable information as to the identity of the individual. On external examination of the body, any scars or tattoos or other possible identifying characteristics should be noted. Even if the body is badly mutilated by postmortem decomposition or thermal burns, it is possible by finding various internal organs being absent that the presence of external scars is extremely likely. Certainly internal examination of the body is very helpful for determining the sex of the individual. By the finding of certain pathologic conditions of internal organs and comparing this with past medical records, it is possible to get valuable information concerning the identity of an individual.

h. There are laboratory examinations that are useful in identification of unknown remains. The determination of blood groups is helpful and should always be done in cases of unknown remains if not precluded by changes of decomposition. The examination of hair gives certain information valuble for determining race and certain other individual characteristics such as bleaching or dyeing of the hair. Information obtained from the examination of blood and hair is not used to positively identify an individual, but it is useful for exclusionary purposes, especially in cases of mass disasters.

i. There are other things that are useful in identification, but these are not thought to be as reliable as the above mentioned more scientific methods. These methods include recognition by family or friends, examination of the clothing, personal effects found on the body or in the clothing, and other characteristics such as a specific eye glass prescription or the finding of contact lenses within the eyes.

j. When identification of a body or parts of a body is unusually difficult or when multiple detached parts of several bodies present a problem, technical specialists are available to give aid as indicated in AR 638-42/BUMEDINST 5360.1B/AFR 143-4. The Department of the Army Technical Manual entitled "Identification of Deceased Personnel" (TM 10-286) provides helpful information. Assistance concerning identification can be obtained from the Division of Forensic Pathology, Armed Forces Institute of Pathology, Washington, DC 20306.

135. Examination of Injuries

a. The description and measurement of injuries are one of the most important aspects of a medicolegal autopsy. Wounds should be located on the body with measurements of the distance from the top of the head and from the midline of the body. In addition it is useful to localize wounds using nearby prominent body landmarks. The dimensions of each individual wound should be accurately measured. Probes should not be stuck into wounds until all measurements have been taken and the internal tracks of wounds are identified and measured. The tracks of gunshot wounds or stab wounds should be completely identified before any of the internal organs are removed for further examination.

b. The shape or configuration of wounds may reveal the type of instrument used in their production. Thus, the pattern of an automobile tire or radiator grill may be imprinted on clothing or skin. Wounds produced by a given type of hammer, wrench, file, etc., may have highly individual characteristics. Wounds should be examined carefully for any trace evidence, such as rust or paint chips, that might link the wound with a suspected weapon used in the assault.

c. The nature and location of injuries are often the means of distinguishing between suicide and homicide. This is particularly true in the case of firearm injuries. In the study of fatal injuries of this kind, wounds of en-

trance must be distinguished from wounds of exit and the characteristics of the region of the entrance wound described in detail, for these characteristics may indicate the distance between muzzle and target when the fatal shot was fired. The finding of powder residue in the disrupted tissues immediately beneath the entrance wound indicates that the muzzle was in contact with the target at the time of weapon firing. Powder residue surrounding the wound indicates that the muzzle was relatively close to the target. The shorter the distance between muzzle and target, the greater will be the tendency for powder residue to be concentrated in the immediate vicinity of the entrance wound. When the weapon is a handgun, rarely will powder residue be deposited on the surface of the skin if the range of fire is greater than eighteen inches. If questions arise concerning the range of fire, range tests must be performed using the same type of ammunition and weapon used in the actual assualt. In cases of fatal injury by close range rifle or shotgun fire in which the question of suicide may be raised, two measurements should be made: The distance between the entrance wound and the trigger when the muzzle is placed against the wound, and the distance between the entrance wound and the forefinger of the extended hand. Such measurements give some indication whether the wound could have been self inflicted, However, in certain instances of suicide the individual has been known to have used his toe or some external object in order to pull the trigger.

d. It may be of utmost importance from a medicolegal standpoint to establish as accurately as possible the interval between injury and death. Injury is usually followed by an orderly sequence of reactive changes, and a recognition of these may make it possible to estimate the time that has elapsed. Thus, microscopic examination of the injured tissue may show that a given injury could not have been sustained more than a few minutes before death or that injury was sustained hours, days, or weeks before death. The establishment of a civil or criminal responsibility of some individual may depend to a great degree upon the amount of care that has been exercised in the acquisition of such information. The circumstances may be such that a given individual could or could not be responsible for the fatal injury if it were known that it was received before or after some specific time.

e. It is frequently impossible to determine whether one or several assailants participated in a given assault. Such a determination can be made, however, in some incidents of homicide by shooting. If examination discloses that the injuries were inflicted by several different weapons as indicated by the character of the wounds or differences in bullets, it can sometimes be assumed that several persons participated in the attack. It is extremely important to recognize that there is the possibility of more than one assailant, and to describe accurately and in detail the nature of the wounds' tracks and the extent and nature of the injuries produced by each missile. It is for this reason that it is of crucial importance that each missile within the body be recovered for submission to a crime lab for examination. On the surface of a bullet there are usually markings characteristic of the firearm from which it was discharged.

f. It is important not only to determine the interval between injury and death, but also to reconstruct the sequence in which any given series of injuries was received. In cases of multiple injuries, it may be found that certain wounds were received after others, some may even have been inflicted after death. In such incidences it may be apparent that suicide or a plea of acting in self defense is untenable. In other incidences it may be found that the injuries were separated by hours or even days. If such injuries have resulted from assault, there may be clear evidence of premeditation and extreme cruelity.

g. Sometimes it is important to determine if the injuries received were immediately incapacitating and if not, to what extent and for how long was the deceased capable of movement. It is important to interpret the injuries to determine the extent to which the decedent may have contributed to their existence. In such circumstances it may be important to know what he might have done after certain injuries were sustained. If he could not have come unaided to the place where his body was found, it can be assumed that someone is in possession of special knowledge regarding the circumstances in which the injury was received.

136. Toxicology

The examination of body fluids and tissues for drugs and toxic substances is a vital part of any medicolegal autopsy. There should be a blood alcohol determination in almost all medicolegal cases because of the widespread use of this drug, and according to the circumstances and anatomic findings of a case, there may be indications for testing for other drugs. It is important for the pathologist to give the circumstances surrounding the death to the toxicologist, and this will enable the toxicologist to conduct his examination in a more intelligent manner. The specimens for toxicologic examination should be collected, preserved, and shipped as described in paragraph 113.

137. Mutilated, Decomposed and Burned Bodies

When confronted with a body which has been mutilated by extreme trauma, distorted by postmortem decom-

position or partially destroyed by thermal burns, care should be taken to not overlook important changes. There is a tendency to only do a superficial examination on these types of bodies, but a careful, methodical examination can many times uncover changes which are vital to the understanding of the cause and manner of death. For instance, it may be possible to ascertain that coronary arteriosclerotic heart disease was the probable cause of an automobile accident causing mutilating injuries, or that there is a small caliber bullet within the chest of a severely decomposed body found in a wooded area. Always photograph and X-ray a decomposed or burned body.

138. Investigation of Diving Fatalities

a. This discussion will deal primarily with the investigation of fatalities due to SCUBA (Self-contained Underwater Breathing Apparatus) diving, but the general investigative principles can be used to investigate deep sea diving fatalities. The investigating pathologist should be familiar with hyperbaric pathophysiology and SCUBA technology, and these are discussed in various articles and text books.

b. For practical purposes, the death of an individual involved in a SCUBA accident can be classified under decompression sickness or air embolism. In decompression sickness, nitrogen with the inspired air goes into solution in the blood and/or tissues of the body as the pressure increases during the diver's descent. As the diver ascends without proper decompression stops, the nitrogen bubbles may come out of solution and the disease manifests itself as bubbles in joint spaces, within the central nervous system, within the small pulmonary artery vessels and within the vascular system to the spinal cord. Decompression sickness does not cause immediate death but can cause delayed death. Air embolism is sometimes classified under the general term of extra-alveolar air syndrome, which includes air emphysema, pneumothorsx, mediastinal emphysema or pulmonary interstitial emphysems. The most serious of these is an air embolism into the pulmonary vasculature, and when a diver dies suddenly, this entity is a strong possibility. Air embolism occurs when a diver does not properly exhale on ascent but holds his breath; as the pressure decreases, the air expands in the "closed" alveoli leading to their rupture and the passage of air into the vascular tree. Table 1. gives a comparison of air embolism and decompression sickness.

*Table 1. Comparison of air embolism and decompression sickness**

	Air Embolism	Decompression Sickness
1. Analagous physical model.	Overdistended balloon with rupture.	Uncapped bottle of soda water.
2. Depth precipitating onset symptoms.	Shallow; maybe less than 10 feet.	No cases documented from less than 30 feet; generally much deeper.
3. Mode on onset.	Generally immediately upon surfacing; rarely after 5 minutes.	Generally insidious; 86 percent occur in the first hour but may be delayed up to 24 hours.
4. Presenting signs and symptoms.	Unconsciousness and convulsions are very common.	Only 1 percent become unconscious; most have pains in muscles and joints.
5. Central nervous system involvement.	Common; commonly have identifiable cerebral-arterial occlusive syndromes.	Uncommon; if it occurs it is usually a spinal syndrome.
6. Onset of death.	Not uncommonly occurs shortly after surfacing; may be delayed.	Usually delayed for days but death uncommon; no documented cases of acute death shortly after surfacing.
7. Decompression treatment approach.	U.S. Navy Tables 5A or 6A.	U.S. Navy Tables 3, 4, 5, or 6.
8. Expected relevant pathologic findings.	Acute deaths: identifiable bubbles in coronary and/or cerebral arterial circulations; presence of pneumothorax, subcutaneous or mediastinal emphysema; pneumopericardium. Delayed deaths: no bubbles; presence of ischemic and/or hemorrhagic infarcts in the heart and brain.	Delayed deaths: ischemic hemorrhagic infarcts, predominantly in the thoro-lumbar cord; may be scattered cerebral hemorrhages.

*Table 1 is reprinted from legal Medicine Annual 1976 by permission of Richard T. Goldhahn, Jr., the author, and Appleton-Century-Crofts, New York, the publishers.

c. As with all cases of sudden and unexpected death, the first step of the investigation is a thorough examination of the scene of the incident. If the investigating pathologist is not able to make an on-site investigation, he should talk to competent investigators who have visited the scene of the incident. The history of the victim's experience with diving is important. The details of the dive itself should be investigated, as well as the weather conditions at the time of the incident. The pathologist should be knowledgeable of the way that the body was recovered, and have information concerning any resuscitation attempted.

d. The investigating pathologist should examine carefully the diving equipment used and the clothing worn by the victim. The body should be viewed by the pathologist as it was recovered, before any of the clothing or equipment is removed. If the pathologist is not familiar with SCUBA equipment, this should be examined by a person knowledgeable in this field. All of the equipment should be analyzed for possible malfunction. The status of the regulator mechanism and the position of the air reserve safety lever on the tank valve should be examined. Air left within the tank should be analyzed for impurities and percentage of oxygen in the compressed air. The interior of the tank should be examined for abnormalities that might possibly block the valves within the equipment.

e. An autopsy should always be performed when there is a fatality involving SCUBA diving. Photography is a very important part of the investigation, and all phases of the autopsy should be documented by numerous photographs. Drowning is a very common terminal event in a diving fatality, but the crucial information needed is what was the underlyng event that led to the drowning.

f. During the external examination of the body, any injuries should be carefully documented. Any injuries inflicted by marine animals should be noted and evaluated as to their effect on the victim during life. It is possible that injuries due to marine life could initiate a chain of events that could lead to the subsequent death of the individual. It is also important to recognize postmortem injuries inflicted upon the body. If at all possible, a full body X-ray examination should be performed. The X-rays may indicate unsuspected aseptic bone necrosis and collection of air in subcutaneous tissue or body cavities.

g. A thorough internal examination must be performed. In any SCUBA fatality, it is important to rule out arterial air embolism. The first incision into the body should be in the scalp, and the calvarium should be carefully removed. The circle of Willis and its branches are the important areas to look for air bubbles. Before these areas are cut, the frontal lobe should be reflected, the optic nerves cut, and the circle of Willis along with the basilar artery should be inspected. The middle cerebral arteries are also inspected for evidence of air embolism. If bubbles are identified, these should either be photographed in situ or the carotid arteries clamped and the brain removed for photographs. The chest should be opened next using the standard techniques for documenting free air within the pleural and pericardial cavities. The coronary arteries should be examined for air bubbles and the presence of air within the cavities of the heart should be documented. The lungs should be examined in situ for pleural lacerations, blebs, bullae, hemorrhage, and atelectasis. Injuries to the tongue or lips suggest agonal convulsions. If the X-rays identify bone lesions of aseptic necrosis, these areas should be sampled. Without the benefit of X-ray studies, blind biopsies of femoral or humeral heads, distal femur and proximal tibia should be obtained. It is a good idea to remove the temporal bones, both for documenting middle ear hemorrhage and checking for the effects of acute and chronic hyperbaric exposure to the middle ear structures. The tympanic membrane should be examined for evidence of rupture, because tympanic membrane rupture can cause disorientation leading to serious problems in the underwater environment. A complete autopsy should be performed to identify any acute or chronic disease that might have caused or led to the person's death.

h. A toxicological examination should always be performed on the victim's fluids and tissues to document any drug use that might have influenced the person's actions. The blood should always be analyzed for ethanol and carbon monoxide, and a complete drug screen should be performed if the circumstances indicate.

139. Special Techniques

a. Anterior Neck Dissection with Removal of the Tongue. The removal of the neck organs with examination of the tongue should be performed as a part of every medicolegal autopsy. Fresh bite marks give support to the possibility that a seizure preceded death. Also, a good view of the upper air passage can be obtained for examination for possible foreign bodies. After the chest organs and the brain have been removed, the shoulder region of the body should be elevated on a board or head rest. Reflect the skin of chest and neck to the level of the mandible. The layers of tissue of the anterior neck should be examined to reveal any hemorrhage within the muscle or soft tissue. The carotid arteries on each side should be identified and preserved so that the body can be properly embalmed at a later time. A knife should be inserted beneath the mandible

in the area of the symphysis and pushed through the floor of the mouth (fig. 24). The tip of the knife will emerge under the tongue. Cut along each side of the mandible to the angle of the mandible, using care to avoid severing the carotid arteries. The tissue is then freed beneath the mandibular arch and the soft palate is cut to include the uvula and tonsils with the tongue and neck organs to be removed. The esophagus and trachea are freed from the tissue posteriorly and the neck organs along with the tongue are removed. The tongue is examined for evidence of fresh bite marks and the oropharynx and hypopharynx are examined for lesions or foreign bodies obstructing the air passages. The structures of the neck should be examined more closely by removing all tissue and muscle from the bone and cartilage with the sharp end of a scalpel in a scraping motion. Any hemorrhage or fractures of the bone or cartilage should be noted. The greater horns of the hyoid bone and the superior horns of the thyroid cartilage are particularly prone to fracture and should be carefully examined. The larynx and trachea should be opened posteriorly and any lesions or foreign bodies identified.

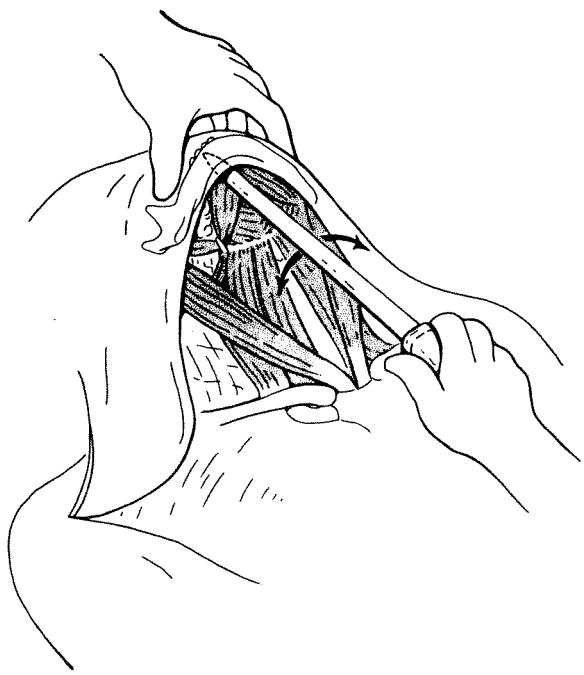

Figure 24.

b. Posterior Dissection of the Neck. When there is the possibility of injury to the cervical spine, as in falls or in whiplash trauma, the neck should be examined from the posterior approach. Before dissection, X-rays should be taken of the cervical spine. After the brain, neck organs and chest organs have been removed, the body is placed face down with a board or head rest under the shoulder region. The head is flexed and a midline incision is made on the back of the neck. The tissues are dissected layer by layer to document any hemorrhage. After the tissues have been cleared from the vertebral column, the vertebrae should be examined for evidence of fractures. The laminae of the cervical vertebrae can be cut and the spinal cord visualized. After removal of the spinal cord, the vertebrae should be examined again for hemorrhage and/or instability.

c. Demonstration of Thrombi in the Leg. This technique is used to determine the source of thromboemboli found within the legs after embolization to the pulmonary vasculature. The calves of the legs should be inspected for variation in size. Incise the larger calf posteriorly from the heel to the popliteal fossa and reflect the skin laterally and medially. Divide the Achilles tendon and dissect the leg muscles from the bones from the heel upward. Avoid damage to the arteries of the leg located between the tibia and fibula. Incise the muscles of the calf in a bread-loaf fashion at 2 cm intervals. Antemortem thrombi in the veins will distend the vessels and extrude from the vessels. Postmortem clots are flabby in comparison and will not fill and distend the veins. Both legs should be examined.

140. Autopsy Protocol of the Medicolegal Autopsy

It is preferable to have a slightly different format of the medicolegal autopsy protocol as compared to the autopsy protocol of a routine hospital death. The first part of the protocol should be a *Summary of the Circumstances* surrounding the death, and if at a later time the complete investigative report is received, this can be attached to the completed protocol. The next section should be an *External Description* which includes a description of the clothing, general appearance, description of rigor mortis and livor mortis, body temperature, and a description of any significant identifying features. The next section should be entitled *Evidence of Injury,* and in this section all injuries should be described rather than describing injuries under each individual organ system. In this section the tracks of stab wounds or gunshot wounds should be described in their entirety. For example, a gunshot wound wouldhave a description of the entrance wound, a description of the direction of the wound track and organs injured by the path of the missile,

and a description of the exit wound. When there are multiple gunshot wounds, each wound should be identified with an entrance wound, wound track, and exit wound. The next heading should be *Evidence of Medical and/or Surgical Treatment* and this would identify any evidence of therapy as contrasted to any injuries that were received. The next section is the *Internal Examination* in which the organ systems are described as in the routine autopsy. The *Summary* of the autopsy should include only those things that are factual and no speculative ideas should be given. The autopsy protocol must be proofread carefully so as to not decrease the credibility of the document by typographical errors. Copies of photographs, X-rays and toxicology reports should be attached as part of the completed report.

141. Court Appearances

The most important preparation for any court appearance is the careful performance of a complete and thorough autopsy and being certain that the autopsy report is correct. When a pathologist is summoned or ordered to appear in a court proceeding, he should insist upon a pre-trial conference with the attorney to discuss the court proceedings and the specific items that the attorney wants emphasized. Even though the pathologist is summoned by either the prosecution or the defense in the case, the pathologist should not be on one side or the other, but be an impartial witness to present the autopsy findings of the case. As final preparation for a court appearance, the pathologist should know the case material well and try to anticipate any questions that might be asked by doing extra research concerning the subject matter of the case.

142. Classical Mistakes in Forensic Pathology

On October 11, 1956, Dr. Alan R. Moritz presented the Ward Burdick Award address at the Thiry-Fifth Annual Meeting of the American Society of Clinical Pathologists in Chicago, Illinois. The title of his address was "Clinical Mistakes in Forensic Pathology" and from his own forensic pathology experience and the experience of colleagues that he had consulted, he gave the following mistakes:[1]

a. Not being aware of the objective of the medicolegal autopsy.

b. Performing an incomplete autopsy.

c. Permitting the body to be embalmed before performing a medicolegal postmortem examination.

d. Regarding a mutilated or decomposed body unsuitable for autopsy.

e. Nonrecognition or misinterpretation of postmortem changes.

f. Failing to make an adequate examination and description of external abnormalities.

g. Confusing the objective with the subjective sections of the protocol.

h. Not examining the body at the scene of the crime.

i. Substituting intuition for scientifically defensible interpretation.

j. Not making adequate photographs of the evidence.

k. Not exercising good judgement in the taking or handling of specimens for toxicologic examination.

l. Permitting the value of the protocol to be jeopardized by minor errors.

m. Talking too soon, too much, or to the wrong people.

143. Medicolegal Autopsy Report Form

The medicolegal autopsy report form (see fig. 25, DA Form 4885-R, located in the back of this manual) is a computer adapted revision of the protocol developed and presented by the panel on "Autopsy Protocol," Dr. Russell S. Fisher, Chairman, at the International Conference on Accident Pathology, Washington, DC, June 8, 1968. This form along with the accompanying body diagrams may be reproduced at the local level to be used as the protocol for medicolgeal autopsies, or the form may be used as a check list to be certain that all information is included in other formats of medicolegal autopsy reports.

---

[1]Moritz, A. R., Classical Mistakes In Forensic Pathology. *Am. J. Clin Path.*, 26:1383-1397, 1956.

CHAPTER 7
SELECTION AND PRESERVATION OF TISSUE FOR FURTHER STUDY AND MUSEUM PURPOSES

Section I. FIXATION OF BLOCKS FOR MICROSCOPIC STUDY

144. Selection of Tissue

Blocks of tissue to be used for microscopic study should be selected as follows:

a. Tissue should not be crushed or otherwise injured before it is selected and cut from the organs. The mucosa of the intestine should not be touched or washed before the block is taken. Contact of any tissue with water should be avoided before fixation.

b. Use adequate amounts of fixative. Twenty volumes of fluid for each one volume of tissue is recommended.

c. If there is a focal lesion, the block should be taken to include the junction of the lesion with the normal tissue.

d. The block should be sufficiently thin to allow rapid penetration of the fixative—*not over 0.5 cm in thickness.*

e. Ample tissues should be taken for microscopic study and more than one block from significant areas. The blocks should be sufficiently large for orientation and identification of the parts of the organ—ordinarily not less than 1.5 to 3 cm square.

f. Sections of each organ should be taken through representative structures; for example, blocks from the kidney should include the cortex, medula, and pelvis; blocks from the intestine should include a lymphoid follicle; blocks from the heart should include ventricles, atria, valves, and coronary arteries.

g. In organs covered by a serious membrane at least one block should include the serosa.

h. If there is any question of identification (sections from the base and tip of the appendix, from each of paired organs, or from the various lobes of the lung), each block should be placed in a separate bottle or cut in a distinctive shape, so that they can be identified later.

i. Make certain that the tissue is not bent, twisted, or distorted after it is placed in the fixative. Small pieces of tissue may be placed on a paper towel and then floated into the fixative. There is sufficient protein on the surface of most organs to coagulate and hold the tissue to the paper.

j. Over-fixation in some fixatives may do much harm. Tissue should never be fixed in Zinker's fluid for longer than 12 hours.

145. Fixation

a. Ten percent neutral buffered formalin: fix for 24 to 48 hours.

b. Zenker's fluid: fix for 12 hours, wash for 2 hours in running tap water and then place in 70 percent alcohol.

c. Bouin's Fluid: fix tissue for 18 hours, place specimens in 70 percent alcohol for 3 hours. If time permits, extend the exposure in 70 percent alcohol up to 18 hours to allow removal of as much picric acid as possible.

d. McDowell and Trump's Formaldehyde—Glutaraldephyde (see para 118*a*).

146. Formulae for Fixatives

a. Formalin. This is the best fixative for general purposes. It is prepared by mixing one volume commercial formalin (37-40 percent formaldehyde solution) with nine volumes of tap water. The 10 percent formalin (3.7-4.0 percent formaldehyde solution) should be neutralized and buffered (pH 7.0) by the addition of 4 gm acid sodium phosphate monohydrate and 6.5 gm anhydrous disodium phosphate *per liter.* If the chemicals are not available, neutralization can be accomplished by adding a sufficient amount of sodium acetate (see AFIP Staining Manual).

b. Ethyl Alcohol. This should be used only for special purposes. For fixation and prolonged storage of tissues for glycogen stains, use absolute alcohol. For certain cytological studies of the central nervous system, use 95 percent alcohol. When formalin is not available, 95 percent ethyl alcohol may be used if the tissue sections are cut less than 0.3 cm thick.

c. Zenker's Fluid.

Potassium bichromate	2.5 gm
Mercuric chloride	5.0 gm
Distilled water	100.0 ml

At the time of use, add 5 ml glacial acetic acid to 95 ml of the above mixture. If mercuric chloride is not available, 2.5 gm zinc chloride may be substituted. For fixation of bone marrow, in which there are spicules of bone, add 10 ml glacial acetic acid to 90 ml of the above solution to facilitate decalcification.

d. Bouin's Fluid.

Glacial acetic acid ..... 5 ml
Commercial formalin ..... 25 ml
Picric acid, saturated aqueous solution ..... 75 ml

e. McDowell and Trump's Formaldehyde—Glutaraldehyde (see para 119*a*).

Section II. PRESERVATION BY DEEP FREEZING FOR BACTERIOLOGICAL, SEROLOGICAL, AND HORMONE STUDY

147. Methods of Preservation and Storage

a. Tissue, fluid, or feces can be stored in a frozen state pending future examination for microorganisms, hormone assay, or serological reactions. Virus recovery is most successful if the material has been kept at −60° C to −70° C. The autopsy should be performed promptly so that the material will be fresh.

b. Tissue or fluid in 1 ml amounts should be obtained under sterile conditions and each sample placed in a separate, labeled, wide-mouthed bottle; representative pieces of adjacent tissue should be fixed for histological study.

c. Blood serum may be collected by withdrawing 10 ml of blood in a sterile dry syringe, and transferring it to a sterile centrifuge tube. After clotting, the blood is centrifuged, serum withdrawn and transferred to a sterile Wasserman tube and sealed with a rubber sleeve-type stopper. The tube should be frozen in an inclined position.

148. Hormonal Study

If hormonal study is the objective, the autopsy should be performed immediately. The organ to be studied should be weighed in its entirety and blocks selected for histologic study. The remainder, or a large portion of the organ, should be frozen and maintained at −20° C. Analysis should be carried out promptly.

Section III. PRESERVATION OF TISSUES FOR MUSEUM PURPOSES

149. Objective

In the selection and preparation of a specimen for display in a museum, the prosector should bear in mind that the tissue is to be viewed by others who do not have the advantage of inspecting the entire organ and other organs.

150. General Principles

The following general principles are suggested as a guide:

a. The specimen should have one flat surface, cut with one stroke of a large knife.

b. The specimen should not be thicker than 2 to 3 cm, since fixative will not penetrate beyond a few centimeters. With large organs, fix half of the organ and then cut the slab to include the original cut surface.

c. With large solid viscera, two parallel surfaces should be prepared, each by a single stroke of the knife.

d. Cut the organ in such a way that orientation is possible.

e. Do not cut a new surface after fixation except as mentioned in *b* above, for the characteristic contour may be lost.

f. Place the specimen in the fixative so that it is not distorted.

g. Do not cover specimens with paper towels, because these will leave an imprint of the towel's fibers. If the tissue floats, cover it with a layer of absorbent cotton, the fibers of which, by capillary attraction, will draw fluid over the exposed surface. Cover the container lightly.

h. Opened hollow viscera may be pinned on a board, using care to avoid tension which produces distortion.

i. Be sure that the specimen does not adhere to the sides or bottom of the vessel, preventing contact of the fixative with all surfaces.

j. Label each specimen. The most satisfactory method is to print the identifying number on line cloth with India ink, dip the cloth in melted paraffin, and after cooling, sew the label to the specimen.

Section IV. FIXATION OF MUSEUM SPECIMENS

151. Methods and Solutions

Formaldehyde converts hemoglobin to acid hematin, thus causing loss of characteristic color. The following methods will aid in preservation of color:

★*a. The Kaiserling Method.* The tissue is fixed in a solution designated as Kaiserling I, made as follows:

Potassium acetate ..... 170 gm
Potassium nitrate ..... 90 gm
Commercial formalin ..... 1,600 ml
Water—sufficient to make ..... 8,000 ml

After 3 to 7 days, the specimen is washed in running water from 12 to 24 hours and then placed in 95 percent ethyl alcohol, referred to as Kaiserling II. Alcohol converts the brown acid hematin into reddish brown alkaline hematin. The specimens should be kept under observation in alcohol from 6 to 24 hours, until there is maximum development of the reddish color. If ethyl alcohol is not available, tertiary butyl alcohol may be substituted. Remove the specimens from the alcohol, wash in running water for not over 2 hours, and place in the final mounting fluid, known as Kaiserling III, made as follows:

Potassium acetate	1,720 gm
Glycerol	2,000 ml
Water—sufficient to make	10,000 ml

As a preservative, add to the above, 20 ml of phenol or crystals of thymol until the solution is saturated. If phenol or thymol is not available, arsenious acid 4 percent (poison), or sodium fluoride 8 percent (poison), may be substituted, and the postassium acetate reduced to a concentration of 2 percent. If glycerol is not available, propylene glycol is a satisfactory substitute.

b. The Klotz Method:

Klotz I Solution

Sodium sulfate	385.0 gm
Sodium bicarbonate	351.0 gm
Sodium chloride	317.0 gm
Potassium nitrate	657.0 gm
Potassium sulfate	45.0 gm

Chloral hydrate	1750.0 ml
Formalin	1750 ml
Distilled water—sufficient to make	35,000.0 ml

Klotz II Solution

Sodium sulfate	193.0 gm
Sodium bicarbonate	175.0 gm
Sodium chloride	159.0 gm
Potassium nitrate	328.0 gm
Potassium sulfate	23.0 gm
Chloral hydrate	350.0 gm
Formalin	175.0 ml
Distilled water—sufficient to make	35,000.0 ml

Procedure:

Fix specimen for 1 to 5 days in Klotz I.
Wash in running water for 24 hours.
Place in several changes of Klotz II over a period of several weeks, or until the solution remains clear.
Mount in Klotz Solution II.

c. Solution for Use with Plastic Mounts:

(1) The wet mount in plastic permits better retention of color than any other gross mounting technique. Satisfactory fixation can be obtained with the hydrosulfite technique. (Bulletin of the International Association of Medical Museums, 32:117, 1951).

Solution for Tissue Fixation

Sodium phosphate, monobasic (a buffer)	89.1 gm
Sodium phosphate, diabasic (a buffer)	112.5 gm
Formaldehyde solution (40%) (5% in final solution)	950 ml
Distilled water—sufficient to make	19,000 ml

Solution for Color Restoration

First three components, same as above	
Sodium hydrosulfite	95.0 gm
Distilled water—sufficient to make	19,000.0 ml

(2) Procedure: The gross specimen should be fixed in the first solution for a minimum of 2 weeks, preferably 3 to 4 weeks. Precautions should be taken, including covering the bottom of the container with cotton to ensure contact of the solution with all surfaces.

152. Remarks

a. If primary fixation is defective (because of inadequate time or incomplete contact with solution) the color of the poorly fixed tissue will not be restored by the final mounting solution and the mounting fluid will become cloudy. Perfusion should be done when possible.

b. Attempt color restoration only with properly fixed specimens. If the specimen is fixed in 10 percent unbuffered formalin, the longer the specimen remains in the formalin solution, the poorer are the possibilities of restoring color.

c. Hydrosulfite restores reds as brighter hues than the Kaiserling technique.

d. Hydrosulfite deteriorates rapidly if exposed to air and the stock solution tends to deteriorate after 10 days.

e. Sections for histologic study can be taken from tissue fixed in the first solution, but fixation may take 2 to 4 times as long as 10 percent formalin.

f. After the hydrosulfite has restored the color, subsequent exposure to air will cause permanent fading. This means that the solution cannot be used in glass containers in which there must be a large air space. It also explains why all bubbles must be removed and the hydrosulfite solution introduced only when the box is to be permanently sealed.

g. Because of the danger of color loss, special precautions should be taken in changing the hydrosulfite solution if it becomes cloudy. The simplest way is to introduce the fluid through a narrow tube and withdraw it through another tube at the same time, keeping the overall level of fluid constant.

h. To minimize the possibility of cloudy solutions, friable specimens may be coated with gelatin.

i. The mount should be viewed by incandescent rather than fluorescent light, for the fluorescent spectrum does not possess the reds and oranges necessary to impart "natural" color.

j. Melanin and bile pigment usually discolor the mounting solution.

k. The hydrosulfite is somewhat difficult to get into solution and may cause the fluid to be cloudy for several hours.

l. When a specimen is sent to a central museum, make a note on the jar and in the protocol of the exact procedure used for fixation, restoration of color, and final preservation.

m. Some laboratories will find it more convenient to ship the specimens, after primary fixation, to the central museum, where color restoration will be carried out.

n. Plastic jars are the containers of choice for museum specimens. The container must be large enough for the specimen without distortion. If benzyl benzoate or oil of wintergreen is used as mounting fluids, then glass jars must be used because these substances dissolve plastic. Plastic bags can be used as containers, but care must be used in packing and shipping so as not to distort the specimen.

o. The following manual can be referred to for additional information concerning museum specimens: "Methods of Preparing Pathologic Specimens for Storage and Shipment" (TM 8-340/NAVMED P-5083/AFM 160-28/VA IB 11-13).

153. Special Instructions Regarding Members of the US Military Academy Class of 1956

a. The US Military Academy class of 1956 has been the subject of much research and study regarding the relationship of blood lipoproteins in cardiovascular study. This study embraces about 475 subjects, and it is intended that it will continue for 20 or more years, and it should provide information regarding the relationship of lipoproteins, cholesterol, and phospholipids to the occurrence of atherosclerotic heart disease.

b. Much clinical data has already accumulated on these individuals. It is essential in case of death in any one of these individuals, that a very careful postmortem examination be performed. The autopsy investigation is very important and it is essential to the successful completion of this study. If the examination is incomplete, or there is failure to carry out these instructions, it means that the chance for a correlation of a large amount of clinical data with the postmortem findings is lost forever.

c. These cases are identified by a special folder in their health records. In such cases, it is essential that the heart and the aorta be opened in the appropriate way and maintained intact. The specimen should be fixed in neutral formalin using approximately 10 times the amount of tissue mass. The formaldehyde should be changed in the first few hours, and every effort made to ensure proper fixation. A routine section of the myocardium should be taken. The specimen should be packaged in a separate container and sent with the remaining autopsy specimens to the Armed Forces Institute of Pathology, ATTN: Cardiovascular Pathology Department, Washington, DC 20306. This applies to only those cases under study and embracing the US Military Academy Class of 1956.

d. A careful evaluation of the blood vessels, other than those of the heart and aorta, should be made at the time of postmortem examination. Specimens should be taken from vessels showing significant pathologic changes, and these specimens should be appropriately labeled and identified.

e. The success of this investigation, embracing years of clinical work, is dependent upon careful anatomical study and the proper collection and securing of specimens.

APPENDIX A
REFERENCES

1. Joint Army, Navy and Air Force Directives:

AR 15-97 BUMEDINST 6510.6A AFT 161-41	Joint Committee on Aviation Pathology
AR 40-31 BUMEDINST 6510.2E AFR 160-55	The Armed Forces Institute of Pathology and Armed Forces Histopathology Centers
AR 40-441 BUMEDINST 6200.1D AFR 161-40	Joint Utilization of Certain Armed Forces Medical Laboratory Facilities
AR 638-42 BUMEDINST 5360.1B AFR 143-4	Care and Disposition of Remains When Multiple Deaths of Members of Two or More Services Occur as a Result of Disaster of Major Accident
FM 10-63 NAVMED P-5016 AFM 143-3	Handling of Deceased Personnel in Theaters of Operations

2. Army Directives:

AR 40-2	Army Medical Treatment Facilities: General Administration
AR 40-21	Medical Aspects of Army Aircraft Accident Investigation
AR 40-400	Patient Administration
AR 385-40	Accident Reporting and Records
AR 600-10	Army Casualty System
AR 600-33	Line of Duty Determinations
AR 638-30	Graves Registration Organization and Functions in Support of Major Military Operations
AR 638-40	Care and Disposition of Remains

3. Navy Directives:

Manual of Medical Department:

Chapter 17	Deaths
Article 17-7	Reporting Deaths of Civilian Authorities
Article 17-24	Post-Mortem Examinations and Autopsies
Article 17-25	Relations with Civil Authorities
BUMEDINST 6510.6A	Aviation Pathology Program
OPNAVINST 3750.6K	Navy Aircraft Accident, Incident, and Ground Accident Reporting Procedures
BUMEDINST 6510.8B	Reference Laboratories in Automatic and Clinical Pathology

4. Air Force Directives:

AFM 127-1	Aircraft Accident Prevention and Investigation
AFM 127-2	Air Force Accident/Incident Reporting
AFM 143-1	Mortuary Affairs
AFM 160-20	Medical Treatment Facilities
AFR 35-67	Line-of-Duty and Misconduct Determinations and Investigations
AFR 127-4	Investigation and Reporting Air Force Mishaps
AFR 160-109	Medical Investigation of Aircraft Accident Fatalities

5. Miscellaneous Publications:

Adams, J. R., and Mader, R. D.; *Autopsy*. Year Book Medical Publishers, Inc., Chicago, 1976.

Adelson, L.; *The Pathology of Homicide*. Charles C Thomas, Publisher, Springfield, 1974.

Camps, F. E. (Ed.); *Gradwohl's Legal Medicine*, third edition Year Book Medical Publications, Inc., Chicago, 1976.

Kissane, J. M. and Smith, M. G.; *Pathology of Infancy and Childhood*. The C. V. Mosby Co., St. Louis, 1975.

Lennettee, E. H., Spaulding, E. H., and Truant, J. P.; *Manual of Clinical Microbiology*, second edition, American Society for Microbiology, Washington, DC, 1974.

Ludwig, J.; *Current Methods of Autopsy Practice*, second edition, W.B. Saunders Co., Philadelphia, London, Toronto, 1979.

Luna, L. G. (Ed.); *Manual of Histologic Staining Methods of the Armed Forces Institute of Pathology*, third edition, McGraw-Hill Book Co., New York Toronto, London, Sydney, 1098.

Morison, J. E.; *Foetal and Neonatal Pathology*, Butterworth and C., London, 1970.

Potter, E. L. and Craig, J. M.; *Pathology of the Fetus and the Infant*, third edition, Year Book Medical Publishers, Inc., Chicago, 1975.

Rezek, P. R. and Millard, M.; *Autopsy Pathology*. Charles C Thomas, Publisher, Springfield, 1963.

Spitz, W. U. and Fisher, R. S. (Eds.); *Medicolegal Investigation of Death*, second edition, Charles C Thomas, Publishers, Springfield, 1980.

Trump, B. F. and Jones R. T.; *Diagnostic Electron Microscopy*, Vol. 1, John Wiley, New York, 1978, p. 118.

Yunis, J. J.; *Human Chromosome Methodology*, second edition, Academic Press, Inc., New York, San Francisco, London, 1974.

APPENDIX B
EQUIPMENT AND SUPPLIES

1. Autopsy Room

The autopsy room should have ventilation, light, good artificial illumination, and gas. In using artificial light, care should be taken that the colors are not misrendered. A sewer drain and tap water outlet to which a hose is attached should be available. The floor and walls should be made of material that is easily cleaned and washed.

2. Instruments

The following instruments are recommended for the proper performance of an autopsy.

Standard items

Surgical Instrument Set, Postmortem ..... ea 1
Chest, Medical Instrument and Supply Set, Field No. 3,30 in. long by 18 in. wide by 10 in deep, Empty ..... ea 1
Knife, Craftsman's 5 in ..... ea 1
Forceps, Tissue, Russian, 6 in ..... ea 1
Chisel, Bone, 5 in ..... ea 1
Forceps, Bone Cutting, Straight, Liston, 8¾ in. ..... ea 1
Ronguer, Curved, Hartmann, 7¼ in. ..... ea 1
Forceps, Dressing, Straight, Rankin, 5½ in. ..... ea 1
Forceps, Hemostatic, Straight, Rankin, 6¼ in. ..... ea 1
Forceps, Tissue, Tweezers Type, Straight, 5½ in. ..... ea 1
Mallet, Autopsy, Metal, with hook ..... ea 1
Blade, Surgical Knife, Detachable No. 21, 6s ..... pkg 2
Handle, Surgical Knife, Detachable Blade No. 4 ..... ea 2
Needle, Suture, Postmortem, Half Curved, Cutting Edge, 5 in ..... ea 1
Probe, General Operating, 10 in. ..... ea 1
Saw, Amputating, Satterlee, 8 in. blade ..... ea 1
Scissors, General Surgical, Straight, Mayo, 6¾ in. ..... ea 1
Scissors, Enterotomy, 8 in. ..... ea 1
Scissors, Iris, Angular, 4½ in. ..... ea 1
Scissors, General Surgical, Straight, 7 in. ..... ea 1
Scissors, General Surgical, Straight, Double Shape, 5¼ in. long, 1¾ in. cut ..... ea 1
Scales, Weighing, Commercial, Autopsy ..... ea 1
Rule, Anatomical, Transparent, 18 in. ..... ea 1
Knife, Slicing, Carbon Steel Blade, 16 in. long clear of Handle ..... ea 1
Saw, Bone-Cutting, Autopsy, Stryker, 110 volts, ac-dc, with one arbor, blade and electric cord ..... ea 1
Bag, cellophane, Pathological Specimen, Polyethylene lined, 4 x 6 in. ..... ea 1
Bag, cellophane, Pathological Specimen, Polyethylene lined, 6 x 8 in. ..... ea 1
Bag, cellophane, Pathological Specimen, Polyethylene lined, 8 x 10 in. ..... ea 1
Bag, cellophane, Pathological Specimen, Polyethylene lined, 12 x 10 in. ..... ea 1
Sealing Iron, Electric Pathological Specimen, Bag, 110 volts; ac, complete with cord ..... ea 1

Non-standard items

Chisel, Virchow, skull opening (for Autopsy Kit) ..... ea 1
Knife, Postmortem, full section, 18 in. cutting edge, hollow ground (for Autopsy Kit) ..... ea 1
Councilman's Bone Cutting Forceps, 15 in., Mortise lock ..... ea 1

APPENDIX C
TABLES OF AVERAGE WEIGHTS AND MEASUREMENTS

*Table 2. Weight and Measurements of Various Organs in Adults**

Organ	*Weight in grams*	*Measurements in centimeters*	
Brain:			
Male	1100–1700 (average 1400)	Sagittal diameter, 15–17	
Female	1050–1550 (average 1275)	Vertical diameter, 12.5	
Spinal Cord	Average, 27	Length, 45	
		Frontal	*Sagittal*
Cervical		1.3–1.4	Average, 0.9
Thoracic		Average, 1	Average, 0.8
Lumbar		Average, 1.2	Average, 0.9
Pineal Gland	Average, 0.2		
Heart and Vessels:			
Male	270–360 (average 300)		
Female	200–280 (average 250)		
		Range	*Average*
Left ventricle muscle			1.5
Right ventricle muscle			0.5
Auricular muscle			0.2
Mitral valve		8–10.5	10.0
Aortic valve		6–7.5	7.5
Pulmonary valve		7–9	8.5
Tricuspid valve		10–12.5	12.0
Pulmonary artery			8.0
Aorta:			
Ascending			7.4
Thoracic			5.0
Abdominal			4.0
Lungs:			
Right	360–570 (average 450)		
Left	325–480 (average 375)		
Liver	1500–1800 (average 1650)	25–30 by 19–21 by 6–9	
Spleen:		12–14 by 8–9 by 3–4	
16–20 years	150–200 (average 170)		
20–65 years	Average, 155		
80 years and over	Average, 100		
Pancreas	60–135 (average 110)	23 by 4.5 by 3.8	
Kidneys:		11–12 by 5–6 by 3–4	
Male	230–440 (average 313)		
Female	240–350(average 288)		
Prostate:		3.6 by 2.8 by 1.9	
20–30 years	Average, 15		
51–60 years	Average, 20		
51–80 years	Average, 40		
Seminal vesicles		4.1–4.5 by 1.6–1.8 by 0.9	
Uterus:			
Virgin	33–41 (average 35)	7.8–8.1 by 3.4–4.5 by 1.8–2.7	
After pregnancy	102–117 (average 110)	8.7–9.4 by 5.4–6.1 by 3.2–3.6	
Cervix (virgin)		2.9–3.4 by 2.5 by 1.6–2	
Endocrines:			
Pituitary:		2.1 by 1.4 by 0.5	
10–20 years	Average, 0.56		
20–70 years	Average, 0.61		
Pregnancy	0.84–1.06 (average, 0.95)		
Thyroid	30–70 (average, 40)	5–7 by 3–4 by 1.5–2.5	

*Table 2 is reprinted from *Normal Values in Clinical Medicine*, 1949 Edition, by permission of F. William Sunderman and Frederick Barner, the authors, and W. B. Saunders Company, Philadelphia and London, the publishers.

Table 2. Weight and Measurements of Various Organs in Adults—Continued

Organ	Weight in grams	Measurements in centimeters
Testis:		
Newborn		1 by 0.5 by 0.4
Puberty		3 by 2 by 1.6
Adult	20–27 (average 25)	4–5 by 2.5–3.5 by 2–2.7
Ovary:		
Virgin		4.1–5.2 by 2–2.7 by 1–1.1
After pregnancy	Average, 7	2.7–4.1 by 1.5 by 0.8
Adrenal	Average, 6	4.5 by 2.5–3.5 by 0.5
Parathyroids	0.12–0.18	0.3–0.6 by 0.2–0.4 by 0.05–0.2 (ea)
Thymus:		
Newborn	6.05–25.88 (average 13.98)	
1–9 months	6.74–34.10 (average 20.14)	
9–24 months	19.97–37.72 (average 26.60)	
6–25 years	Average, 25	
26–35 years	Average, 20	
36–65 years	Average, 16	
65 years and over	Average, 6	
Gastrointestinal tract:		
Esophagus		25
Duodenum		30
Small intestine		550–650
Colon		150–170

*Table 3. Average Weights and Measurements of Normal Organs**
(Infants and Children)

Age	Body weight M**	Body length	Heart	Lungs		Spleen	Liver	Kidneys		Brain
				right	left			right	left	
	kg	*cm*	*gm*	*gm*	*gm*	*gm*	*gm*	*gm*	*gm*	*gm*
Birth—3 days	3.4	49	17	21	18	8	78	13	14	335
3—7 days		49	18	24	22	9	96	14	14	358
1—3 weeks		52	19	29	26	10	123	15	15	382
3—5 weeks		52	20	31	27	12	127	16	16	413
5—7 weeks		53	21	32	28	13	133	19	18	422
7—9 weeks		55	23	32	29	13	136	19	18	489
3 months	6.5	56	23	35	30	14	140	20	19	516
4 months		59	27	37	33	16	160	22	21	540
5 months		61	29	38	35	16	188	25	25	644
6 months	8.5	62	31	42	39	17	200	26	25	660
7 months		65	34	49	41	19	227	30	30	691
8 months		65	37	52	45	20	254	31	30	714
9 months	9.8	67	37	53	47	20	260	31	30	750
10 months		69	39	54	51	22	274	32	31	809
11 months		70	40	59	53	25	277	34	33	852
12 months	10.8	73	44	64	57	26	288	36	35	925
14 months		74	45	66	60	26	304	36	35	944
16 months		77	48	72	64	28	331	39	39	1,010
18 months	12.2	78	52	72	65	30	345	40	43	1,042
20 months		79	56	80	74	30	370	43	44	1,050
22 months		82	56	83	75	33	380	44	44	1,059
24 months	13.2	84	56	88	76	33	394	47	46	1,064
3 years	15.2	88	59	89	77	37	418	48	49	1,141

Table 3. Average Weights and Measurements of Normal Organs (Infants and Children)—Continued*

Age	Body weight M**	Body length	Heart	Lungs		Spleen	Liver	Kidneys		Brain
				right	left			right	left	
	kg	*cm*	*gm*	*gm*	*gm*	*gm*	*gm*	*gm*	*gm*	*gm*
4 years	17.3	99	73	90	85	39	516	58	56	1,191
5 years	19-4	106	85	107	104	47	596	65	64	1,237
6 years	21.9	109	94	121	122	58	642	68	67	1,243
7 years	24.6	113	100	130	123	66	680	69	70	1,263
8 years	27.7	119	110	150	140	69	736	74	75	1,273
9 years	31.0	125	115	174	152	73	756	82	83	1,275
10 years	34.8	130	116	177	166	85	852	92	95	1,290
11 years	38.8	135	122	201	190	87	909	94	95	1,320
12 years	43.2	139	124			93	936	95	96	1,351

*Table 3 is reprinted from *American Journal of Pathology 9:59, 1933,* by permission of the publisher.
**Means

***Table 4. Organ Weight in Grams, Body Length and Fetal Age in Relation to Body Weight (Chicago Lying-in Hospital)**

Organ		Body Weight 500–999	1,000–1,499	1,500–1,999	2,000–2,499	2,500–2,999	3,000–3,499	3,500–3,999	4,000–4,499	4,500+
Brain	X	109	180	250	308	359	403	421	424	406
	SD	45	53	55	76	67	60	72	55	56
	N	267	181	148	149	127	138	76	41	28
Lungs	X	18	27	38	44	49	55	58	66	74
	SD	6	7	10	10	11	13	12	15	16
	N	256	130	108	83	69	88	51	20	21
Heart	X	6	9	13	15	19	21	23	28	36
	SD	2	5	5	5	5	4	5	5	10
	N	368	257	226	198	186	213	127	58	41
Liver	X	39	60	76	98	127	155	178	215	275
	SD	11	16	17	25	31	33	38	36	54
	N	376	269	232	207	188	226	135	59	43
Spleen	X	2	3	5	7	9	10	12	14	17
	SD	2	3	3	5	4	4	5	5	7
	N	367	267	228	211	187	220	134	61	43
Kidneys	X	7	12	16	20	23	25	28	31	33
	SD	3	4	4	4	5	5	7	7	8
	N	340	220	219	186	171	204	121	54	37
Adr-enals	X	3	4	5	6	8	10	11	12	15
	SD	1	1	2	2	3	3	3	4	4
	N	356	262	227	205	184	216	128	60	36
Thymus	X	2	4	7	8	9	11	13	14	17
	SD	1	2	3	4	4	4	5	5	6
	N	366	262	228	208	188	223	125	59	42
Thyroid	X	0.8	0.8	0.9	1.0	1.3	1.6	1.7	1.9	2.3
	SD	0.7	0.8	0.6	0.7	0.9	0.9	0.8	0.9	1.1
	N	255	177	153	141	128	148	84	45	34
Pan-creas	X	1.0	1.4	2.0	2.3	3.0	3.5	4.0	4.6	6.0
	SD	1.3	1.0	1.3	1.1	1.2	1.2	1.5	2.1	6.2
	N	245	170	127	143	125	131	85	45	34

**Table 4. Organ Weight in Grams, Body Length and Fetal Age in Relation to Body Weight (Chicago Lying-in Hospital)*—Continued

					Length (cm)					
Crown-heel	X	33	39	43	47	50	52	53	54	56
	SD	3	2	3	2	2	2	2	2	2
	N	386	276	241	217	191	230	136	63	43
Crown-heel	X	22	26	29	32	34	36	37	38	40
	SD	2	2	2	2	2	2	2	2	2
	N	386	275	241	217	187	230	134	63	42
					Fetal Age (1st Day LMP to Birth)					
Day	X	180	208	230	250	270	276	281	281	283
	SD	23	23	24	28	22	20	16	12	12
	N	220	181	153	124	111	126	56	28	25

*Based on 1,878 autopsies of fetuses and infants less than 2 hours of age who were not macerated, malformed, erythroblastotic or one of twins. Also excluded were lungs with pneumonia, hyaline membranes and large amounts of amniotic fluid.
X = mean weight; SD = standard deviation; N = number; LMP = last menstrual period.

**From Potter, E. L. and Craig, J. M.: *Pathology of the Fetus and Infant* third edition. Copyright © 1975 by Year Book Medical Publishers, Inc., Chicago. Used by permission.

Table 5. Criteria for Classification as to Period of Development

Abortion:

1. Length, less than 28 cm.
2. Weight, less than 500 gm.
3. Gestation, less than 22 weeks.

Immature:

1. Length, from 28 to 34.9 cm.
2. Weight, from 500 to 999 gm.
3. Gestation, from 22 through 28 weeks.

Premature:

1. Length, from 35 to 46.9 cm.
2. Weight, 1000 to 2499 gm.
3. Gestation, from 29 through 38 weeks.

Term:

1. Length, greater than 47 cm.
2. Weight, greater than 2500 gm.
3. Gestation, from 39 through 42 weeks.

Postmature: Gestation, more than 42 weeks.

INDEX

	Paragraph	Page
Abdomen:		
Abdominal viscera	69	36
Peritoneal cavity and abdominal organs	12, 91*b*	5, 40
Primary incision	10	5
Adrenal glands	35,77	25, 36
Aircraft fatality	87-91	40
Air embolism	23*c*	17
Air embolism, aircraft fatality	91*b*	40
Aorta	36*a*, 78	25, 36
Arm and hand	64	35
Authorization for autopsy:		
Consent	6, 7	1, 2
Pediatric	81	38
Responsible persons	6	1
Biochemical and toxicological studies (aircraft)	91*b*	40
Bones, cartilage, joints	55	32
Bone marrow	55, 63	32, 34
Brain:		
Examination	46	26
Aircraft fatality	91*b*	40
Infant	84	38
Breasts and Genitalia, Female	45	26
Bronchi	24	17
Calvarium	57	34
Carotid arteries, dural sinuses, gasserian ganglia	47*c*	29
Cartilage	55	32
Chemistry, postmortem	120	61
Blood	121	61
Vitreous humor	122	62
Cisternal puncture	52	31
Cultures	96-103	51-53
Cytogenetic analysis	115, 116	60
Digits	58	34
Directives, Army, Navy, Air Force:		
Aircraft accident	87	40
Diving Fatalities	138	71
Ducts	31, 72	22, 36
Duodenum	32, 71	22, 36
Dural sinuses, carotid arteries, gasserian ganglia	47*c*	29
Ear, middle, and temporal bone	49, 50	30
Electron microscopy	117-119	60-61
Epididymides and testes	43, 79*g*	25, 37
Equipment and supplies	App B	B-1
Esophagus	32, 79*a*	22, 36
Eyes	51, 91*b*	31, 40
Extremities	59	34
Face	65	35
Fetuses	80-86	38-39

	Paragraph	Page
Forms:		
Aircraft Accident, Autopsy Report, DD Form 1322	91*a*	40
Clinical Record-Autopsy Protocol, Standard Form 503	6*e*, 92	2, 49
Clinical Record—Authorization for Autopsy Examination, Standard Form 523	6	1
Medical Record—Authorization for Tissue Donation, Standard Form 523B	7	2
Medicolegal autopsy	140, 143	73, 74
Toxicological Examination—Request and Report, DD Form 1323	113	57
Formulae for fixatives:		
Electron microscopy	119	61
Museum specimens	151	76
Routine autopsy	146	75
Fungi	100	52
Gallbladder	31, 72	22, 36
Gasserian ganglia	47*c*	29
Genitalia and Breasts, female:		
Examination	45, 79*i*	26, 37
Genitalia, external	67	35
Genitalia, external, male	67	35
Great Vessels, Pericardium, Heart	91*b*	40
Hand	64	35
Heart:		
Air embolism	23*c*	17
Aircraft fatality	91*b*	40
Cardiac conditions	23	17
Histologic examination	22	16
Methods of opening	21	9
Histologic examination	22, 91*b*. 94	16, 40, 50
Histopathologic study	91*b*	40
Hypopharnyx	26	19
Immunological studies	109, 110	55
Infants	80–86	38–39
Intestine and mesentery	28, 70, 91*b*	20, 36, 40
Joints	55	32
Kidneys	38, 79*b*	25, 37
Knee	60	34
Larnynx, pharnyx, hypopharynx, tongue, thyroid and parathyroid	26, 66, 91*b*, 139*a*	19, 35, 40, 72
Liver	34. 72, 91*b*	22, 36, 40
Lungs	25, 91*b*	17, 40
Lymph nodes	30	22
Mediastinum	18	6
Medicolegal	124–143	64–74
Mesentery	28, 70	20, 36
Microorganisms, examination	96–103	51–53
Museum, Preservation of Tissues	149, 150	76
Fixation, Methods and Solutions	151, 152	76, 77
Nasopharynx	48	29
Neuromuscular apparatus	54	32
Oral cavity	27	20

	Paragraph	Page
Pancreas	33, 75	22, 36
Paranasal sinuses	48	29
Parathyroid	26	19
Pericardium-pericardial cavity	17, 91*b*	6, 40
Peripheral nerves	54	32
Peritoneal cavity	12, 13	5, 6
Pharynx	26	19
Photography	123, 131	63, 66
Pituitary gland	47*b*	29
Placenta and umbilical cord	85	39
Pleural cavities	15	6
Porta hepatis	31, 72	22, 36
Prostate	40, 79*d*	25, 37
Rabies	105–108	53–54
Radioactive cadavers and specimens:		
Precautions in handling	111	55
Disposition and storage	112	56
Records and reports (see also Forms)	90–95	40-51
Rectum and sigmoid	41, 79*e*	25, 37
References	App A	A-1
Respiratory tract	91*b*	40
Retroperitoneal structures in the midline	76	36
Ribs	56	34
Seminal vesicles	42	25
Shipment of specimens	5	1
Sigmoid	41	25
Skin	11	5
Skull	47	29
Smears	101	52
Spleen, splenic vessels	29, 73	22, 36
Spinal cord:		
Aircraft fatality	91*b*	40
Infant	84*d*	38
Removal and examination	53	31
Spinal fluid	52	31
Postmortem chemistry	120	61
Sternoclavicular joints	61	34
Stomach	32, 71, 91*b*	22, 36, 40
Tables of average weights and measurements	App C	C-1
Temporal bone and middle ear	49, 50	30
Testes	43, 79*g*	25, 37
Thorax	10, 14–16	5, 6
Thyroid	26	19
Tongue	26, 139*a*	19, 72
Toxicological studies	91*b*	40
Specimens for toxicological examination	113-114,136	57, 70
Trachea	24, 91*b*	17, 40
Urinary bladder	39	25
Urinary tract	37	25
US Military Academy Class of 1956, special study	153	78
Vas deferens	44, 79*h*	26, 37

	Paragraph	*Page*
Vena cava	36*b*, 78	25, 36
Vertebrae	62	34
Viral diseases, special studies	104–108	53–54
Visera:		
Dissection and examination	19, 20	7
Organ by organ removal	21–65	9–35
Removal en masse	66–79	35–36

The proponent agency for this regulation is the Office of the Surgeon General. Users are invited to send comments and suggested improvements on DA Form 2028 (Recommended Changes to Publications and Blank Forms) direct to HQDA (DASG-PSC-L) WASH DC 20310.

By Order of the Secretaries of the Army, the Navy, and the Air Force:

E. C. MEYER
General, United States Army
Chief of Staff

Official:

J. C. PENNINGTON
Major General, United States Army
The Adjutant General

H. A. SPARKS
Rear Admiral, MC, USN
Acting Chief, Bureau of Medicine & Surgery

LEW ALLEN, JR., *General USAF*
Chief of Staff

Official:

VAN L. CRAWFORD, JR., Colonel, USAF
Director of Administration

DISTRIBUTION:

To be distributed in accordance with DA Form 12-34B requirements for Autopsy.

INTRODUCTION AND INSTRUCTIONS

The MedicoLegal Autopsy Report Form is designed to:

(1) permit a check list recording of medicolegal data in detail
(2) allow the placement of all data into a computer for automatic data processing

This form has 15 pages (1-11 are demographic and medical; 12-15 are contributing factors including environmental). Seventeen pages of anatomical diagrams are provided for optional use.

The form should eliminate loss of data including clerical and coding coverage and yet be medically and legally acceptable. Space is provided for "written in" data and additional sheets may be attached. (The numbers appearing in parenthesis are for data processing only and should be ignored by the pathologist).

A COMPLETE REPORT IS REQUIRED. A CHECK MARK MUST BE MADE FOR EACH ENTRY INCLUDING NOT EXAMINED IF NO STUDY WAS MADE.

The following are examples and notes to be observed:

(A) Please include Zip code with address.
(B) Date/Time should be numerals, based on the 24 hour clock.
Example – January 12, 1969 at 1:15 a.m. would be 01/12/69/0115;
June 9, 1969 at 1:15 p.m. would be 06/09/69/1315.
(C) Check marks (✓) should be appropriately and legibly placed.
Example – An appendix examined and found to be normal would appear as:

APPENDIX: (24)__U__ Present-Not Examined (25)_✓N_ Normal (26)__A__ Abnormal (27)__S__ Surg Absence.

The larynx which reveals edema and other unspecified conditions, would be indicated as: Larynx (24)__U__ Not Exam (25)__N__ Normal (26) _✓E_ Edema (27)__A__ Surg Absence (28)_✓O_ Other. Appropriate description of "other" would be made in Remarks, section under NECK ORGANS.

(D) For recording the degree of injury, one of two formats appear, (1) the check-mark type (__0__1__2__3__4), or the write-in type (__°).
(E) The use of diagrams is optional to the extent that, only the pertinent ones need to be completed.

Comments and/or suggestions as to the improvement of this form should be directed to:

REGISTRAR – Registry of Accident Pathology
Armed Forces Institute of Pathology
Washington, D.C. 20305

Figure 25 (1)

MEDICOLEGAL AUTOPSY REPORT

For use of this form, see TM 8-300; the proponent agency is the Office of The Surgeon General.

(Attach additional sheets of 8½ x 11 paper as required.)

A

RESERVED: (2-9) _____

CASE NO. (10-19) _____ LAST NAME (20-36) _____ FIRST NAME (37-45) _____ MI (46) _____ AUTOPSY NO. (47-56) _____

SOCIAL SECURITY NO.: (57-65) _____

ADDRESS

Street and No.: _____

City and State: _____

ZIP Code _____ (66-70)

ESTIMATED DATE & TIME OF DEATH

Mo Day Yr Time: (24 Hr Clock)

/ / / (71-80)

B

PLACE OF DEATH

Location: _____

City and State: _____

ZIP Code _____ (10-14)

DATE & TIME PRONOUNCED DEAD

Mo Day Yr Time: (24 Hr Clock)

/ / / (15-24)

RACE: (25) ___C___ Caucasian ___N___ Negro ___I___ Indian ___M___ Mongolian ___Ø___ Other _____ ___U___ Unknown

SEX: (26) ___M___ Male ___F___ Female ___U___ Unknown AGE: (27-29) _____ Yrs. (30-31) _____ Mos.

MARITAL STATUS: (32) ___M___ Married ___S___ Single ___W___ Widowed ___D___ Divorced ___U___ Unknown

OCCUPATION: (Specify) _____

Occupational Category: (33) ___1___ Professional ___2___ Skilled ___3___ Unskilled ___4___ Student ___5___ Military ___6___ Retired ___7___ Unemployed ___8___ Other: ___9___ Unknown

MANNER OF DEATH (From Death Certificate)

(34) ___A___ Accident ___H___ Homicide ___S___ Suicide ___N___ Natural ___U___ Undetermined

PLACE OF INJURY

Location: _____

City and State: _____

ZIP Code _____ (35-39)

DATE & TIME OF INJURY

MO Day Yr Time: (24 Hr Clock)

/ / / (40-49)

METHOD OF OBTAINING REPORT: (50) ___1___ Autopsy (51) ___2___ Inspection (52) ___3___ Inquiry

WHERE PERFORMED

Location: _____

City and State: _____

ZIP Code _____ (53-57)

DATE & TIME PERFORMED

Mo Day Yr Time: (24 Hr Clock)

/ / / (58-67)

PROSECTOR'S OR EXAMINER'S Name: _____

Credentials: (68) ___N___ Not a Physician ___Ø___ Physician (Other Than Pathologist) ___P___ Pathologost (Not Boarded) ___B___ Pathologist (Board Certified)

Type of Board: (69) ___N___ None (70) ___A___ Anatomic (71) ___C___ Clinical (72) ___F___ Forensic

WITNESS' Name(s): _____ (73) _____ _____ (74) _____

Identification: Enter proper code from this list in space provided beside each name.

___1___ Physician (Not Pathologist) ___2___ Pathologist (No Board) ___3___ Pathologist (Board Certified)

___4___ Policeman ___5___ Photographer ___6___ Recorder ___7___ Other: _____

DISPOSITION OF BODY: (75) ___B___ Buried ___C___ Cremated ___Ø___ Other: _____

C

CAUSE OF DEATH (From Death Certificate)

ICDA Code Diagnosis

(10-14) ___.___ Primary (1): _____

(15-19) ___.___ (2): _____

(20-24) ___.___ Contributing (1): _____

(25-29) ___.___ (2): _____

POLICE JURISDICTION: _____

INVESTIGATORS: _____

CASE NO. AUTOPSY NO.

EXTERNAL EXAMINATION

RIGIDITY

		Absent	Partially Developed	Fully Developed	
JAWS:	(30)	A	P	F	
UPPER EXTREMITIES:	(31)	A	P	F	
LOWER EXTREMITIES:	(32)	A	P	F	

Remarks: ____

LIVIDITY

		Absent	Fully Developed	Remarks
FRONT:	(33)	A	F	
BACK:	(34)	A	F	
UPPER:	(35)	A	F	
LOWER:	(36)	A	F	
LEFT:	(37)	A	F	
RIGHT:	(38)	A	F	

BODY MARKS: (39) N None (40) S Scars (41) T Tatoos (42) Ø Other: ____

Remarks: ____

PRESERVATION

(43) G Good (44) A Advanced Decomposition (45) E Early Decomposition (46) E Embalmed

Remarks: ____

BODY HABITUS

(47) N Normal Ø Obese S Slender E Emaciated X Undetermined

Weight of Body: (48-50) ____ lbs or (51-53) ____ kg Length of Body: (54-55) ____ in or (56-58) ____ cm

Remarks: ____

DIAGRAMS USED

(59) X None
(61) A Full Length Body – Ant & Post
(63) B Full Length Body – R & L Lat
(65) C Body With Skeleton – Ant & Post
(67) D Body With Skeleton – R & L Lat
(69) E Head, Neck – Ant, Post R & L Lat
(71) F Right & Left Hands – Palmar, Dorsal
(73) G Skull – Ant, Post, R & L Lat
(75) H Calvarium (Ext, Int), Base of Skull
(60) I Brain – R Lat, Sup, L Lat, Inf
(62) J Brain – Coronal Sections (Anterior)
(64) K Brain – Coronal Sections (Posterior)
(66) L Cerebellum, Medulla & Spinal Cord
(68) M Respiratory Sys, Cardiovascular Sys
(70) N Alimentary Sys, Biliary Sys
(72) Ø Hemopoietic Sys, Urinary Sys
(74) P Male/Female Reproductive Sys
(76) Q Endocrine (Thyroid, Adrenals, Pituitary)

OTHER PICTORIALS: (77) N None (78) X X-Rays (79) P Photos (80) Ø Other: ____

Remarks: ____

SPECIAL INSTRUCTIONS

Supplement with photographs where possible. Attach additional sheets of 8½ x 11 paper as required.

In each instance during external examination, specify exact location of the injury, abrasion, amputation, burn; and degree of contusion, discoloration, hemorrhage, whether pre-existing or acquired. Also give opinion as to possible cause of injury.

In each instance during skeletal examination, specify exact location and type of fracture or dislocation. X-Rays are to be used where possible. Give opinion as to probable direction and magnitude of force causing injury. Available skeletal diagrams should be used.

INTERNAL EXAMINATION

THE DEGREE OF INJURY SHOULD BE ASSESSED AS: 1 – MILD (Insignificant); 2 – MODERATE; 3 – SEVERE (Potentially Fatal); OR 4 – EXTREME (Obviously Fatal). ORGANS SHOWING SIGNIFICANT PATHOLOGIC CHANGES SHOULD BE PRESERVED.
(Attach additional sheets of 8½ x 11 paper as required.)

SKULL

(10) ___U___ Not Examined

If examined, enter codes 1, 2, 3 or 4 as described above on proper line to indicate location and type of injury, or enter 0 under "NONE" if there is no injury.

TYPE OF FRACTURE

LOCATION	None	Linear	Depressed	Other	Description
CALVARIUM:					
Left:	(11) ___	(12) ___	(13) ___	(14) ___	___
Right:	(15) ___	(16) ___	(17) ___	(18) ___	___
ANTERIOR FOSSA:					
Left:	(19) ___	(20) ___	(21) ___	(22) ___	___
Right:	(23) ___	(24) ___	(25) ___	(26) ___	___
MIDDLE FOSSA:					
Left:	(27) ___	(28) ___	(29) ___	(30) ___	___
Right:	(31) ___	(32) ___	(33) ___	(34) ___	___
POSTERIOR FOSSA:					
Left:	(35) ___	(36) ___	(37) ___	(38) ___	___
Right:	(39) ___	(40) ___	(41) ___	(42) ___	___

OTHER LESIONS: ___

BRAIN

The whole brain should be preserved in 10% N. Formalin after tissue is removed for Toxicology.

APPEARANCE: (43) ___U___ Not Examined ___N___ Normal ___A___ Abnormal WEIGHT: (44-47) ___ gms

ABNORMALITIES: Use a check (√) to indicate location and type .

	Contusion	Laceration	Pre-existing Lesion	Remarks
CEREBRUM:				
Left:	(48) C	(49) L	(50) P	___
Right:	(51) C	(52) L	(53) P	___
CEREBELLUM:				
Left:	(54) C	(55) L	(56) P	___
Right:	(57) C	(58) L	(59) P	___
MID BRAIN:				
Left:	(60) C	(61) L	(62) P	___
Right:	(63) C	(64) L	(65) P	___

Remarks: ___

SWELLING:	(66)	0	1	2	3	4
ANEURYSM:	(67)	0	1	2	3	4
ATHEROSCLEROSIS:	(68)	0	1	2	3	4
OTHER ABNORMALITY:	(69)	0 Absent		1 present		

HEMORRHAGE: (Record volume in cc)

		Left		Right	
Extra Dural:	(10-12)	___	(13-15)	___	___
Sub Dural:	(16-18)	___	(19-21)	___	___
Sub Arachnoid:	(22-24)	___	(25-27)	___	___
Intracerebral:	(28-30)	___	(31-33)	___	___
Intraventricular:	(34-36)	___	(37-39)	___	___

Remarks ___

Figure 25 (4)

CASE NO. AUTOPSY NO.

INTERNAL (continued)

PITUITARY

(40)__U__ Not Examined (41)__N__ Normal (42)__T__ Trauma (43)__Ø__ Other Pathology:

Remarks: _____

SPINAL CORD

(44)__U__ Not Examined (45)__N__ Normal (46)__ Pre-existing Lesion (47)__L__ Lacerated

(48)__C__ Contused (49)__T__ Transected Remarks: _____

MIDDLE AND INNER EAR

LEFT: (50)__U__ Not Examined (51)__N__ Normal (52)__P__ Pre-existing Lesion (53)__H__ Hemorrhage

RIGHT: (54)__U__ Not Examined (55)__N__ Normal (56)__P__ Pre-existing Lesion (57)__H__ Hemorrhage

Remarks _____

EYES

	Not Examined	Normal	Trauma	Cataract	Opacity (°)	Other
LEFT:	(58)__U__	(59)__N__	(60)__T__	(61)__C__	(62)__	(63)__Ø__
RIGHT:	(64)__U__	(65)__N__	(66)__T__	(67)__C__	(68)__	(69)__Ø__

Remarks: _____

F

ORAL CAVITY

TONGUE: (10)__U__ Not Examined (11)__N__ Normal (12)__L__ Lacerated (13)__Ø__ Other:

FRACTURES: (14)__U__ Not Examined __N__ None Present

Maxilla: (15)__L__ Left (16)__R__ Right Mandible: (17)__L__ Left (18)__R__ Right

Dental: (19)__U__ Upper (20)__L__ Lower Number of Teeth Fractured: _____

PLATES: (21)__U__ Upper (22)__L__ Lower (23)__N__ None

Remarks: _____

NECK ORGANS

LARYNX: (24)__U__ Not Exam (25)__N__ Normal (26)__E__ Edema (27)__A__ Surg Absence (28)__Ø__ Other

Hemorrhage: (Record Degree) (29)__1__ __2__ __3__ __4__

FRACTURES: (30)__U__ Not Exam (31)__N__ None (32)__C__ Cricoid (33)__T__ Thyroid (34)__H__ Hyoid

THYMUS: (35)__U__ Not Exam (36)__N__ Not Identified (37)__P__ Prev Path (38)__T__ Trauma

Weight: ____ gms

THYROID: (39)__U__ Not Exam (40)__N__ Normal (41)__P__ Pre-existing Lesion (42)__T__ Trauma

Weight: ____ gms

PARATHYROIDS: (43)__U__ Not Exam (44)__N__ Normal (45)__P__ Pre-existing Lesion (46)__T__ Trauma

Remarks _____

PLEURAL SPACE

(47) __U__ Not Examined __N__ Normal __A__ Abnormal

ABNORMALITIES:

	Adhesions	Pneumothorax	Hemothorax	Perforated Pleura	Other
Left:	(48)__1__	(49)__2__	(50)__3__	cc (51)__4__	(52)__5__
Right:	(53)__1__	(54)__2__	(55)__3__	cc (56)__4__	(57)__5__

Remarks: _____

Figure 25 (5)

CASE NO. AUTOPSY NO.

INTERNAL (continued)

CHEST WALL

(58) ____ U Not Examined ____ N Normal ____ A Abnormal

SOFT TISSUE INJURY: (59) ____ C Contusion (60) ____ Ø Other:

Size of Wound: Length (61-62) ____ in Width (63-64) ____ In

FRACTURES: (65) ____ N None (66) ____ L Left Rib Fx (67) ____ R Right Rib Fx

(68) ____ S Sternal (69) ____ W Unstable Chest Wall

Remarks: ____

TRACHEA

(70) ____ U Not Exam (71) ____ N Normal (72) ____ T Trauma (73) ____ P Tracheostomy (74) ____ B Blood

(75) ____ M Mucus (76) ____ V Vomitus/Food (77) ____ Ø Foreign Object:

Evidence of Smoke Inhalation? (78) ____ Y Yes ____ N No

Remarks: ____

G

LUNGS

(10) ____ U Not Examined ____ N Normal ____ A Abnormal

WEIGHT: Left (11-14) ____ gms Right (15-18) ____ gms

ABNORMALITIES: For each condition, check "L" for Left and "R" for Right as appropriate.

Aspirated Blood:	(19) ____ L	(20) ____ R	Laceration:	(21) ____ L	(22) ____ R
Aspirated Vomitus:	(23) ____ L	(24) ____ R	Perforation:	(25) ____ L	(26) ____ R
Aspiration Pneumonia:	(27) ____ L	(28) ____ R	Hemorrhage/Contusion:	(29) ____ L	(30) ____ R
Broncho Pneumonia:	(31) ____ L	(32) ____ R	Atelectasis:	(33) ____ L	(34) ____ R
Lobar Pneumonia:	(35) ____ L	(36) ____ R	Emphysema:	(37) ____ L	(38) ____ R
Edema:	(39) ____ L	(40) ____ R	Thromboembolism:	(41) ____ L	(42) ____ R
Other:	(43) ____ L	(44) ____ R			

Remarks ____

DIAPHRAGM

(45) ____ U Not Examined (46) ____ N Normal (47) ____ L Laceration (48) ____ Ø Other:

Remarks: ____

GREAT VESSELS

AORTA: (49) ____ U Not Examined ____ N Normal ____ A Abnormal

Aneurysm (Thoracic) (50) ____ 1 ____ 2 ____ 3 ____ 4 Aneurysm (Abdominal) (51) ____ 1 ____ 2 ____ 3 ____ 4

Atherosclerosis (52) ____ 1 ____ 2 ____ 3 ____ 4 Trauma (53) ____ 1 ____ 2 ____ 3 ____ 4

Remarks: ____

VENA CAVA: (54) ____ U Not Examined (55) ____ N Normal Trauma (56) ____ 1 ____ 2 ____ 3 ____ 4

Remarks:

OTHER MAJOR ARTERIES: (57) ____ U Not Examined (58) ____ N Normal Trauma (59) ____ 1 ____ 2 ____ 3 ____ 4

OTHER MAJOR VEINS: (60) ____ U Not Examined (61) ____ N Normal Trauma (62) ____ 1 ____ 2 ____ 3 ____ 4

Remarks: ____

HEART

(63) ____ U Not Exam (64) ____ N Normal (65) ____ E Air Embolism (66) ____ T Trauma (67) ____ P Pre-exist Lesion

(68) ____ V Valvular Disease WEIGHT: (69-72) ____ gms Remarks: ____

Figure 25 (6)

CASE NO. AUTOPSY NO.

INTERNAL (continued)

PERICARDIUM

H

(10) ___ U Not Examined (11) ___ N Normal (12) ___ P Pre-existing Lesion (13) ___ R Rupture
(14) ___ Ø Other: ___ Hemopericardium: (15-18) ___ cc
Remarks: ___

CORONARY VESSELS

(19) ___ U Not Examined ___ N Normal ___ A Abnormal
Assess Maximal Degree of Occlusion as: "1" – Minimum (less than 20%), "2" – Mild (from 20 to 50%), "3" – Moderate (from 50 to 80%) and "4" – Severe (from 80 to 100%).

CHART LOCATION AND DEGREE OF NARROWING

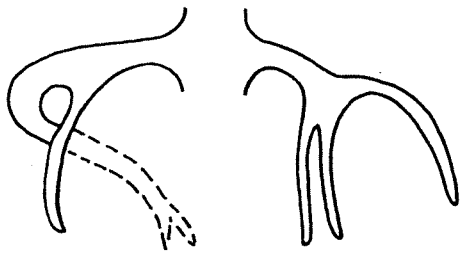

RIGHT: (20) ___ 0 ___ 1 ___ 2 ___ 3 ___ 4

LEFT MAIN: (21) ___ 0 ___ 1 ___ 2 ___ 3 ___ 4

LEFT DESCENDING: (22) ___ 0 ___ 1 ___ 2 ___ 3 ___ 4

LEFT CIRCUMFLEX: (23) ___ 0 ___ 1 ___ 2 ___ 3 ___ 4

Remarks: ___

MYOCARDIUM

(24) ___ U Not Examined (25) ___ N Normal (26) ___ T Trauma (27) ___ I Infarct (28) ___ Ø Other

TRAUMA:
(29) ___ C Contusion (30) ___ P Epicardial Laceration (31) ___ N Endocardial Laceration
(32) ___ R Rupture

MECHANISM OF TRAUMA: (33) ___ G Gunshot Wound (34) ___ R Rib Perforation
(35) ___ C Compression (36) ___ F Foreign Body Perforation

Remarks: (Include description of Mechanism) ___

INFARCT: Specify Location:
Classify as "Acute" (Less than 24 Hrs.), "Recent" (1 day to 1½ wk), "Healing" (over 2 wks.)

(37)	A Acute:	(38) 1 Focal	2 Moderate to Large	3 Massive
(39)	R Recent:	(40) 1 Focal	2 Moderate to Large	3 Massive
(41)	H Healing:	(42) 1 Focal	2 Moderate to Large	3 Massive
(43)	S Scarring:	(44) 1 Focal	2 Moderate to Large	3 Massive

Remarks: ___

OTHER HEART DISEASE: (45) ___ U Not Examined ___ P Present ___ A Absent
Description: ___

PERITONEUM

(46) ___ U Not Examined (47) ___ N Normal
(48) ___ P Pre-existing Lesions (49) ___ Ø Other (include contusion of wall)
Hemoperitoneum: (50-53) ___ cc Acites: (54-57) ___ cc
Remarks: ___

Figure 25 (7)

CASE NO. AUTOPSY NO.

INTERNAL (continued)

ESOPHAGUS

(58)____U Not Examined (59)____N Normal (60)____T Trauma or Laceration (61)____Ø Other Lesions

Remarks: ____

STOMACH

(62)____U Not Examined (63)____N Normal (64)____T Trauma or Rupture (65)____P Perforation

(66)____Ø Other Lesions: VOLUME OF CONTENTS: (67-70)____cc

DESCRIPTION OF CONTENTS: (71)____B Bloody (72)____C Coffee Ground (73)____S Bile Stained

(74)____M Mucous (75)____S Serous (76)____M Medication (77)____Ø Other

Remarks: (Specify other, if checked) ____

INTESTINES

SMALL: (including Mesentery) (10)____U Not Examined (11)____N Normal (12)____C Contusion

(13)____L Laceration (14)____P Perforation (15)____Ø Other (16)____P Pre-existing Lesion

Remarks: ____

LARGE: (17)____U Not examined (18)____N Normal (19)____C Contusion (20)____L Laceration

(21)____P Perforation (22)____Ø Other (23)____P Pre-existing Lesion

Remarks: ____

APPENDIX: (24)____U Present-Not Exam (25)____N Normal (26)____A Abnormal (27)____S Surg Absence

Remarks: ____

LIVER

(28)____U Not Examined (29)____N Normal (30)____T Trauma (31)____P Pre-existing Lesion

TRAUMA: (Classify as 1st, 2nd, 3rd or 4th degree.)

Contusion (32)____° Laceration (33)____° Perforation (34)____° Pulpefaction (35)____°

PRE-EXISTING LESIONS: (36)____F Fatty Infiltration (37)____Ø Other WEIGHT: (38-41)____gms

Remarks: ____

SPLEEN

(42)____U Present-Not Examined ____N Normal ____A Abnormal ____S Surgical Absence

TRAUMA: Laceration (43)____° Perforation (44)____° WEIGHT: (45-48)____gms

Remarks: ____

GALL BLADDER

(49)____U Present-Not Examined ____N Normal ____A Abnormal ____S Surgical Absence

Remarks: ____

PANCREAS

(50)____U Not Exam (51)____N Normal Contusion (52)____° Laceration (53)____° (54)____ϕ Other

WEIGHT: (55-58)____gms Remarks: ____

Figure 25 (8)

INTERNAL (continued)

ADRENALS

LEFT: (59) ___ U Not Exam (60) ___ N Normal (61) ___ H Hemorrhage (62) ___ L Laceration (63) ___ Ø Other
RIGHT: (64) ___ U Not Exam (65) ___ N Normal (66) ___ H Hemorrhage (67) ___ L Laceration (68) ___ Ø Other
WEIGHT: Left (69-70) ___ gms Right (71-72) ___ gms
Remakrs: ___

GENITO–URINARY SYSTEM

KIDNEY

LEFT: (10) ___ U Present-Not Exam ___ N Normal ___ S Surgical Absence ___ T Trauma
TRAUMATIC LESIONS: Contusion (11) ___ o Laceration (12) ___ o Perforation (13) ___ o
(14) ___ Ø OTHER LESIONS: ___ WEIGHT: (15-17) ___ gms
RIGHT: (18) ___ U Present-Not Exam ___ N Normal ___ S Surgical Absence ___ T Trauma
TRAUMATIC LESIONS: Contusion (19) ___ o Laceration (20) ___ o Perforation (21) ___ o
(22) ___ Ø OTHER LESIONS: ___ WEIGHT: (23-25) ___ gms
Remarks: ___

URINARY BLADDER

(26) ___ U Not Examined (27) ___ N Normal (28) ___ P Pre-existing Lesions
(29) ___ T Trauma and/or Perforation (30) ___ Ø Other Lesions CONTENTS: (31-34) ___ cc
Remarks: ___

(If Subject Is Female, Skip To Next Page.)

MALE ORGANS

PROSTATE

(35) ___ U Not Examined ___ N Normal ___ A Abnormal
Remarks: ___

PENIS

(36) ___ U Not Examined (37) ___ N Normal (38) ___ A Abnormal (39) ___ C Circumcision
Remarks: ___

TESTIS

LEFT: (40) ___ U Present-Not Exam (41) ___ N Normal (42) ___ S Surg Absence (43) ___ T Trauma (44) ___ Ø Other
RIGHT: (45) ___ U Present-Not Exam (46) ___ N Normal (47) ___ S Surg Absence (48) ___ T Trauma (49) ___ Ø Other
Remarks: ___

Figure 25 (9)

CASE NO. AUTOPSY NO.

INTERNAL (continued)

(If Subject Is Male, Skip To Next Page:)

FEMALE ORGANS

UTERUS

(35)____U Present-Not Examined (36)____N Normal (37)____S Surgical Absence (38)____P Pregnant
(39)____P Post Partum (40)____T Trauma: _____ (41)____Ø Other Lesions: _____
Remarks: _____

CERVIX

(42)____U Present-Not Examined (43)____N Normal (44)____S Surgical Absence (45)____P Pregnant
(46)____P Post Partum (47)____T Trauma: (48)____Ø Other Lesions:
Remarks: _____

OVARY

LEFT: (49)____U Present-Not Exam (50)____N Normal (51)____S Surg Absence (52)____T Trauma (53)____Ø Other
RIGHT: (54)____U Present-Not Exam (55)____N Normal (56)____S Surg Absence (57)____T Trauma (58)____Ø Other
Remarks: _____

FALLOPIAN TUBE

LEFT: (59)____U Present-Not Exam (60)____N Normal (61)____S Surg Absence (62)____T Trauma (63)____Ø Other
RIGHT: (64)____U Present-Not Exam (65)____N Normal (66)____S Surg Absence (67)____T Trauma (68)____Ø Other
Remarks: _____

VAGINA

(69)____U Not Examined (70)____N Normal (71)____A Abnormal (72)____L Laceration
Specimen taken? (73)____Y Yes ____N No
Remarks: (Include type of specimen and results) _____

Figure 25 (10)

CASE NO. AUTOPSY NO.

INTERNAL (continued)

SKELETAL

FRACTURES: (Check all applicable columns — include disc separations.)

TRAUMA:

Location	Not Exam / Normal	Minor / Severe	Single / Multiple	Simple / Compound / Comminuted
Cervical Spine:	(10) U (11) N	(12) 1 (13) 3	(14) S (15) M	(16) 1 (17) 2 (18) 3
Dorsal Spine:	(19) U (20) N	(21) 1 (22) 3	(23) S (24) M	(25) 1 (26) 2 (27) 3
Lumbar Spine:	(28) U (29) N	(30) 1 (31) 3	(32) S (33) M	(34) 1 (35) 2 (36) 3
Pelvis:	(37) U (38) N	(39) 1 (40) 3	(41) S (42) M	(43) 1 (44) 2 (45) 3
Upper Extremity:				
Left:	(46) U (47) N	(48) 1 (49) 3	(50) S (51) M	(52 1 (53) 2 (54) 3
Right:	(55) U (56) N	(57) 1 (58) 3	(59) S (60) M	(61) 1 (62) 2 (63) 3
Lower Extremity:				
Left:	(10) U (11) N	(12) 1 (13) 3	(14) S (15) M	(16) 1 (17) 2 (18) 3
Right:	(19) U (20) N	(21) 1 (22) 3	(23) S (24) M	(25) 1 (26) 2 (27) 3

PRE-EXISTING LESIONS: Osteoporosis (28) Y Yes N No

Other Disease (include tumors) (29) Y Yes N No

Remarks:

HEMOPOIETIC SYSTEM

LYMPH NODES: (30) U Not Examined N Normal A Abnormal

BONE MARROW: (31) U Not Examined N Normal A Abnormal

Remarks:

BIOCHEMICAL AND TOXICOLOGY

ETHANOL: (32) P Performed N Not Performed Method:

Urine Level: (33-36) . mgm% (37-39) . % Blood Level: (40-43) . mgm% (44-46) . %

Other: (47-50) Specify:

Remarks:

CARBON MONOXIDE: (51) P Performed N Not Performed % Saturation: (52-55)

Remarks:

ANALYSES FOR DRUGS OR MEDICATIONS: (56) P Performed N Not Performed

FINDINGS: (57) B Barbiturates (58) A Amphetamines (59) Ø Opiates (60) T Tranquilizers

(61) A Antihistamines (62) Ø Other:

Remarks: (Include type and level)

Figure 25 (11)

CASE NO. AUTOPSY NO.

INTERNAL (continued)

BIOMEDICAL AND TOXICOLOGY (continued)

OTHER TOXICOLOGY TESTS: (63) ___P___ Performed ___N___ Not Performed

Results Positive? (64) ___Y___ Yes ___N___ No

Remarks: Specify Findings) _____

BLOOD GROUP: (65) ___1___ (0+) ___2___ (0-) ___3___ (A+) ___4___ (A-) ___5___ (B+) ___6___ (B-) ___7___ (AB+) ___8___ (AB-)

Remarks and/or Special Blood Studies: _____

SPECIAL STUDIES

CLOTHING: (66) ___U___ Not Examined (67) ___E___ Examined Preserved? (68) ___Y___ Yes (69) ___N___ No

Remarks: (Specify Findings and How Clothing Disposed) _____

PHOTOGRAPHS (Available to Pathologist): (70) ___0___ None (71) ___1___ Scenes

(72) ___2___ Vehicle (73) ___3___ Victim (external) (74) ___4___ Organ Photographs

Remarks: _____

HISTOLOGICAL FINDINGS

List supplemental Positive Findings. (Use additional sheets of paper if necessary.)

FAT EMBOLISM: (75) ___U___ Not Examined Degree: (76) ___o___ Organ _____

(77) ___Ø___ Other: _____

Remarks: _____

(Space For Additional or Continued Remarks)

CASE NO. AUTOPSY NO.

FACTORS CONTRIBUTING TO ACCIDENT

HUMAN FACTORS

M

PHYSICAL: (Pre-existing Disease) (10) ___Y___ Yes ___N___ No ___X___ Unknown

Type: (11) ___1___ Cerebral (12) ___2___ Cardiovascular (13) ___3___ Other (Specify) ___

Remarks: ___

VISION: (14) ___N___ Normal ___A___ Abnormal ___X___ Unknown

Spectacles: (15) ___W___ Worn (16) ___N___ Not Worn Contacts: (17) ___W___ Worn (18) ___N___ Not Worn

Remarks: ___

HEARING: (19) ___N___ Normal ___A___ Abnormal ___X___ Unknown

Hearing Aid: (20) ___1___ Present and Functional ___2___ Present and Not Functional

(21) ___3___ Needed and Not Present Remarks: ___

CHEMICALS: (History of Ingestion) (22) ___N___ None ___P___ Positive ___X___ No Information

Type: (23) ___1___ Alcohol (24) ___2___ Carbon Monoxide (25) ___3___ Barbiturate (26) ___4___ Tranquilizer

(27) ___5___ Amphetamine (28) ___6___ Opiate (29) ___7___ Hallucinogen (30) ___8___ Antihistamine

(31) ___9___ Other: (Specify)

Remarks: ___

PSYCHOLOGICAL: (32) ___U___ Not Investigated ___I___ Investigated (Attach Summary)

Remarks: ___

SOCIO-ECONOMIC STATUS: (Family Annual Income)

(33) ___1___ (Less than $3,000) ___2___ ($3,001 to $6,000) ___3___ ($6,001 to $12,000)

___4___ (Greater than $12,000) ___5___ Unknown

Remarks: ___

PHYSICAL FACTORS

POSITION IN VEHICLE: (34) ___1___ Driver/Operator ___2___ Passenger ___3___ Pedestrian ___4___ Unknown

Seat Occupied: (35) ___1___ Front ___2___ Back ___3___ Tailgate ___4___ Seat on Bus

___5___ Other: (Specify) ___ ___6___ Unknown

Position of Tailgate Seat: Facing: (36) ___F___ Forward ___R___ Rearward ___C___ Center

Remarks: ___

TYPE OF VEHICLE: (37) ___1___ Car ___2___ Station Wagon ___3___ Truck ___4___ Bus

___5___ Motorcycle ___6___ Motor Scooter ___7___ Tractor-Trailer ___8___ Farm Vehicle

___9___ Military Vehicle (Other Than Above): ___

___Ø___ Other: (Specify) ___

Remarks: (Include No. of wheels, passengers, etc.) ___

MAKE OF VEHICLE: (i.e., Chevrolet, Ford, Dodge, Rambler) (38-45) ___

MODEL OF VEHICLE: (i.e., Impala, Mustang, Dart, Classic) (46-53) ___

YEAR OF VEHICLE: (54-55) 19___ SERIAL NUMBER (56-72) ___

Figure 25 (13)

CASE NO. AUTOPSY NO.

FACTORS CONTRIBUTING TO ACCIDENT

PHYSICAL FACTORS (continued)

BODY STYLE: (73) 1 2-Door with Center Post 2 4-Door with Center Post
3 2-Door with No Center Post 4 4-Door with No Center Post
5 2-Door with Convertible Top 6 4-Door with Convertible Top
7 Station Wagon 8 Other:

Remarks: (Include color(s) of Car)

TYPE OF ACCIDENT: (Refer to ICDA and enter proper code) (74-78) .

Remarks:

POSITION OF VICTIM AT ACCIDENT SCENE: (10) 1 Pedestrian 2 Remained in Vehicle
3 Ejected from Vehicle-Initial Impact 4 Ejected from Vehicle-Secondary Impact

Remarks:

VISIBILITY OF CLOTHING: (11) L Light M Medium D Dark

Remarks:

FIRE FOLLOWING IMPACT? (12) Y Yes N No

Remarks:

SEAT BELT WORN: (13) 1 Yes – Secured 2 Yes – Belt Failure
3 No – Belt Not Installed 4 No – Belt Installed But Not Worn 5 Unknown

SHOULDER HARNESS WORN: (14) 1 Yes – Secured 2 Yes – Harness Failure
3 No – Harness Not Installed 4 No – Harness Installed But Not Worn 5 Unknown

HEADREST: (15) 1 Defective 2 Not Defective 3 Not Installed 4 Unknown

HELMET WORN: (16) 1 Not Applicable 2 Yes 3 No 4 Unknown

Remarks (as necessary to explain, clarify or describe any entry above):

ENVIRONMENTAL FACTORS

WEATHER CONDITION: (17) 1 Clear (18) 2 Cloudy (19) 3 Windy

PRECIPITATION: (20) 0 None 1 Fog 2 Rain 3 Hail 4 Sleet 5 Snow

Remarks:

ROAD CONDITION: (21) 1 Dry (22) 2 Wet (23) 3 Ice (24) 4 Snow (25) 5 Oil
(26) 6 Slush (27) 7 Gravel (28) 8 Other:

Remarks:

GENERAL TIME OF DAY: (29) 1 Dawn 2 Day 3 Dusk 4 Night

DAY OF WEEK: (30) 1 Sun 2 Mon 3 Tue 4 Wed 5 Thu 6 Fri 7 Sat

HOLIDAY OR HOLIDAY WEEKEND: (31) Y Yes N No

Figure 25 (14)

CASE NO. AUTOPSY NO.

FACTORS CONTRIBUTING TO ACCIDENT

ENVIRONMENTAL FACTORS (continued)

ROAD SURFACE: (32) ___1___ Cement ___2___ Asphalt ___3___ Dirt ___4___ Other:

TYPE OF HIGHWAY: Limited Access? (33) ___Y___ Yes ___N___ No ___X___ Unknown

Total No. of Lanes: (34) ___ Opposite Lanes Separated by Barrier: (35) ___Y___ Yes ___N___ No

Remarks:

SECTION OF ROAD: (36) ___1___ Straight-a-way (37) ___2___ Curve Right Angle (38) ___3___ Curve Left Angle

(39) ___4___ Hill Incline (40) ___5___ Hill Decline (41) ___6___ Intersection

If at Intersection was it (42) ___C___ Controlled? or (43) ___U___ Uncontrolled?

Type of Control: (44) ___1___ 2-Way Stop ___2___ 4-Way Stop ___3___ Signal

___4___ Yield ___5___ Other:

Remarks: _____

GENERAL LOCATION: (45) ___B___ Business (High Population Density)

___S___ Suburban/Residential (Low Population Density) ___R___ Rural Area

___M___ Military Installation ___Ø___ Other: _____

Remarks: _____

MECHANICAL FACTORS – From Inspection of Vehicle

DOOR LOCKS: (46) ___1___ Defective ___2___ Not Defective and Locked

___3___ Not Defective and Not Locked ___4___ Undetermined ___5___ Not Applicable

WINDSHIELD:	(47) ___1___ Broken	___2___ Not Broken	___3___ Undetermined	
STEERING ASSEMBLY:	(48) ___1___ Defective	___2___ Not Defective	___3___ Undetermined	
BRAKES:	(49) ___1___ Defective	___2___ Not Defective	___3___ Undetermined	
HEAD LIGHTS:	(50) ___1___ Defective	___2___ Not Defective	___3___ Undetermined	
TAIL LIGHTS:	(51) ___1___ Defective	___2___ Not Defective	___3___ Undetermined	
BRAKE LIGHTS:	(52) ___1___ Defective	___2___ Not Defective	___3___ Undetermined	
WINDSHIELD WIPERS:	(53) ___1___ Defective	___2___ Not Defective	___3___ Undetermined	
DEFROSTER:	(54) ___1___ Defective	___2___ Not defective	___3___ Undetermined	
HORN:	(55) ___1___ Defective	___2___ Not Defective	___3___ Undetermined	
EXHAUST SYSTEM:	(56) ___1___ Defective	___2___ Not Defective	___3___ Undetermined	
FUEL TANK:	(57) ___1___ Ruptured	___2___ Not Ruptured	___3___ Undetermined	

TIRES: (58) ___1___ Blowout ___2___ Other Defect ___3___ Not Defective ___4___ Undetermined

INTERIOR SPACE LOST: (59) ___0___ None (60) ___1___ Front (61) ___2___ Rear (62) ___3___ Top (63) ___4___ Unknown

Remarks: (Specify defects indicated above.) _____

CASE NO. AUTOPSY NO.

FACTORS CONTRIBUTING TO ACCIDENT

FAMILIARITY WITH VICINITY OF ACCIDENT

(64) _____1 Local Resident _____2 Non-Resident _____3 Unknown

Remarks: _____

RELATED INFORMATION

PREVIOUS MOVING TRAFFIC VIOLATIONS: (65) _____Y Yes _____N No _____X Unknown

(List Violations Below.)

NUMBER OF PEOPLE INJURED IN THIS ACCIDENT: (66-67)_____

Remarks: _____

IDENTITY OF RELATED DEATHS: (Attach additional sheets of paper if necessary.)

	Case No.	Autopsy No.	(Reserved)
1.	(10-19) _____	(20-29)_____	(30-37)_____
2.	(10-19) _____	(20-29)_____	(30-37)_____
3.	(10-19) _____	(20-29)_____	(30-37)_____
4.	(10-19) _____	(20-29)_____	(30-37)_____
5.	(10-19) _____	(20-29)_____	(30-37)_____

Remarks: _____

LIST TRAFFIC CONVICTIONS: _____

SUBMITTING ORGANIZATION:

CASE NO. _____ NAME _____

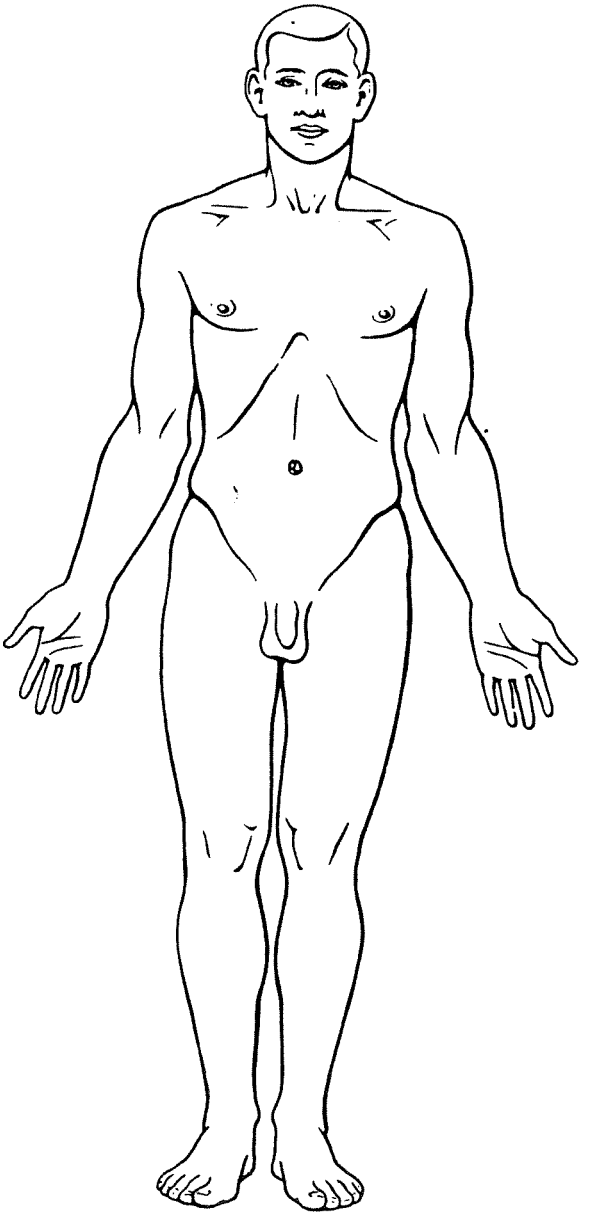

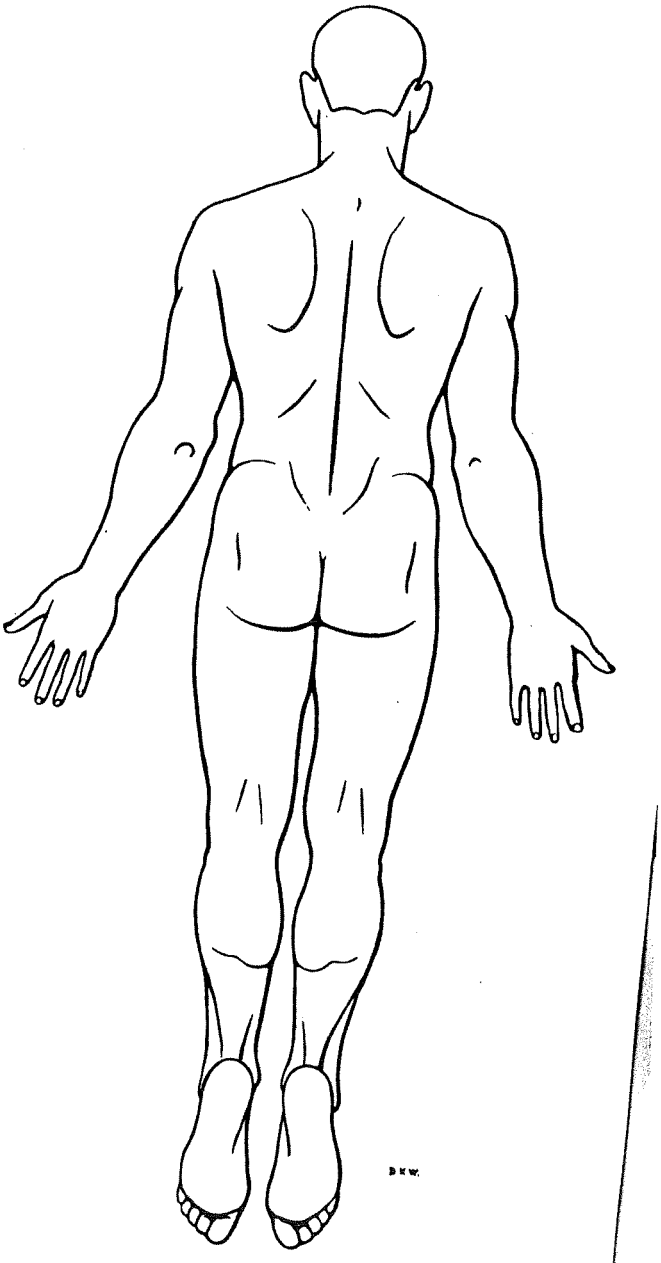

DIAGRAM A

Figure 25 (17)

CASE NO._____ NAME _____

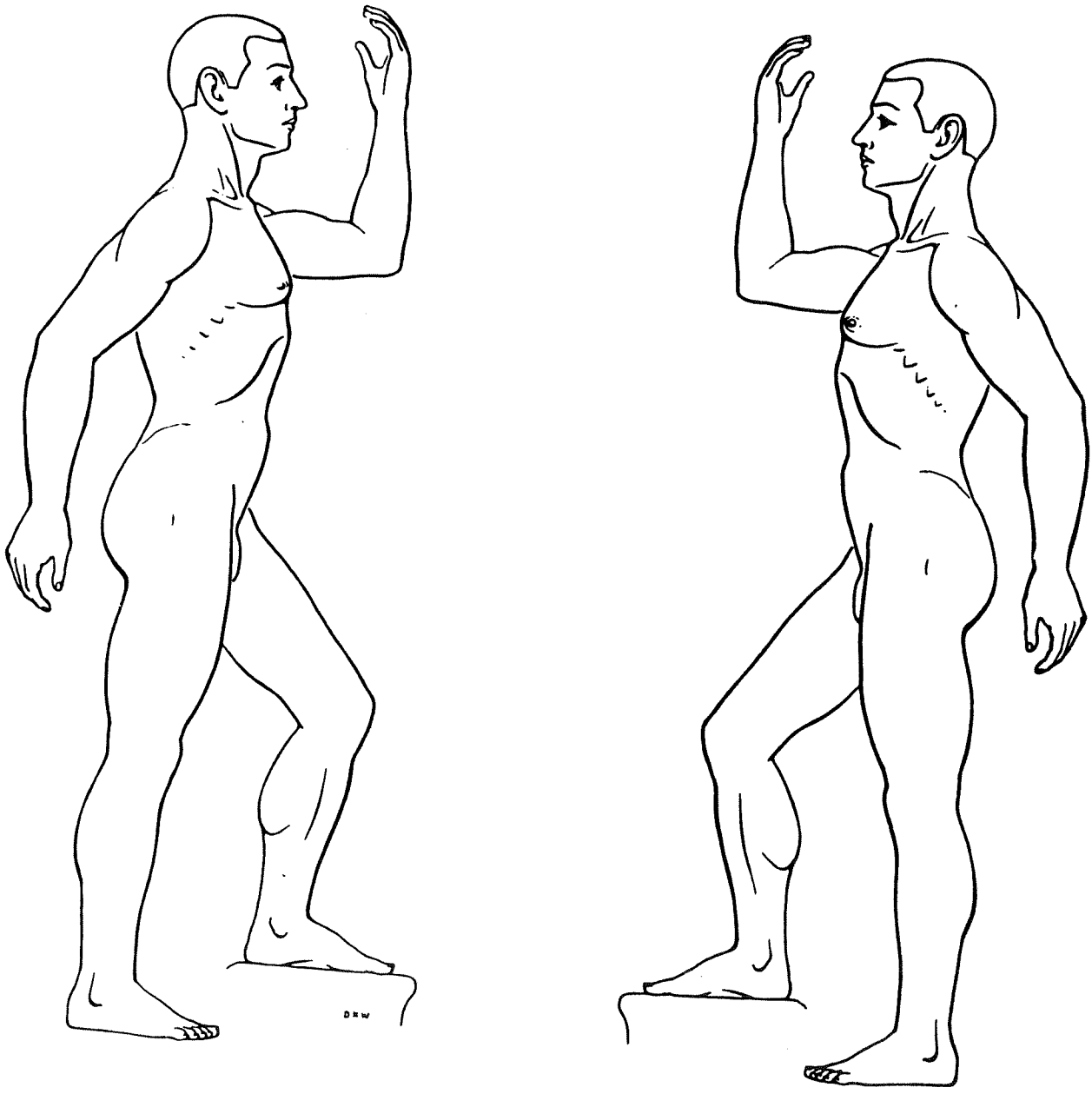

DIAGRAM B

Figure 25 (18)

CASE NO._____ NAME _____

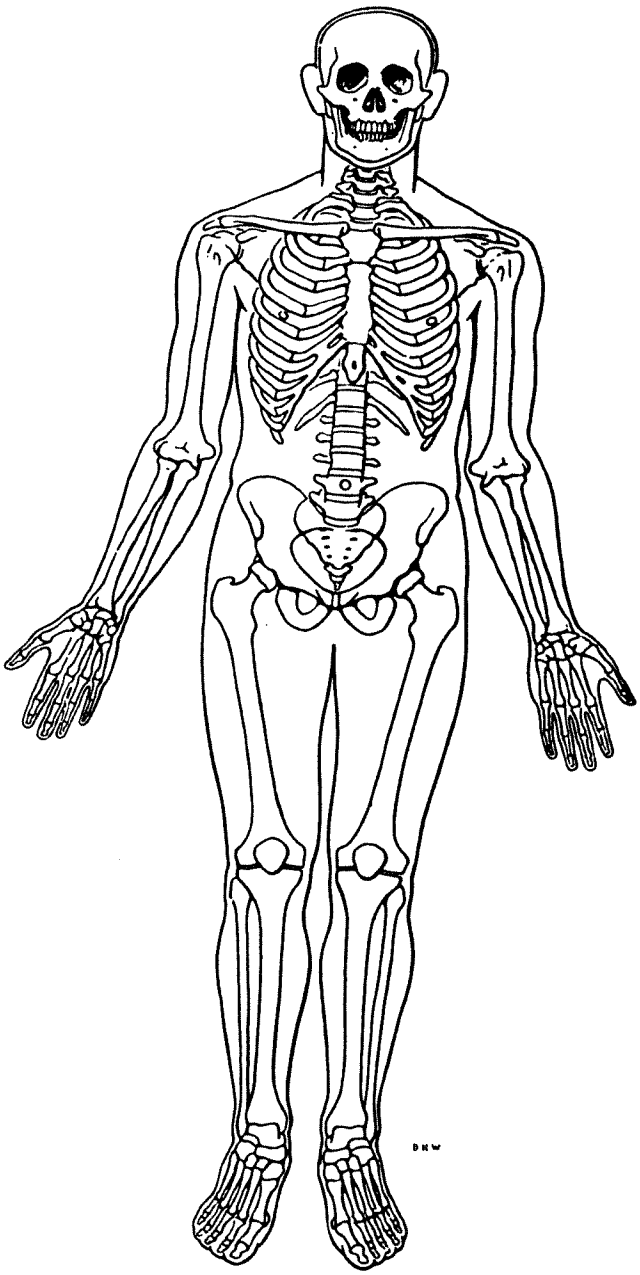

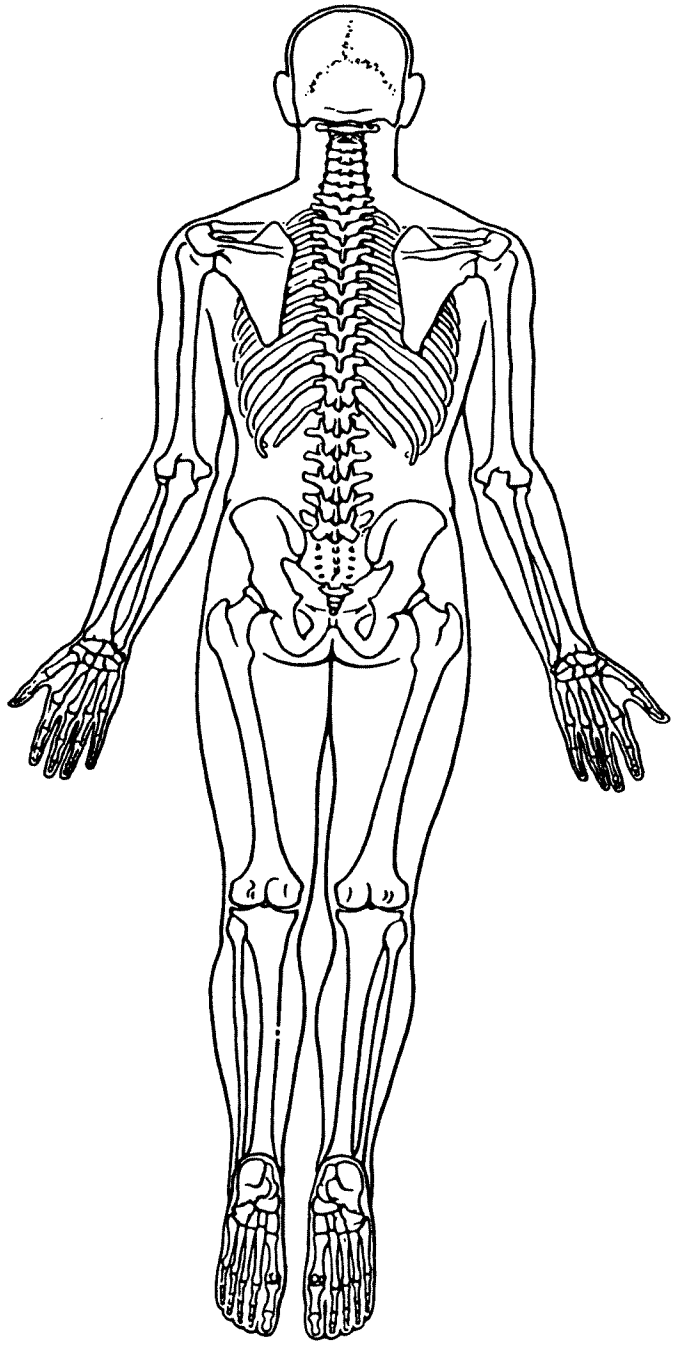

DIAGRAM C

Figure 25 (19)

CASE NO. _____ NAME _____

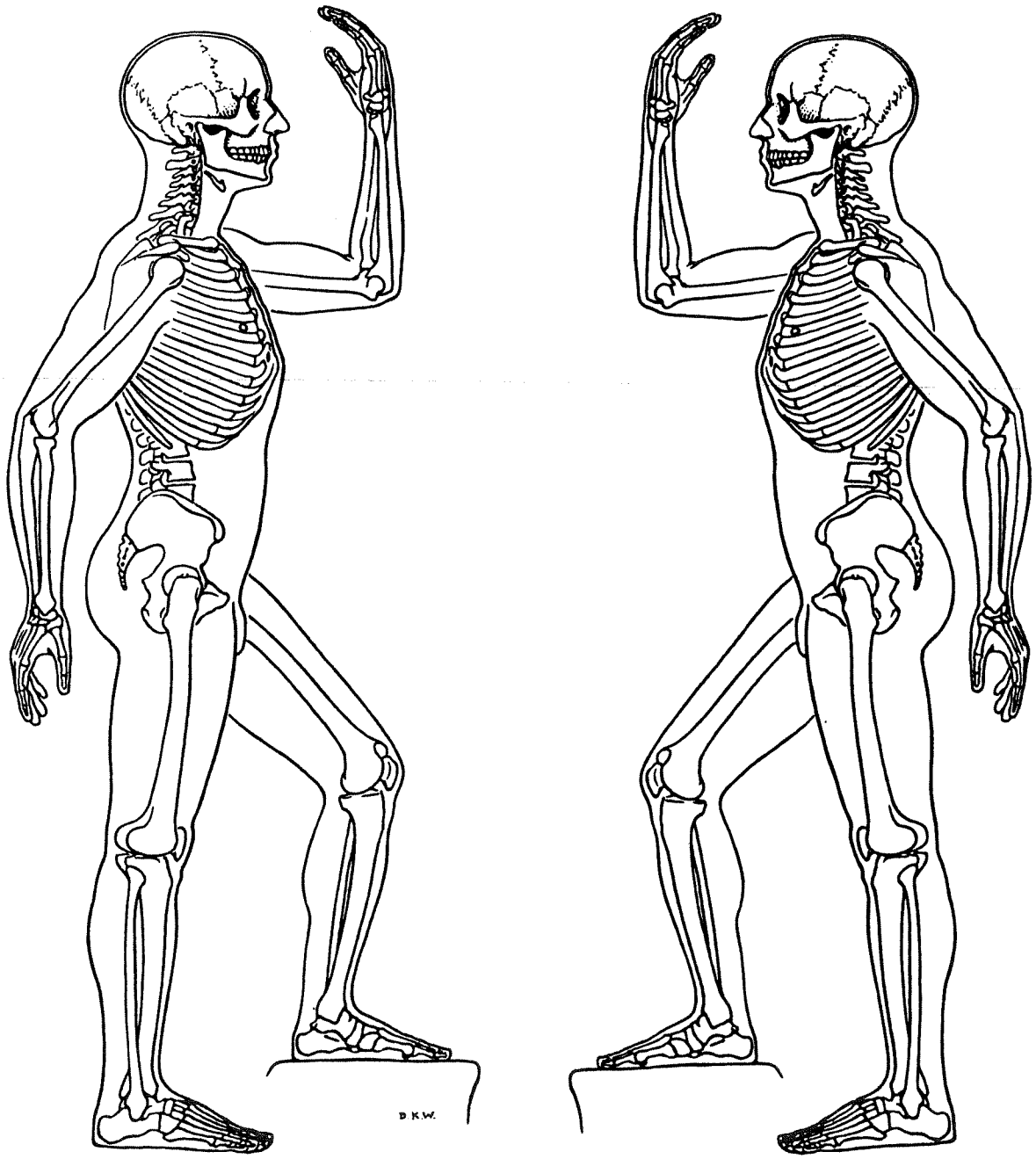

DIAGRAM D

Figure 25 (20)

CASE NO. _____ NAME _____

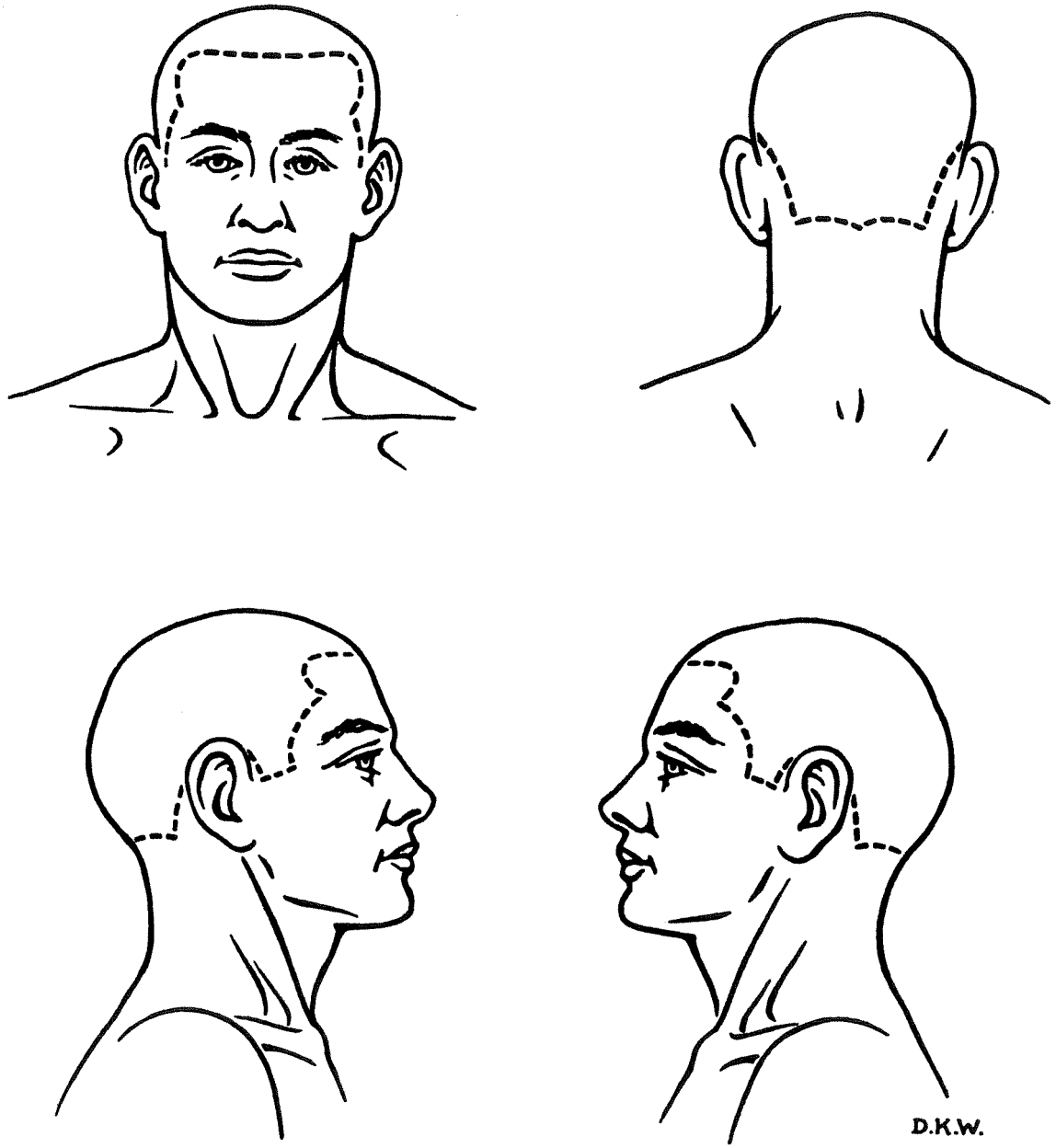

DIAGRAM E

Figure 25 (21)

CASE NO. _____ NAME _____

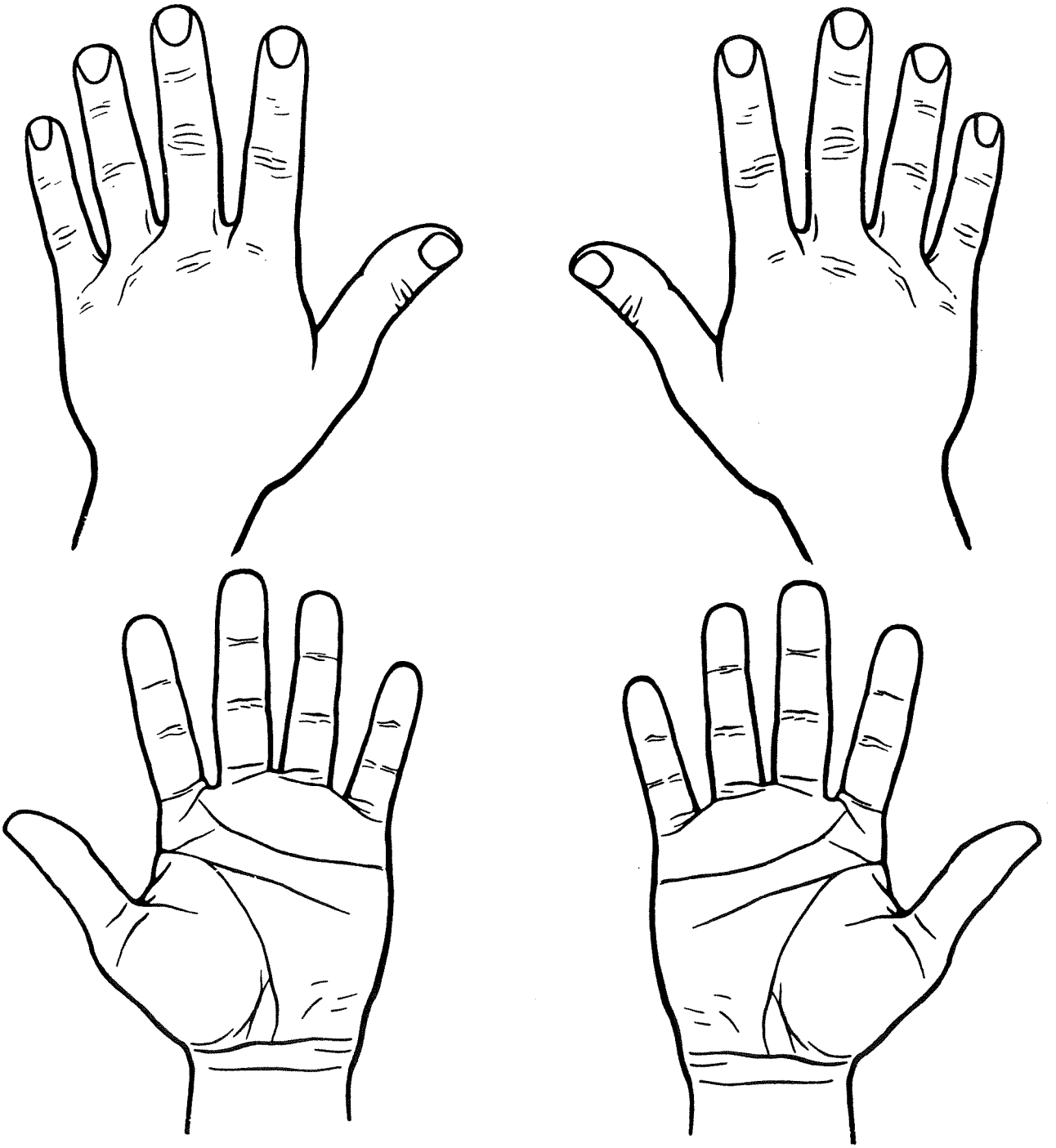

DIAGRAM F

Figure 25 (22)

CASE NO. _____ NAME _____

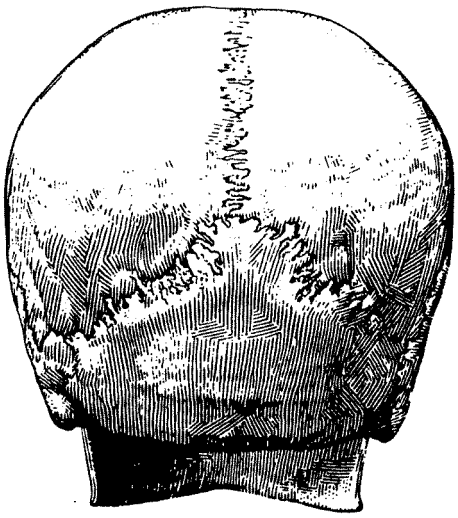

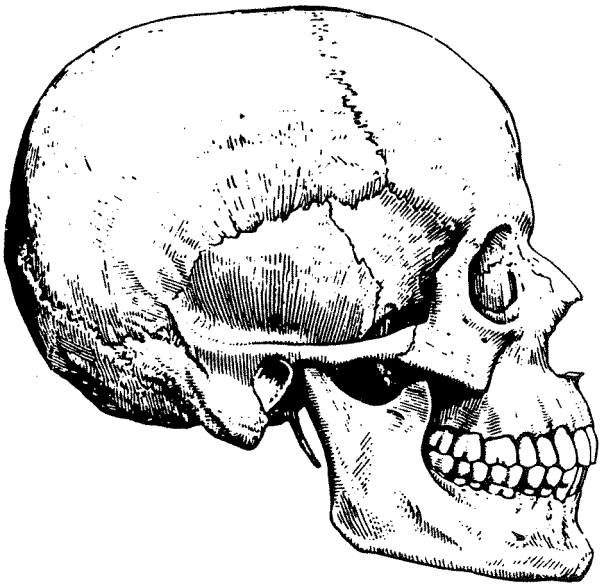

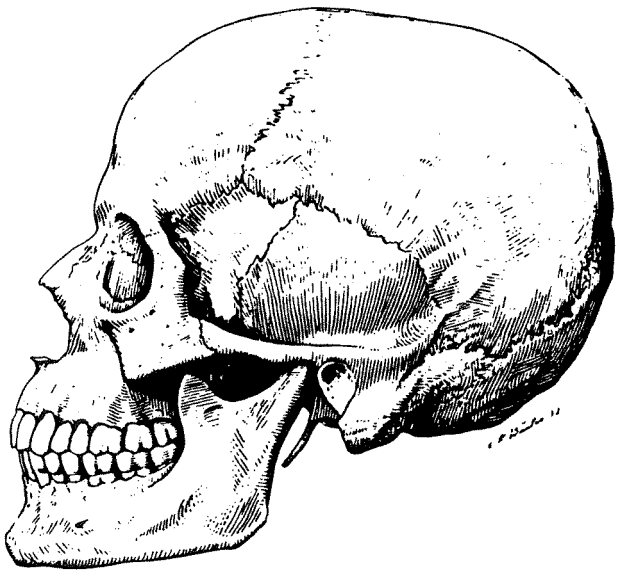

DIAGRAM G

Figure 25 (23)

CASE NO._____ NAME _____

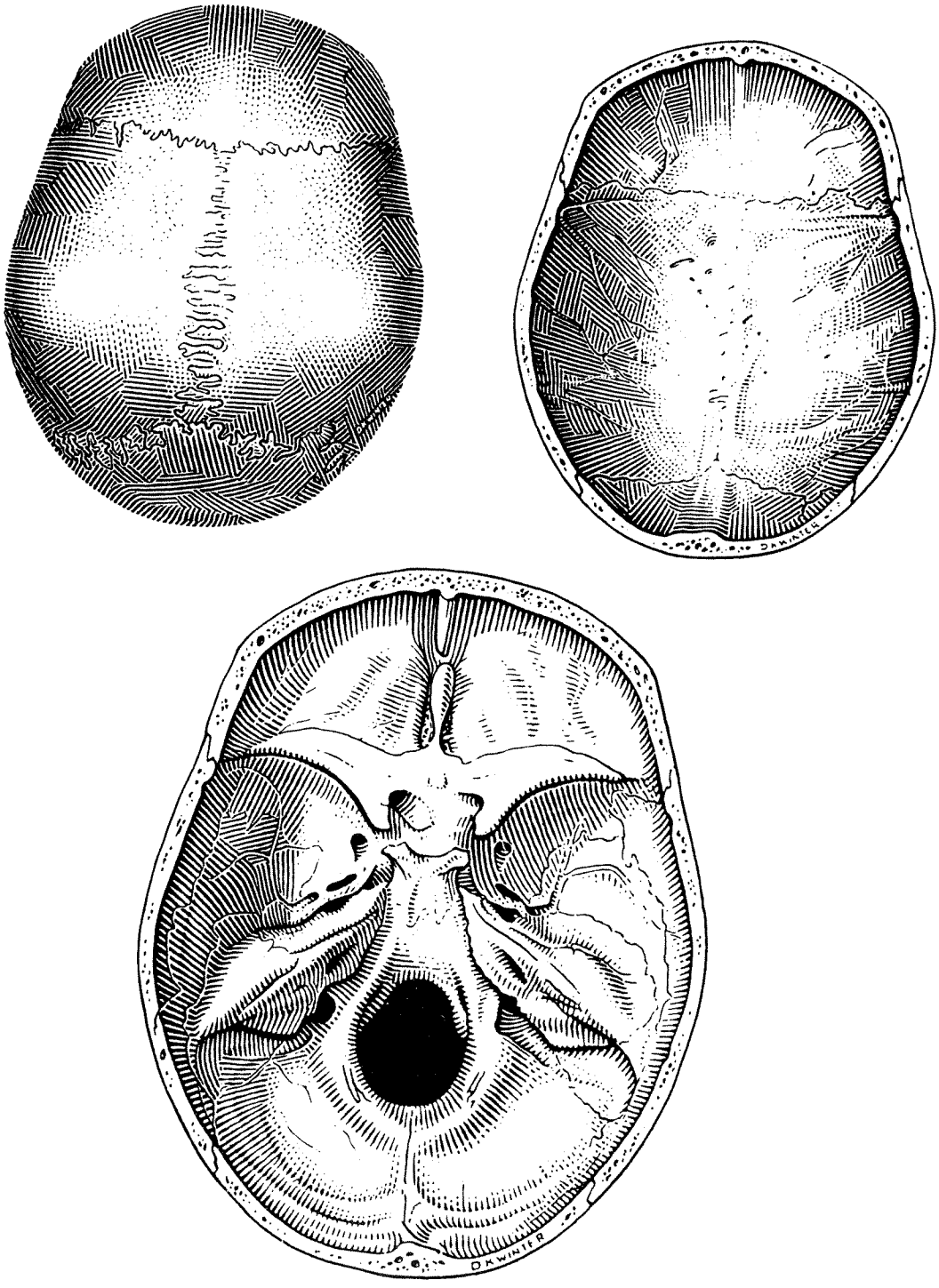

DIAGRAM H

Figure 25 (24)

CASE NO. _____ NAME _____

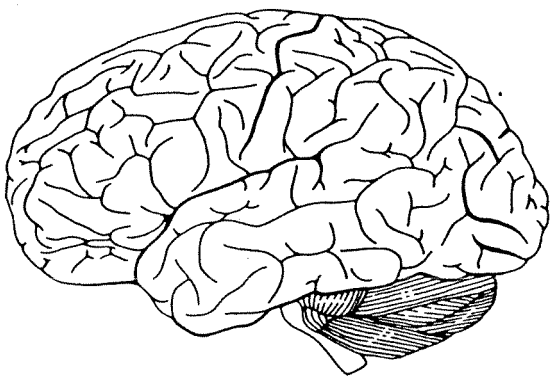

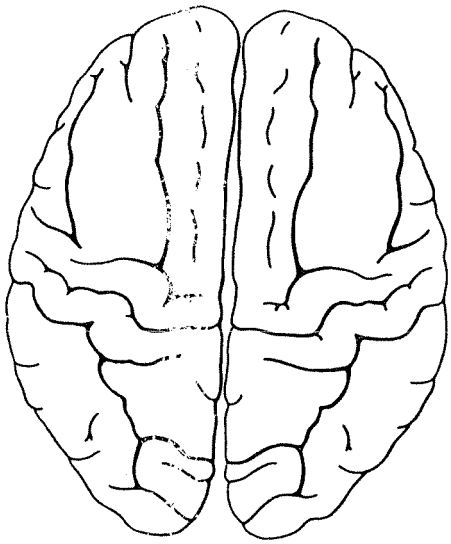

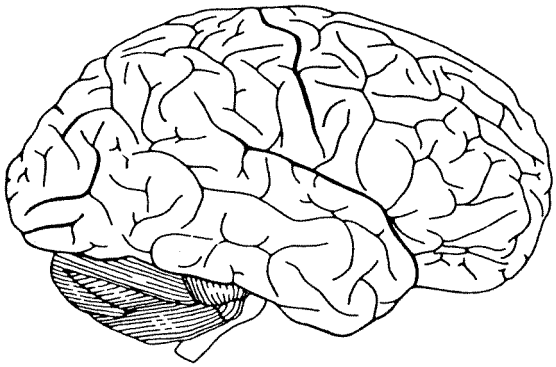

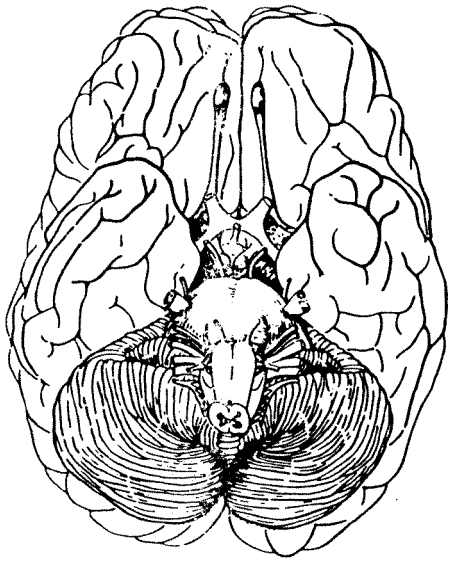

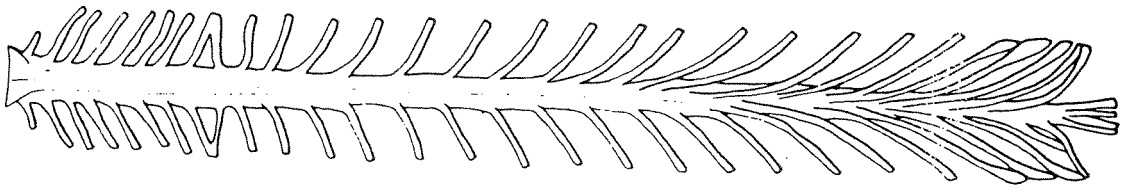

DIAGRAM I

Figure 25 (25)

CASE NO._____ NAME _____

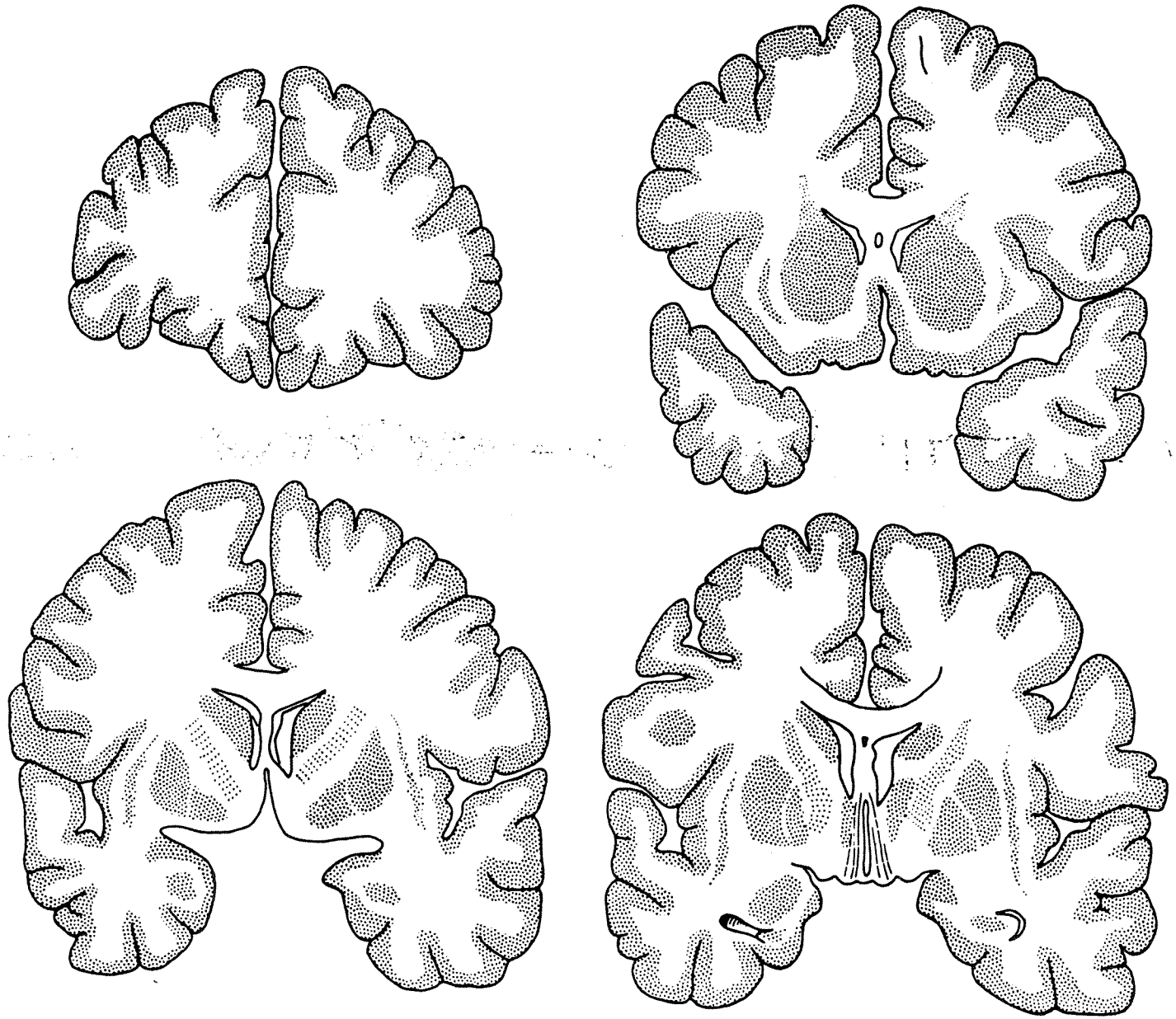

DIAGRAM J

Figure 25 (26)

CASE NO._____ NAME_____

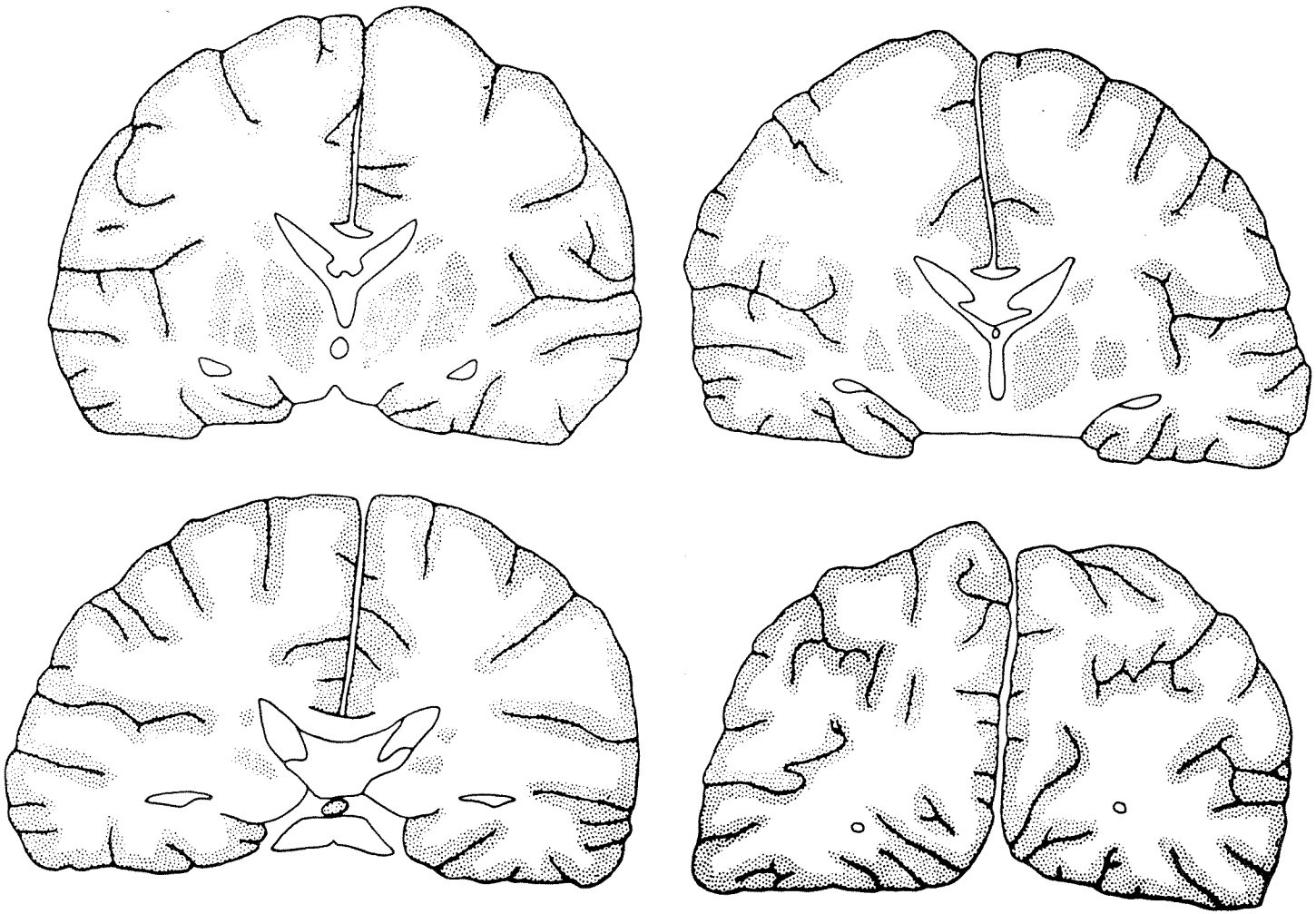

DIAGRAM K

Figure 25 (27)

CASE NO. _____ NAME _____

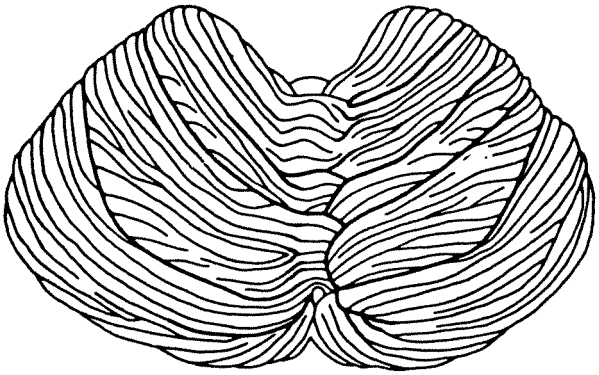

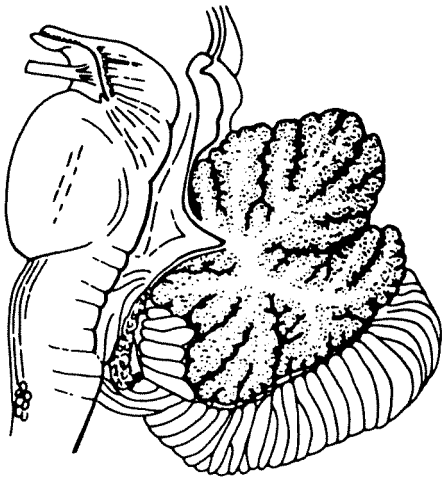

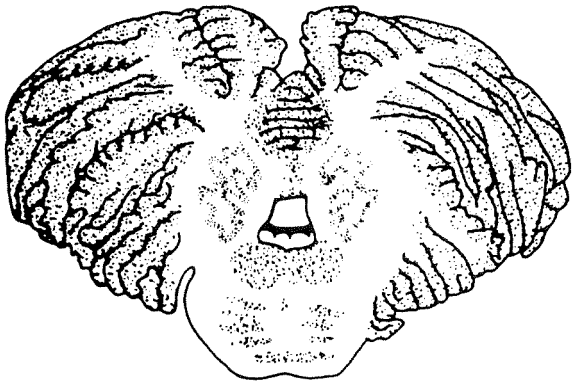

C5

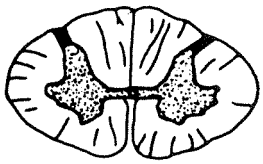

T2

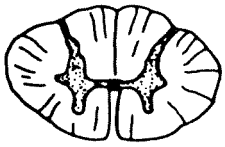

T8

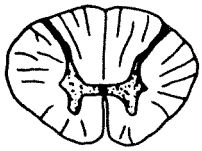

L3

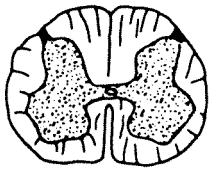

S1

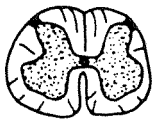

S3

DIAGRAM L

Figure 25 (28)

CASE NO. _____ NAME _____

RESPIRATORY SYSTEM

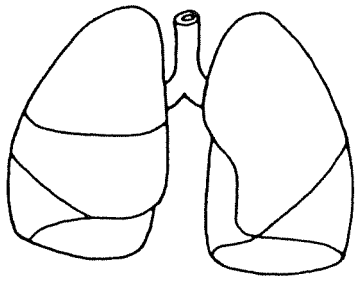

R L

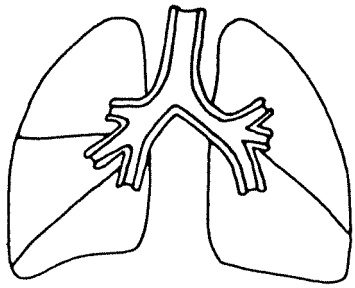

CARDIOVASCULAR SYSTEM

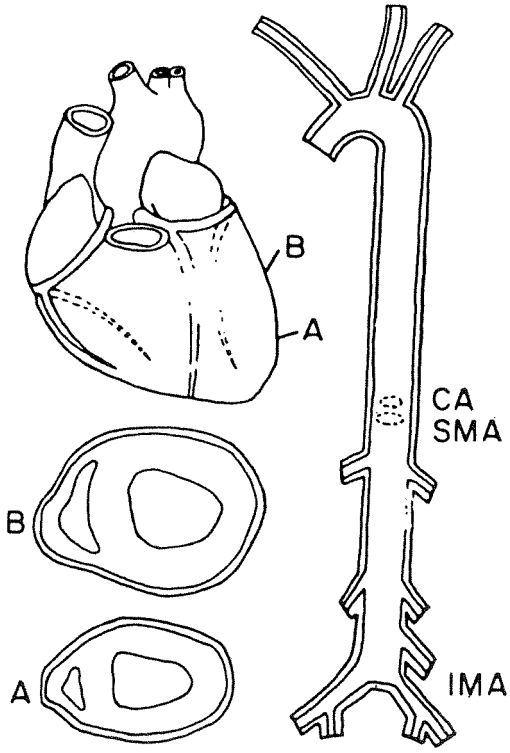

DIAGRAM M

Figure 25 (29)

CASE NO._____ NAME_____

ALIMENTARY SYSTEM

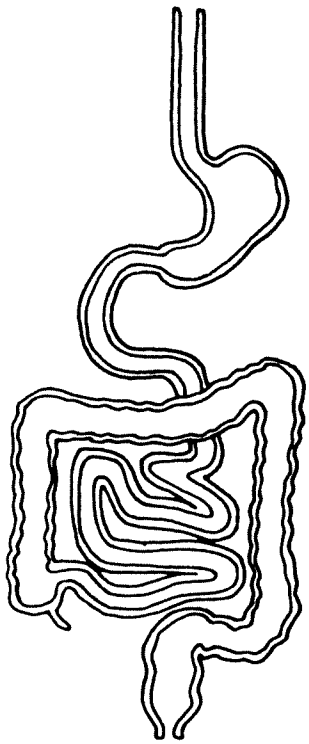

BILIARY SYSTEM

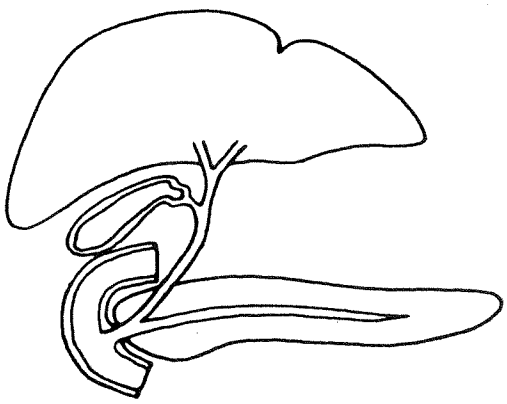

DIAGRAM N

Figure 25 (30)

CASE NO. _____ NAME _____

HEMATOPOIETIC SYSTEM

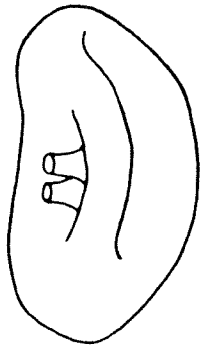

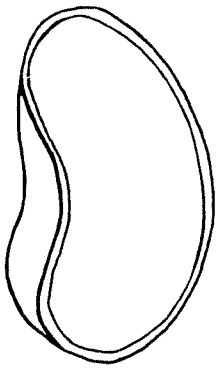

URINARY SYSTEM

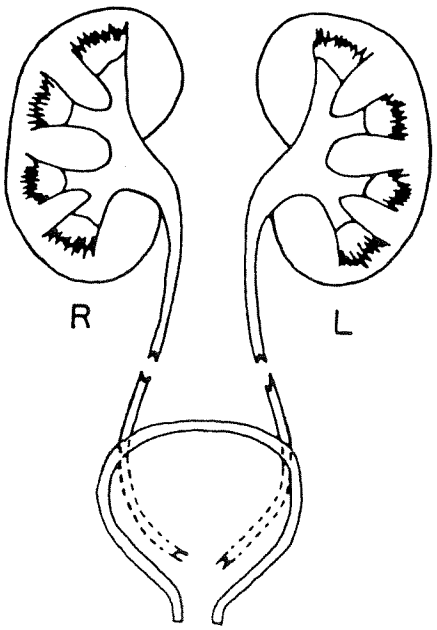

DIAGRAM O

Figure 25 (31)

CASE NO._____ NAME_____

MALE REPRODUCTIVE SYSTEM

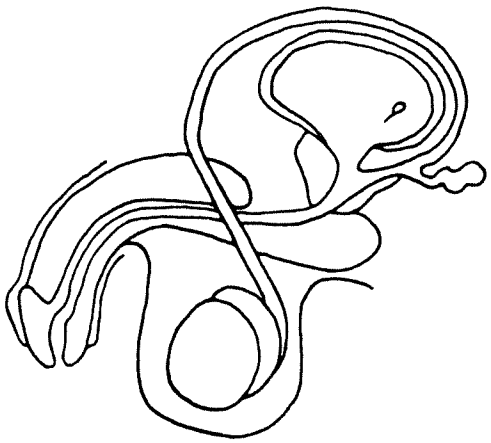

FEMALE REPRODUCTIVE SYSTEM

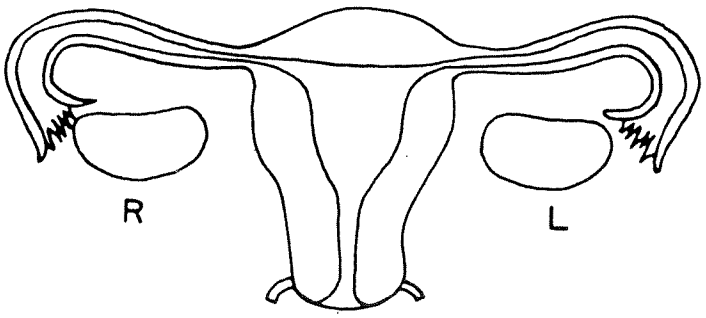

DIAGRAM P

Figure 25 (32)

CASE NO. _____ NAME _____

ENDOCRINE SYSTEM

Thyroid

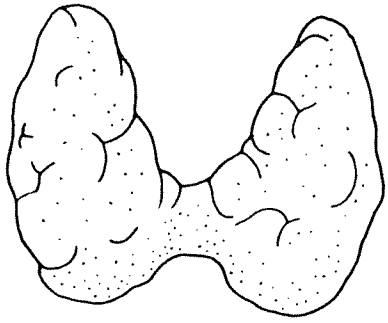

Adrenals

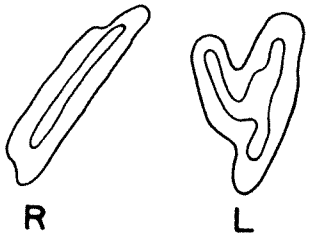

Pituitary

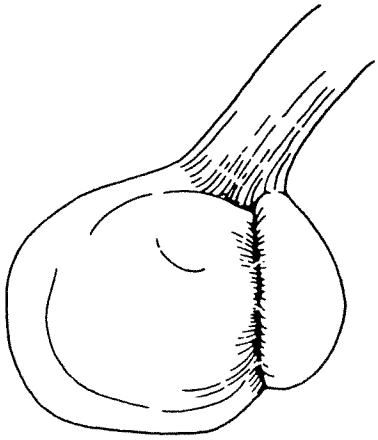

DIAGRAM Q

Figure 25 (33)

☆ U.S. GOVERNMENT PRINTING OFFICE : 1985 O - 461-421 (20697)